

Brain structural changes in schizoaffective disorder compared to schizophrenia and bipolar disorder

Amann BL, Canales-Rodríguez EJ, Madre M, Radua J, Monte G, Alonso-Lana S, Landin-Romero R, Moreno-Alcázar A, Bonnín CM, Sarró S, Ortiz-Gil J, Gomar JJ, Moro N, Fernandez-Corcuera P, Goikolea JM, Blanch J, Salvador R, Vieta E, McKenna PJ, Pomarol-Clotet E. Brain structural changes in schizoaffective disorder compared to schizophrenia and bipolar disorder.

Objective: Brain structural changes in schizoaffective disorder, and how far they resemble those seen in schizophrenia and bipolar disorder, have only been studied to a limited extent.

Method: Forty-five patients meeting DSM-IV and RDC criteria for schizoaffective disorder, groups of patients with 45 matched schizophrenia and bipolar disorder, and 45 matched healthy controls were examined using voxel-based morphometry (VBM).

Results: Analyses comparing each patient group with the healthy control subjects found that the patients with schizoaffective disorder and the patients with schizophrenia showed widespread and overlapping areas of significant volume reduction, but the patients with bipolar disorder did not. A subsequent analysis compared the combined group of patients with the controls followed by extraction of clusters. In regions where the patients differed significantly from the controls, no significant differences in mean volume between patients with schizoaffective disorder and patients with schizophrenia in any of five regions of volume reduction were found, but mean volumes in the patients with bipolar disorder were significantly smaller in three of five.

Conclusion: The findings provide evidence that, in terms of structural gray matter brain abnormality, schizoaffective disorder resembles schizophrenia more than bipolar disorder.

B. L. Amann^{1,2},
E. J. Canales-Rodríguez^{1,2},
M. Madre^{1,3}, J. Radua^{1,4},
G. Monte¹, S. Alonso-Lana¹,
R. Landin-Romero^{1,2},
A. Moreno-Alcázar¹,
C. M. Bonnín⁵, S. Sarró^{1,2},
J. Ortiz-Gil^{1,6}, J. J. Gomar¹,
N. Moro^{1,5}, P. Fernandez-
Corcuera⁵, J. M. Goikolea⁷,
J. Blanch⁸, R. Salvador^{1,2},
E. Vieta^{2,7}, P. J. McKenna^{1,2},
E. Pomarol-Clotet^{1,2}

¹FIDMAG Research Foundation Germanes Hospitalàries, Barcelona, ²CIBERSAM, Madrid, ³Departament de Psiquiatria i Medicina Legal, Doctorat de Psiquiatria i Psicologia Clínica, Universitat Autònoma de Barcelona, Barcelona, Spain, ⁴Department of Psychosis Studies, Institute of Psychiatry, King's College London, London, UK, ⁵Hospital Benito Menni CASM, Sant Boi, ⁶Hospital General de Granollers, Granollers, ⁷Bipolar Disorders Unit, Hospital Clínic, University of Barcelona, IDIBAPS, Barcelona, and ⁸Department of Radiology, Hospital San Juan de Déu, Barcelona, Spain

This is an open access article under the terms of the Creative Commons Attribution-NonCommercial License, which permits use, distribution and reproduction in any medium, provided the original work is properly cited and is not used for commercial purposes.

Key words: neuroimaging; schizoaffective disorder; schizopreniabipolar disorder; voxel-based morphometry

Benedikt L. Amann, FIDMAG Research Foundation, Dr. Antoni Pujadas 38, 08830 Sant Boi de Llobregat, Spain.
E-mail: benedikt.amann@gmail.com

Accepted for publication April 20, 2015

Significant outcomes

- Patients with schizoaffective disorder showed widespread areas of gray matter reduction similar to those observed in schizophrenia
- Gray matter reductions were more extensive in patients with both schizophrenia and schizoaffective disorder than in patients with bipolar disorder, suggesting that schizoaffective disorder resembles schizophrenia more than bipolar disorder
- Neuroimaging may provide a useful source of evidence in the ongoing debate about the nosological position of schizoaffective disorder

Limitations

- Gray matter differences were found in the comparisons between the patients and the controls; differences among the patient groups themselves were not seen
- All patients were medicated, which might have influenced the results
- A sample of schizoaffective disorder, bipolar type, was studied, and the results should not be extrapolated to schizoaffective disorder, unipolar type.

Introduction

Eighty years after the term was introduced by Kasanin (1), the nosology of schizoaffective disorder remains elusive and controversial (2). At various times, it has been argued that it should be considered an independent diagnostic entity (3), a variant of schizophrenia (4), a variant of affective disorder (5), the midpoint on a continuum between the two (6), or even a disorder which does not really exist (7). Clinical studies have performed little to clarify the status of the disorder, finding that it does not clearly separate from schizophrenia or bipolar disorder, either cross-sectionally (8, 9), or in terms of its course and outcome (for a review, see (10)). Similarly, family history studies have found high rates of affective disorders in the first-degree relatives of patients with schizoaffective disorder, but also elevated rates of schizophrenia (11–14).

Structural brain imaging could represent a further source of evidence in this debate. Thus, while schizophrenia is characterized by a reduction in whole volume of around 2%, coupled with larger reductions in regions such as the frontal lobe and the hippocampus (15), bipolar disorder appears to be associated with only at most minor whole brain and regional volume changes (16, 17). Few studies have examined schizoaffective disorder using conventional CT or MRI measures (18–21), and these have mostly been underpowered and have not demonstrated clear differences from either schizophrenia or bipolar disorder.

Studies using newer structural imaging techniques like voxel-based morphometry (VBM) might be more informative in this respect, given that they map volume change across the whole brain, without the necessity of preselecting regions of interest. Schizophrenia and bipolar disorder have been found to show different patterns of gray matter change using this technique: Ellison-Wright and Bullmore (22) meta-analyzed 42 VBM studies of schizophrenia and 14 of bipolar disorder and found that the distribution of gray matter volume reductions was wide in schizophrenia, affecting the frontal, temporal, cingulate and insular cortex, and the thalamus. In contrast, reductions in bipolar disorder were restricted to the anterior cingulate

cortex and bilateral insula. Bora et al. (23) had similar findings in a subsequent meta-analysis, although they noted that the differences became less marked when a predominance of male patients in schizophrenia studies but not in patients with bipolar disorder was controlled for.

To date, there have been only two VBM studies of schizoaffective disorder, both from the same group. In the first of these, Ivleva et al. (24) examined 19 patients with schizophrenia, 16 with schizoaffective disorder, and 17 with bipolar psychotic disorder, as well as 10 healthy controls. They found decreased gray matter volume in the patients with schizophrenia, and there were similar, albeit less extensive, changes in the patients with schizoaffective disorder; however, the patients with bipolar disorder did not differ from the controls. In a larger study which combined MRI data from four different centers, Ivleva et al. (25) found that 146 patients with schizophrenia and 90 patients with schizoaffective disorder both showed gray matter volume reductions in numerous and overlapping areas compared to 200 healthy controls. In contrast, 115 patients with psychotic bipolar disorder showed volume reductions that were limited to the frontotemporal cortex. In both studies, it should be noted, no differences were detected in pairwise comparisons among the three patient groups.

Aims of the study

The aim of this study was to examine, by means of voxel-based morphometry, patterns of brain structural abnormality in well-matched samples of patients with schizoaffective disorder, schizophrenia, and bipolar disorder. Healthy controls were also employed.

Material and methods

Subjects

Forty-five patients with schizoaffective disorder, bipolar type, were recruited from the inpatient units and outpatient departments of three psychiatric hospitals in the Barcelona area: Hospital

Benito Menni in Sant Boi, Hospital Clínic of Barcelona, and Hospital General of Granollers. All patients were diagnosed using DSM-IV criteria, based on a detailed clinical interview and review of case notes. In view of a number of weaknesses identified with the DSM-IV diagnosis of schizoaffective disorder (26), we also required the patients to meet the more detailed and somewhat stricter Research Diagnostic Criteria (RDC) (27). Diagnoses were made based on a detailed clinical interview and review of case notes carried out by a single member of the study team (BLA). The schizoaffective sample included 15 patients who were schizomanic at the time of evaluation, 15 who were schizodepressed, and 15 who only showed minor affective and psychotic symptoms.

Groups of patients with schizophrenia ($n = 45$) and bipolar disorder ($n = 45$), diagnosed according to DSM-IV, were recruited from the same three hospitals. Once again diagnoses were made based on a detailed clinical interview and review of case notes. The schizophrenic sample included 20 patients with acute psychotic symptoms and 25 patients stabilized at the time of evaluation and MRI scanning session. All the patients with bipolar disorder had bipolar I disorder, and 32 had a history of psychotic symptoms (71%). The sample included 15 patients who were manic, 15 who were in a depressive phase, and 15 who were euthymic at the time of evaluation. Normally, patients were admitted to the hospitals in an acute state, in a manic or depressed episode for patients with bipolar disorder or schizodepressed or schizomanic phase for schizoaffective disorder fulfilling corresponding diagnostic criteria. Some patients were also scanned while being in euthymia or clinical remission, recruited from the corresponding outpatient clinics.

All patients were right handed. Exclusion criteria for all three groups were age younger than 18 or older than 65 years, history of neurological disease or brain trauma, and alcohol/substance abuse in the 12 months prior to participation. Patients were also required to have a current IQ in the normal range (>70).

Right-handed healthy subjects ($n = 45$) were recruited via poster and web-based advertisement in the hospital and local community, plus word-of-mouth requests from staff in the research unit. They met the same exclusion criteria as the patients, and they were interviewed and excluded if they reported a history of mental illness and/or treatment with psychotropic medication other than non-regular use of benzodiazepines or similar drugs for insomnia. They were also questioned about family history of mental illness and excluded

if a first-degree relative had experienced symptoms consistent with major psychiatric disorder and/or had received any form of in- or outpatient psychiatric care.

The three patient groups and the healthy controls were selected to be matched with the schizoaffective sample on demographic variables, and on premorbid IQ, as estimated using the Word Accentuation Test (Test de Acentuación de Palabras, TAP) (28, 29). This test is conceptually similar to the UK National Adult Reading Test (30) and the American Wide-Range Achievement Test (31) and requires pronunciation of Spanish words whose accents have been removed. Current IQ was measured using four subtests of the Wechsler Adult Intelligence Scale III (WAIS-III) (vocabulary, similarities, block design, and matrix reasoning).

The study was carried out in accordance with the latest version of the Declaration of Helsinki and was approved by the research ethics committee (Comité Ético de Investigación Clínica de las Hermanas Hospitalarias, Barcelona). Written informed consent was obtained for all subjects.

Structural imaging

All subjects underwent structural MRI scanning in a single session, using the same 1.5 Tesla GE Signa scanner (General Electric Medical Systems, Milwaukee, WI), located at the Sant Joan de Déu Hospital in Barcelona, Spain.

Structural T1-weighted MRI data were acquired using 180 contiguous axial slices with thickness of 1 mm. The images were collected in a 256×224 acquisition matrix and were zero-filled in the k-space by the scanner to yield an image of 512×512 pixels with reconstruction diameter of 240 mm, resulting in an effective in-plane voxel size of $0.47 \times 0.47 \text{ mm}^2$. The echo (TE), repetition (TR) and inversion (TI) times were equal to (TE/TR/TI) = 3.93 ms/2000 ms/710 ms respectively. The flip angle was 15 degrees, and the total acquisition time was approximately 5 min. All images were visually inspected to detect any artifact.

Structural data were analyzed with FSL-VBM, an optimized voxel-based morphometry style analysis (32) carried out with FSL tools (33), which allows to detect potential differences in the local gray matter volume between different groups of subjects. In a first step, structural images were brain-extracted using BET (34). Next, tissue-type segmentation was carried out and the resulting gray matter partial volume images were aligned to the MNI152 standard space using the FSL tools FLIRT and FNIRT. The resulting images were averaged to create a study-specific template, to

which the native gray matter images were nonlinearly re-registered. These images were modulated (to correct for local expansion or contraction) by multiplying by the Jacobian of the warp field, and they were later smoothed with an isotropic Gaussian kernel with a sigma of 4 mm (approximately corresponding to FWHM of 9.4 mm). No images were discarded due to artifacts or technical reasons.

Statistical analyses

Demographic and clinical data. Differences in demographic and clinical characteristics among the groups were examined using chi-square tests for categorical variables and one-way ANOVA tests for continuous variables, with pairwise chi-square/Tukey post hoc comparisons in case of statistical significance.

Inter-group VBM comparisons. Voxel-based morphometry comparisons were carried out using a voxel-wise general linear model (GLM) and permutation-based nonparametric testing as implemented in FSL *randomize* programme, using the threshold-free cluster enhancement (TFCE) method (35) and 10 000 permutations. In the first step, each patient group was individually compared with the healthy control subjects. The three patient groups were also compared with each other. Anatomical locations of significant clusters were determined by reference to the MNI structural atlas integrated into FSLView (part of FSL), the AAL atlas within MRICRON software (<http://www.mccauslandcenter.sc.edu/mricron/mricron/index.html>), and the XJVIEW toolbox for SPM (<http://www.alivelearn.net/xjview8/>).

VBM of the combined patient group and controls with subsequent analysis of the resulting significant clusters. Given that schizophrenia, bipolar disorder and presumptively schizoaffective disorder are all characterized by gray matter volume reductions, structural imaging differences between these patient groups are likely to be more difficult to detect than those between a patient group and controls (e.g., 36). Therefore, a further, region-of-interest (ROI)-based analysis was conducted to detect potential differences between patients groups. For this, the healthy control group was first compared with the combined patient group. This analysis allowed the identification of relevant affected regions related to the illnesses. Then, in a second step, the volume on these detected regions was compared between the three patient groups.

Threshold. In all the whole-brain analyses, a threshold of $P = 0.01$, family-wise error (FWE) corrected for multiple comparisons across space, was used. We applied this relatively conservative threshold to minimize false-positive findings arising from the fact that six different inter-group comparisons were carried out. For completeness, we also report results applying a corrected threshold of $P = 0.05$. For the ROI analysis, correction for multiple comparisons was carried out using the Bonferroni method.

Results

Demographic and clinical data

The findings for the three patient groups and the controls are shown in Table 1. The groups were preselected to be matched for age, sex, and estimated premorbid IQ (TAP score); they were also not significantly different in duration of illness. As expected, the patients with schizophrenia showed a lower current IQ than the healthy controls. This also applied to the patients with schizoaffective disorder and the patients with bipolar disorder.

The number of patients receiving atypical antipsychotics was higher than the number of patients receiving typical antipsychotics in all three groups (patients with bipolar disorder: 68% vs. 24%; patients with schizophrenia: 92% vs. 35%; patients with schizoaffective disorder: 87% vs. 33%). There were statistically significant differences in the chlorpromazine equivalent dosages of total and atypical antipsychotic doses between patients with bipolar disorder and schizophrenia (Table 1).

VBM comparison of each patient group with the healthy controls

At a corrected threshold of $P < 0.01$, both patients with the schizophrenia and the schizoaffective disorder showed areas of volume reduction in relatively widely distributed and broadly similar cortical locations. In contrast, the patients with bipolar disorder showed no areas of volume reduction compared to the healthy controls. There were no areas of significant gray matter volume increase in any of the patient groups. The findings for the patients with schizophrenia and schizoaffective disorder are shown in Fig. 1, and the locations of the clusters are listed in Table 2.

Results for the above analyses at a corrected threshold of $P < 0.05$ are reported in the Supplementary Material. The findings in the patients with schizophrenia and schizoaffective disorder remained broadly similar, with both groups showing

Structural neuroimaging across mental disorders

Table 1. Demographic characteristics of patients with schizophrenia ($n = 45$), schizoaffective disorder ($n = 45$), and bipolar disorder ($n = 45$); and healthy controls ($n = 45$)

| | BD | SZ | SAD | HC | P-value |
|--------------------------------------|-------------|-------------|-------------|--------------|---------|
| Age (years) | 42.9 ± 9.2 | 43.2 ± 9.1 | 43.3 ± 9.0 | 43.3 ± 9.9 | n.s. |
| Sex (male/female) | 26/19 | 26/19 | 26/19 | 26/19 | n.s. |
| Estimated premorbid IQ (TAP) | 101.5 ± 8.5 | 100.1 ± 9.9 | 100.5 ± 9.8 | 101.0 ± 10.1 | n.s. |
| Current IQ (WAIS-III) | 92.0 ± 18.2 | 90.0 ± 16.2 | 88.9 ± 15.0 | 104.0 ± 16.5 | <0.001* |
| Duration of illness (years) | 17.6 ± 11.8 | 21.5 ± 9.8 | 18.8 ± 10.9 | n.a. | n.s. |
| Positive syndrome (PANSS) | 9.7 ± 5.3 | 13.3 ± 5.5 | 13.3 ± 5.7 | n.a. | 0.005† |
| Negative syndrome (PANSS) | 10.4 ± 6.1 | 17.8 ± 6.3 | 11.9 ± 6.4 | n.a. | <0.001‡ |
| Disorganized syndrome (PANSS) | 6.6 ± 2.6 | 10.7 ± 4.5 | 6.7 ± 2.3 | n.a. | <0.001‡ |
| YMRS score | 8.5 ± 10.9 | n.a. | 8.8 ± 9.8 | n.a. | n.s. |
| MADRS score | 13.8 ± 14.4 | n.a. | 11.3 ± 12.7 | n.a. | n.s. |
| Antipsychotic dose (CPZ equivalents) | 428 ± 565 | 852 ± 709 | 694 ± 602 | n.a. | 0.015§ |
| Typical | 49 ± 152 | 121 ± 335 | 154 ± 432 | n.a. | n.s. |
| Atypical | 379 ± 515 | 731 ± 554 | 541 ± 433 | n.a. | 0.012§ |
| Number receiving lithium | 15 | 2 | 8 | n.a. | 0.001§ |
| Number receiving anticonvulsants | 13 | 2 | 21 | n.a. | <0.001‡ |

Values are mean ± standard deviation.

HC, healthy controls; BD, bipolar disorder; SZ, schizophrenia; SAD, schizoaffective disorder; TAP, Word Accentuation Test (Test de Accentuación de Palabras); PANSS, Positive Syndrome Scale; WAIS-III, Wechsler Adult Intelligence Scale; CPZ equival., Chlorpromazine equivalents.

*Statistically significant differences between HC and all groups of patients.

†Statistically significant differences between SC and BIP, and between SAD and BIP.

‡Statistically significant differences between SAD and SC, and between BIP and SC.

§Statistically significant differences between BIP and SC.

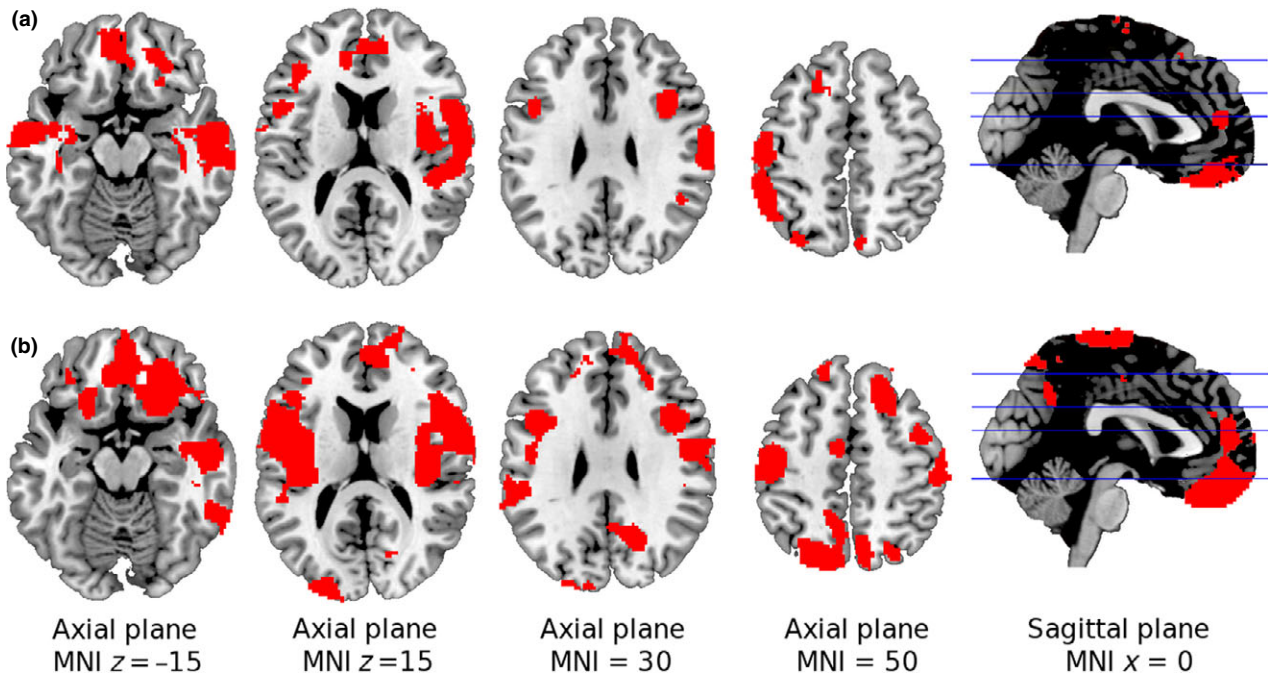


Fig 1. Brain regions showing significant gray matter volume reduction in patients with schizophrenia and schizoaffective disorder in relation to the healthy controls group ($n = 45$) at $P < 0.01$, corrected for multiple comparison across space via a threshold-free cluster enhancement procedure. Top panel (a) Volume reductions in the patients with schizophrenia ($n = 45$). Bottom panel (b) Volume reductions in the patients with schizoaffective disorder ($n = 45$). The patients with bipolar disorder showed no areas of volume reduction. The right side of the image is the right side of the brain.

widespread and overlapping areas of volume reduction. At this less conservative threshold, however, the patients with bipolar disorder also showed a cluster of significant gray matter volume

reduction located in the right middle temporal gyrus and also covering parts of the right superior temporal cortex [peak in MNI (54, -28, -8), $P < 0.02$].

Table 2. Results from the voxel-based morphometry analyses comparing the patients with schizophrenia ($n = 45$) and schizoaffective disorder ($n = 45$) with healthy controls ($n = 45$)

| Group comparison | MNI Coordinates (x,y,z) | P-value | Number of voxels | Breakdown (structures) |
|--------------------------------|-------------------------|---------|------------------|--|
| SZ vs. HC | | | | |
| Patients>HC (none) | | | | |
| Patients<HC | | | | |
| Right anterior cingulate | (1, 12, 49) | <0.005 | 3577 | Bilateral anterior cingulate and gyrus rectus |
| Left supplementary motor area | (-10, 20, 56) | <0.003 | 1651 | Left supplementary motor area and left superior frontal gyrus |
| Left paracentral lobule | (-7, -25, 76) | <0.01 | 97 | Left paracentral lobule |
| Left insula | (-38, 17, 6) | <0.0005 | 5347 | Left insula, rolandic operculum, hippocampus and superior, middle and inferior left temporal cortex |
| Right superior temporal cortex | (46, -29, 7) | <0.0002 | 6189 | Superior, middle and inferior right temporal cortex, right insula, rolandic operculum, and hippocampus |
| Right precuneus | (11, -62, 65) | <0.005 | 256 | Right precuneus |
| Left inferior parietal | (-48, -50, 52) | <0.003 | 1508 | Left inferior and superior parietal cortex and left postcentral |
| Right cerebellum | (20, -70, -38) | <0.001 | 811 | Right cerebellum |
| Left cerebellum | (-22, -64, -48) | <0.001 | 1184 | Left cerebellum |
| SAD vs. HC | | | | |
| Patients>HC (none) | | | | |
| Patients<HC | | | | |
| Right anterior cingulate | (4, 12, 50) | <0.001 | 6578 | Bilateral anterior cingulate cortex and gyrus rectus, bilateral superior frontal gyrus, and frontal medial orbital |
| Left paracentral lobule | (-4, -14, 72) | <0.001 | 6480 | Bilateral paracentral lobule, bilateral postcentral, parietal, supramarginal, supplementary motor area, and medium cingulate |
| Left insula | (-34, -6, 12) | <0.001 | 6659 | Left insula, rolandic operculum, and the superior, middle, and inferior left temporal cortex |
| Right superior temporal cortex | (56, -10, 6) | <0.0006 | 7238 | Superior, middle, and inferior right temporal cortex, right insula, rolandic operculum, and hippocampus. |
| Right cuneus | (20, -64, 32) | <0.003 | 1816 | Right cuneus, precuneus, calcarine, and superior occipital pole |
| Left occipital middle | (-27, -93, 10) | <0.003 | 3163 | Inferior, middle, and superior left occipital pole, left lingual, calcarine, and precuneus |
| Right cerebellum | (12, -56, -26) | <0.001 | 476 | Right cerebellum |
| Left cerebellum | (-22, -56, -34) | <0.0005 | 616 | Left cerebellum |

HC, healthy controls; SZ, schizophrenia; SAD, schizoaffective disorder; BD, bipolar disorder.

VBM comparisons among the patient groups

At $P < 0.01$ corrected, there were no areas of significant gray matter volume difference in any of the comparisons. At the less conservative corrected threshold $P < 0.05$, the patients with bipolar disorder showed areas of increased volume in the cerebellum as compared with the patients with schizophrenia (two main peaks: [peak 1 in MNI (22, -60, -48), $P < 0.02$; peak 2 in MNI (-20, -64, -46), $P < 0.02$]) and the patients with schizoaffective disorder ([peak in MNI (32, -60, -44), $P < 0.03$]).

VBM comparisons of the combined patient group with the healthy controls

At a corrected threshold of $P < 0.01$, this analysis revealed seven clusters of significant difference between the controls and the combined patient group, all representing volume reductions in the patients. One was centered in the medial frontal cortex bilaterally, including parts of the gyrus rectus, the anterior cingulate cortex, and

portions of the medial and superior frontal gyrus (three main peaks: [peak 1 in MNI (22, 30, -24), $P < 0.002$; peak 2 in MNI (4, 14, 48), $P < 0.006$; peak 3 in MNI (-18, 38, 38), $P < 0.002$]). There were also two bilateral clusters located in the superior frontal gyrus ($L > R$), with the cluster on the left also reaching the supplementary motor area and middle part of the cingulate gyrus (two main peaks: [peak 1 in MNI (-18, 38, 38), $P < 0.002$; peak 2 in MNI (20, 22, 48), $P < 0.006$]). Additionally, there was a large right-sided cluster including parts of the insula and rolandic operculum, the inferior, middle and superior temporal cortex, the hippocampus, and reaching the postcentral, parietal, supramarginal, paracentral lobule, and the supplementary motor area (three main peaks: [peak 1 in MNI (62, -2, 4), $P < 0.0006$; peak 2 in MNI (30, -74, 52), $P < 0.002$; peak 3 in MNI (2, 10, 36), $P < 0.009$]). Another large cluster was located in the left hemisphere, including parts of the insula and rolandic operculum, the inferior, middle, and superior temporal cortex, reaching the postcentral, parietal,

supramarginal, precentral lobule, and extending to the supplementary motor area (two main peaks: [peak 1 in MNI (-60, -2, -2), $P < 0.002$; peak 2 in MNI (-58, -18, 44), $P < 0.002$]). Finally, there were two bilateral clusters situated in the cerebellum ([peak 1 in MNI (-10, -62, -28), $P < 0.0006$; peak 2 in MNI (12, -62, -28), $P < 0.002$]).

The above seven clusters were first reduced to five, by combining the roughly symmetrical bilateral clusters in the superior frontal cortex and in the cerebellum. The mean gray matter volumes for each group in these five regions are shown in Fig. 2. At $P < 0.05$ correcting for multiple comparisons, there were no significant differences between the patients with schizoaffective disorder and schizophrenia in any of the regions. However, both patients with the schizophrenia and the schizoaffective disorder showed significantly greater volume reductions than the bipolar group in bilateral regions located in the temporo-insular-parietal cortex, as well as in the cerebellum.

Discussion

Main findings

The patients with schizophrenia and schizoaffective disorder in this study both showed a pattern of widespread gray matter volume reduction compared to healthy controls, whereas the patients with bipolar disorder did not. A subsequent analysis comparing the combined group of patients with the controls followed by extraction of clusters found that, in regions where the patients differed significantly from the controls, the changes were uniformly in the direction of greater volume loss in the patients with schizophrenia and schizoaffective disorder than in the patients with bipolar disorder, although the differences were not always significant.

As noted in the introduction, only two other studies to date have examined schizoaffective disorder using VBM. In the first of these (24), which was carried out on small numbers of subjects (<20 in each group), the patients with schizophrenia and schizoaffective disorder, but not the patients with bipolar disorder showed volume reductions compared to healthy controls; the changes also appeared to be considerably more extensive in the patients with schizophrenia than the patients with schizoaffective disorder. The second, much larger, study (25) had findings similar to ours: 146 patients with schizophrenia and 90 patients with schizoaffective disorder showed gray matter volume reductions compared to 200 healthy controls in

numerous and overlapping areas, whereas changes in 115 patients with psychotic bipolar disorder were restricted to a single cluster in the frontotemporal cortex.

In contrast, neither our study nor that of Ivleva et al. (25) found significant differences when the three patient groups were compared with each other. At 45 per group, numbers in our study were reasonably large and sufficient to show differences from healthy controls. In the study of Ivleva et al. (25), the numbers were much larger, although the fact that they obtained MRI data from four different centers would have inevitably introduced noise into the analysis. A plausible explanation for the negative findings here is that differences between groups of patients characterized by greater or lesser degrees of volume reduction will always be smaller than the differences from healthy controls (25). In this respect, it is interesting to note that, while Ellison-Wright and Bullmore (22) found evidence for more extensive volume reductions in schizophrenia than bipolar disorder in their meta-analysis of VBM studies, a later meta-analysis by Bora et al. (23) found that the differences became considerably less marked when the predominance of male patients in the schizophrenia studies, they included was corrected for. De Peri et al. (37) also found largely similar whole-brain volume reductions in first-episode patients with schizophrenia and bipolar disorder in a meta-analysis of conventional MRI studies, although gray matter reductions were somewhat more pronounced in the former and white matter reductions in the latter.

Findings in the patients with schizophrenia and bipolar disorder

The volume reductions we found in the schizophrenic group affected the medial frontal cortex, the insula, the pre- and postcentral gyri, the hippocampus, parts of the temporal lobe cortex, the precuneus, the inferior parietal cortex, and the cerebellum. These are in reasonable agreement with the results of other studies of schizophrenia; in particular, all of the changes apart from those in the precuneus and inferior parietal cortex were identified in a systematic review of meta-analyses of VBM studies (38).

On the other hand, the bipolar group showed no areas of brain volume reduction compared to the controls. This finding goes against those of other VBM studies of patients with bipolar disorder, meta-analyses of which have found the anterior cingulate cortex, the insula, and the inferior frontal cortex to show volume reductions, among other areas (22, 39, 40). The likeliest explanation of our failure to detect differences is the use of a restrictive

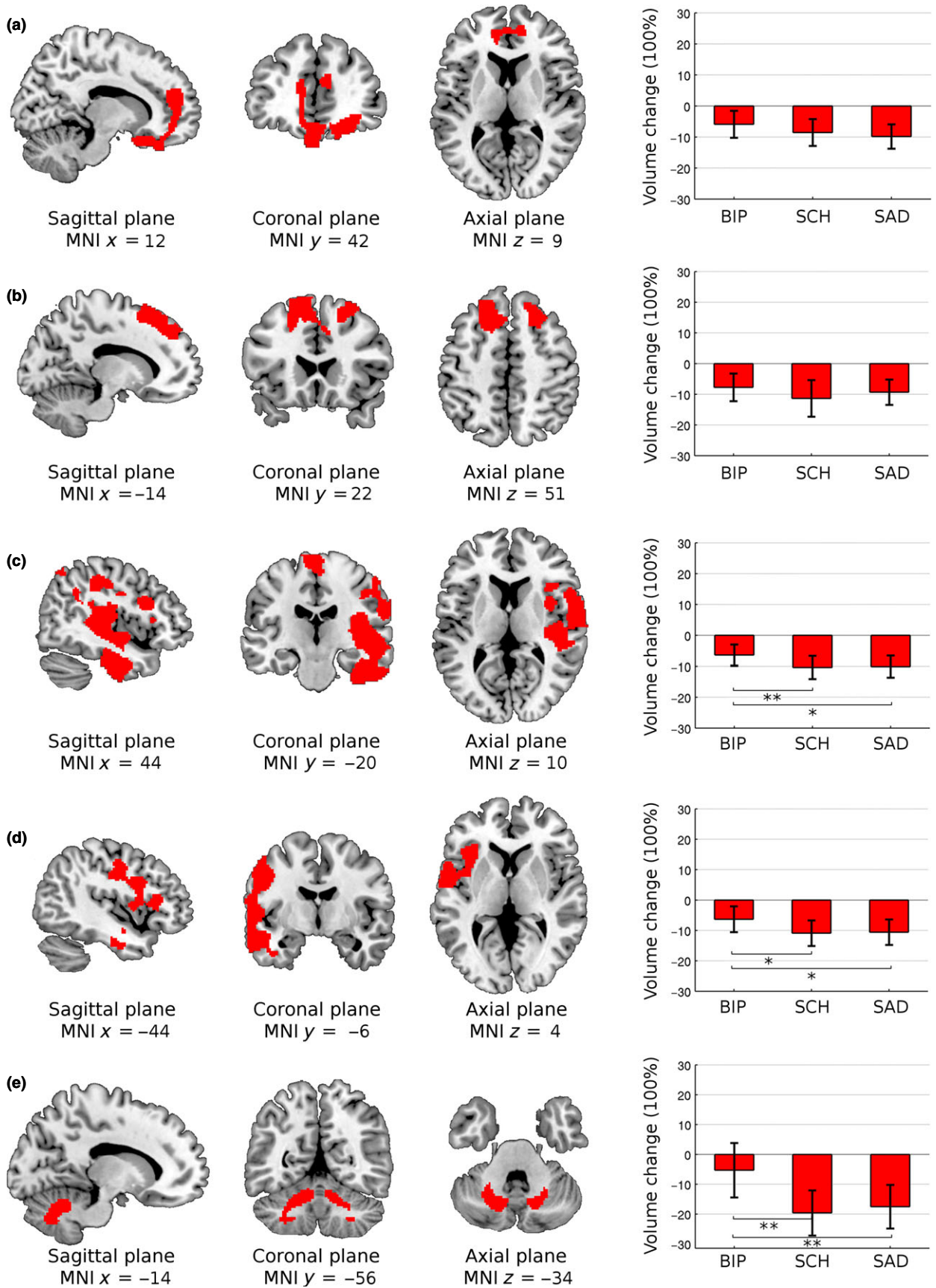


Fig 2. Comparisons of gray matter volume reduction averaged over the clusters in schizoaffective disorder ($n = 45$), schizophrenia ($n = 45$), and bipolar disorder ($n = 45$) in the following regions: (a) ventromedial prefrontal cortex, (b) bilateral frontal superior cortex, (c) right temporo-insular-parietal areas, (d) left temporo-insular-parietal areas, and (e) bilateral cerebellum. Boxplots are based on mean percentage of volume reduction compared to the healthy controls group. ** individual t -tests significant at a corrected $P < 0.01$, * significant at a corrected $P < 0.05$. The right side of the image is the right side of the brain.

threshold of at a $P = 0.01$ corrected. In support of this, when we used a more liberal threshold of $P = 0.05$ corrected a cluster of volume reduction emerged in the right temporal lobe cortex.

Similarities and differences between the schizoaffective and schizophrenic brain changes

Gray matter volume reductions in the patients with schizoaffective disorder followed a substantially similar pattern to those seen in the patients with schizophrenia: in both groups, changes were seen in the medial frontal cortex, a large region incorporating the insula, the rolandic operculum, parts of the temporal lobe, and the hippocampus. There were also volume reductions in the pre- and post-central cortex, the supplementary motor area, and the cerebellum in both patient groups. The overlap, however, was not complete: areas affected in the patients with schizophrenia but not the patients with schizoaffective disorder included the left inferior parietal cortex, the supplementary motor area, and the right precuneus; in contrast, the right precuneus and the left occipital cortex were affected in the patients with schizoaffective disorder but not the patients with schizophrenia.

These differences might simply have reflected sampling error—it seems possible that if two groups of patients with schizophrenia of the size we used were compared to the same group of healthy controls, differences might also have emerged. Another possibility is that the differences found reflected the symptomatic differences of the two disorders, for example, the lack of major mood change in schizophrenia, or a lesser degree of negative symptoms in schizoaffective disorder. In this respect, it is interesting to note that neither the right precuneus and the left occipital cortex that were affected in the patients with schizoaffective disorder but not the patients with schizophrenia appeared in Shepherd et al.'s (38) review of meta-analyses of VBM studies of schizophrenia. On the other hand, the view that negative symptoms (or other schizophrenic symptoms) have brain structural correlates is far from clearly established (41–47).

Nosological implications

What consequences do our findings have for the nosological status of schizoaffective disorder? They

are clearly incompatible with the argument that schizoaffective disorder is a variant of bipolar disorder (5, 48, 49). Nor are they easy to reconcile with the longstanding—and currently highly topical—proposal that schizoaffective disorder represents the midpoint along a continuum of psychosis, as conceptualized either genetically (6, 13), clinically (8, 50, 51), or both (52). This would predict less volume change in schizoaffective disorder than in schizophrenia, something that none of the analyses carried out in this study supported.

Our and Ivleva et al.'s (25) findings appear most compatible with schizoaffective being a variant of schizophrenia. This is a proposal that is currently unfashionable to the extent that it is difficult to find publications that have advocated it since Lehman et al. (e.g., 4), over thirty years ago (4). Another less controversial possibility might be that schizoaffective disorder is an intermediate form of illness, but one that is, for unknown reasons, skewed toward schizophrenia.

Strengths of the study

In our study, we used both DSM-IV and RDC criteria for schizoaffective disorder, with the latter being widely regarded as providing the particularly rigorous and detailed diagnostic guidelines. Both criteria require the presence of delusions or hallucinations for at least 2 weeks in the absence of prominent mood symptoms, and so, in practice mean that there must be some separation between psychotic and affective symptoms in a particular episode. This has the advantage of avoiding confusion with psychotic forms of bipolar disorder, something to which ICD-10 criteria are vulnerable, because they do not require the absence of affective in the presence of psychotic symptoms. Perhaps in line with this Jäger et al. (2) found that patients meeting DSM-IV criteria for schizoaffective disorder had a more unfavorable outcome than patients diagnosed following ICD-10 criteria.

The VBM analyses were performed using standard validated procedures and TFCE correction for multiple comparisons, a relatively new technique that may be more sensitive to detect the underlying morphological differences than other available approaches (53).

Limitations

We examined groups of patients with schizoaffective disorder and bipolar disorder with mixed, that is, manic, depressed and euthymic, presentations, and the majority of the bipolar sample presented with a history of psychotic symptoms but not all of them. Both might have potentially influences results. We also did not match the patients with schizoaffective disorder and the patients with bipolar disorder for numbers of episodes of illness, principally because this presented difficulties in the patients with schizoaffective disorder. Beyond this, our samples were made up exclusively of right-handed patients, which could represent a sampling bias, as left-handedness has been found to be over-represented in schizophrenia. We excluded current drug or alcohol abuse, but data on substance abuse in the past were not systematically collected and could have differed between groups. Finally and in common with other neuroimaging studies of psychosis, the patients were medicated, which both in the case of antipsychotics (54, 55) and lithium (56) has the potential to influence brain volume (23).

Acknowledgements

This work was supported by the Centro de Investigación Biomédica en Red de Salud Mental (CIBERSAM); from the Catalan Government (2009SGR211 to the Research Unit of Benito Menni and 2009SGR1022 to Hospital Clinic Bipolar Disorders Unit) and grant support from the Instituto de Salud Carlos: Stabilization Contract grant to B.L. Amann (CES 12/024) Miguel Servet Research Contracts to R. Salvador (CP07/00048), and to E. Pomarol-Clotet (CP10/00596); Intensification grant to S. Sarró (10/231); Research Projects to B.L. Amann (PI07/1278 and PI10/02622), E. Pomarol-Clotet (PI10/01058), R. Salvador (PI05/1874), and E. Vieta (PI09/1893).

Declarations of interests

Dr. BL Amann has served as speaker for Janssen, Lundbeck, and Otsuka. Dr. Goikolea has served as speaker or advisor for the following companies: Astra-Zeneca, Bristol-Myers Squibb, Eli Lilly, Glaxo-Smith-Kline, Janssen-Cilag, Merck Sharpe and Dohme, Otsuka, Pfizer, Sanofi-Aventis, and Lundbeck. Dr. Vieta has received grants and served as consultant, advisor or CME speaker for the following entities: AstraZeneca, Bristol-Myers Squibb, Elan, Eli Lilly, Ferrer, Forest Research Institute, Gedeon Richter, Glaxo-Smith-Kline, Janssen, Lundbeck, Otsuka, Pfizer, Roche, Sanofi-Aventis, Servier, Sunovion, Takeda, Teva, the Spanish Ministry of Science and Innovation (CIBERSAM), the Seventh European Framework Programme (ENBREC), and the Stanley Medical Research Institute. The rest of the authors have declared that there are no conflict of interests in the last 2 years.

References

1. KASANIN K. The acute schizoaffective psychoses. *Am J Psychiatry* 1933;**90**:97–126.

2. JÄGER M, HAACK S, BECKER T, FRASCH K. Schizoaffective disorder—an ongoing challenge for psychiatric nosology. *Eur Psychiatry* 2011;**26**:159–165.
3. PROCCI WR. Schizo-affective psychosis: fact or fiction? A survey of the literature. *Arch Gen Psychiatry* 1976;**33**:1167–1178.
4. LEHMAN H. Schizophrenia: clinical features. In: FREEDMAN A, KAPLAN H, SADDOK J, eds. *Comprehensive textbook of psychiatry*. Baltimore, MD: Williams & Wilkins; 1975: 457–486.
5. POPE HG Jr, LIPINSKI JF, COHEN BM, AXELROD DT. “Schizoaffective disorder”: an invalid diagnosis? A comparison of schizoaffective disorder, schizophrenia, and affective disorder *Am J Psychiatry* 1980;**137**:921–927.
6. CROW TJ. The continuum of psychosis and its implication for the structure of the gene. *Br J Psychiatry* 1986;**149**: 419–429.
7. LAKE CR, HURWITZ N. Schizoaffective disorders are psychotic mood disorders; there are no schizoaffective disorders. *Psychiatry Res* 2006;**143**:255–287.
8. CHENIAUX E, LANDEIRA-FERNANDEZ J, LESSA TELLES L et al. Does schizoaffective disorder really exist? A systematic review of the studies that compared schizoaffective disorder with schizophrenia or mood disorders *J Affect Disord* 2008;**106**:209–217.
9. PAGEL T, BALDESSARINI RJ, FRANKLIN J, BAETHGE C. Characteristics of patients diagnosed with schizoaffective disorder compared with schizophrenia and bipolar disorder. *Bipolar Disord* 2013;**15**:229–239.
10. MCKENNA P. *Schizophrenia and related syndromes*, 2nd edn. Hove, UK: Routledge, 2007.
11. CORYELL W, ZIMMERMAN M. The heritability of schizophrenia and schizoaffective disorder. A family study. *Arch Gen Psychiatry* 1988;**45**:323–327.
12. MAIER W, LICHTERMANN D, MINGES J et al. Continuity and discontinuity of affective disorders and schizophrenia. Results of a controlled family study. *Arch Gen Psychiatry* 1993;**50**:871–883.
13. LAURSEN TM, LABOURIAU R, LICHT RW, BERTELSEN A, MUNK-OLSEN T, MORTENSEN PB. Family history of psychiatric illness as a risk factor for schizoaffective disorder: a Danish register-based cohort study. *Arch Gen Psychiatry* 2005;**62**:841–848.
14. BERTELSEN A, GOTTESMAN II. Schizoaffective psychoses: genetic clues to classification. *Am J Med Genet* 1995;**60**:7–11.
15. HAIJMA SV, VAN HAREN N, CAHN W, KOOLSCHIJN PC, HULSHOFF POL HE, KAHN RS. Brain volumes in schizophrenia: a meta-analysis in over 18 000 subjects. *Schizophr Bull* 2013;**39**:1129–1138.
16. ARNONE D, CAVANAGH J, GERBER D, LAWRIE SM, EBMEIER KP, MCINTOSH AM. Magnetic resonance imaging studies in bipolar disorder and schizophrenia: meta-analysis. *Br J Psychiatry* 2009;**195**:194–201.
17. KEMPTON MJ, GEDDES JR, ETTINGER U, WILLIAMS SC, GRASBY PM. Meta-analysis, database, and meta-regression of 98 structural imaging studies in bipolar disorder. *Arch Gen Psychiatry* 2008;**65**:1017–1032.
18. RIEDER RO, MANN LS, WEINBERGER DR, van KAMMEN DP, POST RM. Computed tomographic scans in patients with schizophrenia, schizoaffective, and bipolar affective disorder. *Arch Gen Psychiatry* 1983;**40**:735–739.
19. GETZ GE, DELBELLO MP, FLECK DE, ZIMMERMAN ME, SCHWIERS ML, STRAKOWSKI SM. Neuroanatomic characterization of schizoaffective disorder using MRI: a pilot study. *Schizophr Res* 2002;**55**:55–59.
20. RADONIC E, RADOS M, KALEMBER P, BAJA-JANOVIC M, FOLNEGOVIC-SMALC V, HENIGSBERG N. Comparison of hippocampal

- volumes in schizophrenia, schizoaffective and bipolar disorder. *Coll Antropol* 2011;**35**(Suppl 1):249–252.
21. SMITH MJ, WANG L, CRONENWETT W, MAMAH D, BARCH DM, CSERNANSKY JG. Thalamic morphology in schizophrenia and schizoaffective disorder. *J Psychiatr Res* 2011;**45**:378–385.
 22. ELLISON-WRIGHT I, BULLMORE E. Anatomy of bipolar disorder and schizophrenia: a meta-analysis. *Schizophr Res* 2010;**117**:1–12.
 23. BORA E, FORNITO A, YUCEL M, PANTELIS C. The effects of gender on grey matter abnormalities in major psychoses: a comparative voxelwise meta-analysis of schizophrenia and bipolar disorder. *Psychol Med* 2012;**42**:295–307.
 24. IVLEVA EI, BIDESI AS, THOMAS BP et al. Brain gray matter phenotypes across the psychosis dimension. *Psychiatry Res* 2012;**204**:13–24.
 25. IVLEVA EI, BIDESI AS, KESHAVAN MS et al. Gray matter volume as an intermediate phenotype for psychosis: bipolar-Schizophrenia Network on Intermediate Phenotypes (B-SNIP). *Am J Psychiatry* 2013 Nov;**170**:1285–1296.
 26. HECKERS S. Diagnostic criteria for schizoaffective disorder. *Expert Rev Neurother* 2012;**12**:1–3.
 27. SPITZER RL, ENDICOTT J, ROBINS E. Research diagnostic criteria: rationale and reliability. *Arch Gen Psychiatry* 1978;**35**:773–782.
 28. del SER T, GONZALEZ-MONTALVO JI, MARTINEZ-ESPINOSA S, DELGADO-VILLAPALOS C, BERMEJO F. Estimation of premorbid intelligence in Spanish people with the Word Accentuation Test and its application to the diagnosis of dementia. *Brain Cogn* 1997;**33**:343–356.
 29. GOMAR JJ, ORTIZ-GIL J, McKENNA PJ et al. Validation of the Word Accentuation Test (TAP) as a means of estimating premorbid IQ in Spanish speakers. *Schizophr Res* 2011;**128**:175–176.
 30. NELSON HE, WILLISON JR. The revised national adult reading test. Windsor, Berkshire: NFER-Nelson, 1991.
 31. WILKINSON GS. Wide range achievement test 3. Wilmington, DE: Wide Range, Inc, 1993.
 32. ASHBURNER J, FRISTON KJ. Voxel-based morphometry – the methods. *NeuroImage* 2000;**11**:805–821.
 33. SMITH SM, JENKINSON M, WOOLRICH MW et al. Advances in functional and structural MR image analysis and implementation as FSL. *NeuroImage* 2004;**23**(Suppl 1):S208–S219.
 34. SMITH SM. Fast robust automated brain extraction. *Hum Brain Mapp* 2002;**17**:143–155.
 35. SMITH SM, NICHOLS TE. Threshold-free cluster enhancement: addressing problems of smoothing, threshold dependence and localisation in cluster inference. *NeuroImage* 2009;**44**:83–98.
 36. YUKSEL C, MCCARTHY J, SHINN A et al. Gray matter volume in schizophrenia and bipolar disorder with psychotic features. *Schizophr Res* 2012;**138**:177–182.
 37. de PERI L, CRESCINI A, DESTI G, FUSAR-POLI P, SACCHETTI E, VITA A. Brain structural abnormalities at the onset of schizophrenia and bipolar disorder: a meta-analysis of controlled magnetic resonance imaging studies. *Curr Pharm Des* 2012;**18**:486–494.
 38. SHEPHERD AM, LAURENS KR, MATHESON SL, CARR VJ, GREEN MJ. Systematic meta-review and quality assessment of the structural brain alterations in schizophrenia. *Neurosci Biobehav Rev* 2012;**36**:1342–1356.
 39. BORA E, FORNITO A, YUCEL M, PANTELIS C. Voxelwise meta-analysis of gray matter abnormalities in bipolar disorder. *Biol Psychiatry* 2010;**67**:1097–1105.
 40. SELVARAJ S, ARNONE D, JOB D et al. Grey matter differences in bipolar disorder: a meta-analysis of voxel-based morphometry studies. *Bipolar Disord* 2012;**14**:135–145.
 41. MITELMAN SA, BUCHSBAUM MS. Very poor outcome schizophrenia: clinical and neuroimaging aspects. *Int Rev Psychiatry* 2007;**19**:345–357.
 42. KOUTSOULERIS N, GASER C, JAGER M et al. Structural correlates of psychopathological symptom dimensions in schizophrenia: a voxel-based morphometric study. *NeuroImage* 2008;**39**:1600–1612.
 43. GALDERISI S, MAJ M. Deficit schizophrenia: an overview of clinical, biological and treatment aspects. *Eur Psychiatry* 2009;**24**:493–500.
 44. CASCELLA NG, FIELDSTONE SC, RAO VA, PEARLSON GD, SAWA A, SCHRETTLEN DJ. Gray-matter abnormalities in deficit schizophrenia. *Schizophr Res* 2010;**120**:63–70.
 45. NENADIC I, SAUER H, GASER C. Distinct pattern of brain structural deficits in subsyndromes of schizophrenia delineated by psychopathology. *NeuroImage* 2010;**49**:1153–1160.
 46. BENOIT A, BODNAR M, MALLA AK, JOOBER R, LEPAGE M. The structural neural substrates of persistent negative symptoms in first-episode of non-affective psychosis: a voxel-based morphometry study. *Front Psychiatry* 2012;**3**:42.
 47. VOINESKOS AN, FOUSSIAS G, LERCH J et al. Neuroimaging evidence for the deficit subtype of schizophrenia. *JAMA Psychiatry* 2013;**70**:472–480.
 48. CLAYTON PJ, RODIN L, WINOKUR G. Family history studies. 3. Schizoaffective disorder, clinical and genetic factors including a one to two year follow-up. *Compr Psychiatry* 1968;**9**:31–49.
 49. DELL'OSSO L, AKISKAL HS, FREER P, BARBERI M, PLACIDI GF, CASSANO GB. Psychotic and nonpsychotic bipolar mixed states: comparisons with manic and schizoaffective disorders. *Eur Arch Psychiatry Clin Neurosci* 1993;**243**:75–81.
 50. MARNEROS A, DEISTER A, ROHDE A. Psychopathological and social status of patients with affective, schizophrenic and schizoaffective disorders after long-term course. *Acta Psychiatr Scand* 1990;**82**:352–358.
 51. KENDLER KS, MCGUIRE M, GRUENBERG AM, WALSH D. Examining the validity of DSM-III-R schizoaffective disorder and its putative subtypes in the Roscommon Family Study. *Am J Psychiatry* 1995;**152**:755–764.
 52. van Os J, KAPUR S. Schizophrenia. *Lancet* 2009;**374**:635–645.
 53. RADUA J, CANALES-RODRIGUEZ EJ, POMAROL-CLOTET E, SALVADOR R. Validity of modulation and optimal settings for advanced voxel-based morphometry. *NeuroImage* 2014;**86**:81–90.
 54. NAVARI S, DAZZAN P. Do antipsychotic drugs affect brain structure? A systematic and critical review of MRI findings. *Psychol Med* 2009;**39**:1763–1777.
 55. VITA A, de PERI L, DESTI G, SACCHETTI E. Progressive loss of cortical gray matter in schizophrenia: a meta-analysis and meta-regression of longitudinal MRI studies. *Transl Psychiatry* 2012;**2**:e190.
 56. LYOO IK, DAGER SR, KIM JE et al. Lithium-induced gray matter volume increase as a neural correlate of treatment response in bipolar disorder: a longitudinal brain imaging study. *Neuropsychopharmacology* 2010;**35**:1743–1750.

Supporting Information

Additional Supporting Information may be found in the online version of this article:

Data S1. Supplementary Material.