



ELENA FIORIN, ALBERT ISIDRO, DOUGLAS H. UBELAKER, ASSUMPCIÓ MALGOSA

## A CONGENITAL STERNUM ANOMALY FROM A LATE ROMAN BURIAL FROM PALMA MALLORCA, SPAIN

**ABSTRACT:** *A curious case of a congenital non fusion of the caudal portion of the sternum was found in the skeletal remains of a juvenile male recovered from a Late Roman burial from the Necropolis of Pollentia, Palma Mallorca, Spain. No other significant changes in the skeleton or pathological disorders were observed and potentially health problems, due to this anomaly, can not be determined. This kind of congenital defect is unusual and there are a few cases reported in paleopathological literature. Despite the fact that the sternum is one of the bones of the body with a wider variety of congenital variants, generally the described cases focus on the most frequent anomalies, such as pectus excavatum or sternal aperture, whereas the rarest variations, such as sternal bifid/cleft or failure of fusion of the caudal portion are not reported.*

**KEY WORDS:** *Sternum - Congenital anomalies - Developmental defect - Late Roman - Spain*

### INTRODUCTION

There is a wide spectrum of anomalies of the chest wall and, among the different types, *pectus* deformities are found in as many as one in 300 live births (Mathes *et al.* 2006). *Pectus excavatum* (or funnel chest) is the most common and this deformity makes up 90% of anterior chest wall deformities. It is present in between one in 400 and one in 1000 live births (Restrepo *et al.* 2009) and, although most cases are isolated, it appears to be a strong genetic component (Fokin *et al.* 2009). *Pectus carinatum* (protrusion of the sternum) represents a less

common abnormality, being present in one in 1500 live births (Restrepo *et al.* 2009). Sternal cleft (or fissure) is even rarer, having been observed in 0.15% of a series of 5182 patients (Acastello *et al.* 2003).

On the other hand, some morphological variants have been incidentally detected during radiological examination. *Sternal aperture* is the most common of these anomalies and has been reported to be present in 4% of European sterna (Ashley 1956). However, other studies have detected this anomaly in 6.7–16.6% of individuals examined in a modern forensic context (Babinski *et al.* 2012, Cooper *et al.* 1988).

---

Received 11 November 2014; accepted 11 June 2015.

© 2016 Moravian Museum, Anthropos Institute, Brno. All rights reserved.

In the paleopathological literature there are few studies focusing on congenital anomalies of the sternum (Brothwell 1981, Barnes 1994). Usually, the cases describe the most frequent anomalies, such as *pectus excavatum*, *carinatum* and sternal aperture (Fily *et al.* 2001, Groves *et al.* 2003, Tóth, Buda 2001). However, the work about sternal defects conducted by Farkas *et al.* (2004) on a large medieval osteological sample, identified different kinds of anomalies affecting breast bones demonstrating that both rare and frequent anomalies could be found in ancient skeletal remains. In spite of the potential health problems that this kind of defects can cause, they could not be reported in general. We must take into account that the real problem is in the viscera that sternum protect more than in the bony defect itself.

The aim of the present study is to report an unusual congenital anomaly of the sternum from a Late Roman context in Spain. This type of defect is rare and not properly described in paleopathological literature. Also few cases are illustrated in clinical practice.

### Individual description

The analyzed sternum belongs to an individual buried in the Necropolis of Can Reiners, located in *Pollentia* (Palma Mallorca, Spain), the most important Roman city in the Balearic Islands. The Necropolis was located in the central area of the *Forum* and has been excavated since the 1980's. Although the exact chronology of the use of the cemetery is not clear yet, it dates back to around 600 AD, when the forum was abandoned (Orfila 2000) and this area attained funerary uses. Anthropological analyses have been conducted on more than 200 individuals (Díaz de Villabona 2010, García Sivoli 2009, Ortega *et al.* 2003).

The individual come from the grave CR-16.1 that contained a single skeleton buried in a supine position with the upper limbs crossed above the abdominal region. No grave goods were found inside the burial. Although almost the entire skeleton was present, the state of preservation was poor. The ribs were incomplete and damaged, and the total chest wall could not be reconstructed.

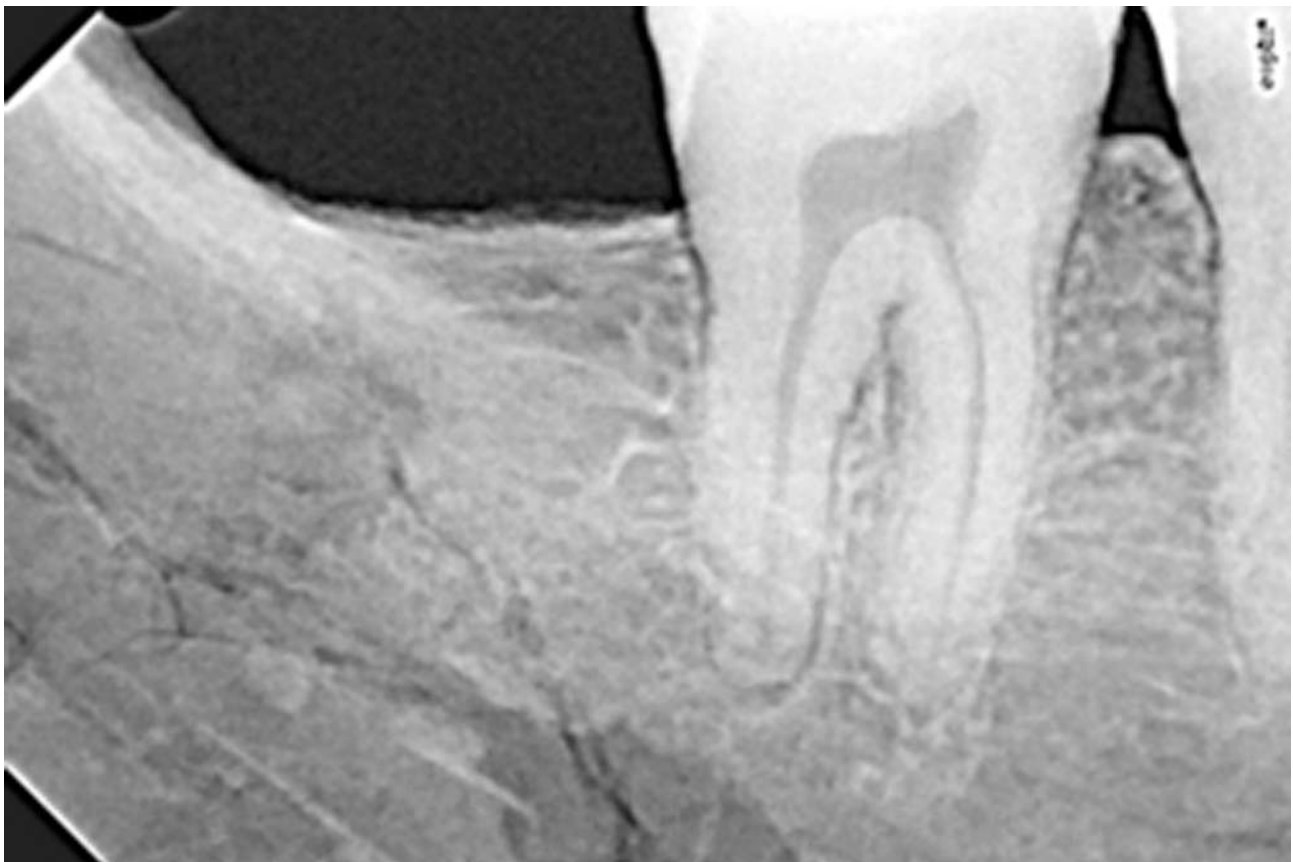

FIGURE 1: Radiograph of the roots of the left second molar and the third molar agenesis.

Sex was determined using cranial and pelvis morphology (Ferembach *et al.* 1979, Buikstra, Ubelaker 1994). The cranium showed large and rounded mastoid processes, a marked nuchal crest and protruding supra-orbital ridges and the *os coxae* exhibited narrow sciatic notches, all this indicating male sex.

Age at death was based on bone growth (Scheuer, Black 2000, Ubelaker 1989b) and dental maturity (Crétot 1978, Ubelaker 1989a). Regarding bone growth, proximal epiphyses of the humeri were separated but the distal ones were fused, while the proximal and distal epiphyses of the femurs, tibiae and fibulae were also fused. Although the ilium, pubis and ischium were fused together, the iliac crest was not. The roots of the second molars were completely formed, but the individual presented third molar agenesis (*Figure 1*). Taking all this into account, the

anthropological data suggest that the skeleton belonged to a male and his age at death was probably between 17 and 21 years.

Concerning pathologies, linear enamel hypoplasia in the mandibular teeth could be observed. No carious lesions were found. Osteochondritis in the proximal facet of the third right metatarsal bone and in the corresponding facet of third cuneiform was also visible. No other anomalies or pathologies have been found, with the exception of the sternum ossification.

### The sternum

The individual showed a normal manubrium but exhibited a partial sternal cleft affecting the inferior part of the body (*Figure 2*). The mesosternum was divided into four elements. The first sternebra consisted of a unique bone element. The second sternebra was divided into two slightly asymmetric

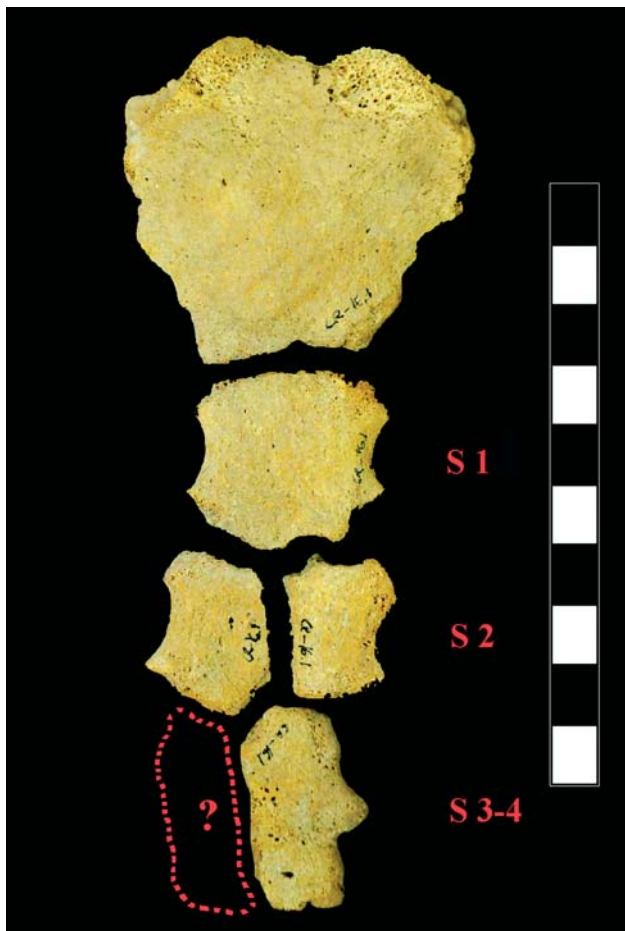


FIGURE 2: The sternum of the individual CR 16.1.

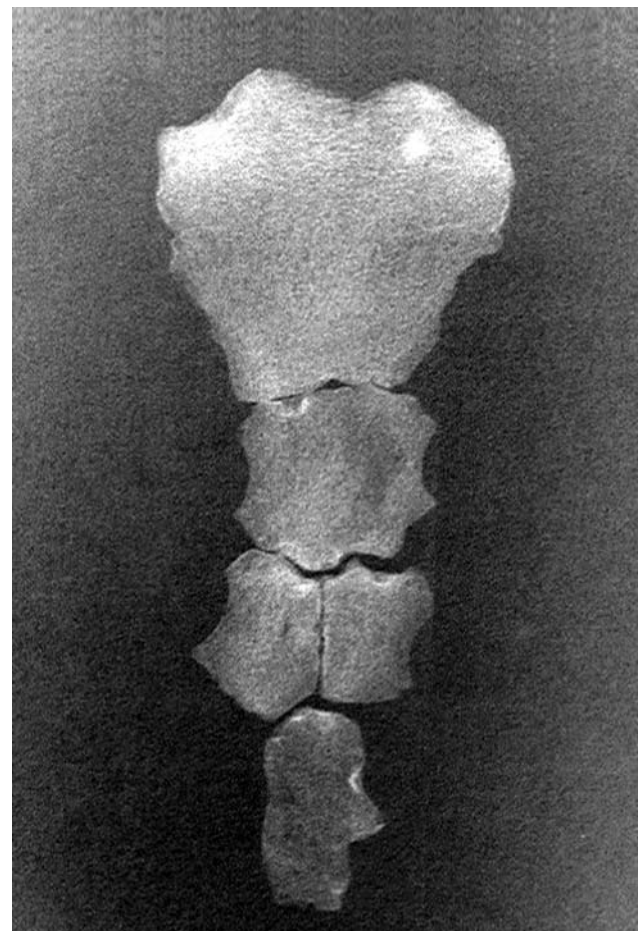


FIGURE 3: Radiograph of CR 16.1 sternum.

elements. The third and fourth sternebrae were divided lengthwise into two parts, but only the left part was found and presented fusion of these two sternebrae. The xiphoid process was absent. Recording of standard measurements was limited because the body was not fused. The manubrium length (midsagittal distance from the jugular notch to the manubriosternal junction) measured 45 mm, which usually suggests female sex (Bongiovanni, Spradley 2012). The width at first sternebra (S1, minimum distance of the first segment of the body) was 27 mm, consistent with values reported for males (Bongiovanni, Spradley 2012). This size variation reflects its irregular form and reinforces the anomalous morphology of the male specimen.

Radiological examination revealed a homogeneous image with a light density despite the low X-ray penetration (*Figure 3*). The manubrium exhibited a slight iuxta-articular subchondral sclerosis of the sternoclavicular joints, in particular on the left side. It also displayed a lacunar image compatible with a bone infarction vs. enostosis. On the right side of the superior margin of the first sternebra, where it articulates with the manubrium, the radiographic image showed a subchondral cyst that displayed a spherical shape. On the left side, there was a decrease in the radiological signal without clinical significance. The image of the second sternebra showed a clear asymmetry with a weak subchondral sclerosis in the superior margin. The medial joint line did not exhibit signs of movement between the two parts of the sternebra.

The image of the third and fourth sternebrae showed significant subchondral sclerosis on the left costosternal joints. Moreover, the most distal part of the bone exhibited a slightly mottled intraosseous pattern. Overall, the radiological image did not provide any information about pathology.

## DISCUSSION

The early development of the sternum is formed in the embryo around the sixth week of gestation (Zalel *et al.* 1999). A pair of lateral cartilaginous sternal plates appears in this period: they are independent of each other and begin to fuse in the midline along the craniocaudal direction around the ninth fetal week when the ribs start to increase in length. The mesenchymal bars only fuse when the heart has descended to the thorax (Scheuer, Black 2000).

The first center of ossification appears in the 6<sup>th</sup> month and it involves the manubrium and the upper part of the sternal body. Progressively, centers appear in the 7<sup>th</sup> month at the middle of the sternal body, during the 1<sup>st</sup> postnatal year in the lower part of the body and between years five and 18 in the xiphoid process (Zalel *et al.* 1999). The time of appearance and the number and the pattern of ossification vary among individuals (Riach 1967). At the age of three-six years all sternebrae can be found as isolated elements.

The direction of the fusion of the sternebrae is caudo-cranial and takes place between years four and 25. The first sternebrae to fuse are the third and the fourth (four-eight years). They fuse with the second sternebra around puberty (11–16 years) and the last fusion between the second and first sternebra usually occurs between 15 and 20 years (Scheuer, Black 2000). At 21 years the body of the sternum is complete, although lines of fusion can persist until 25 years.

The individual CR-16.1 shows a not frequent condition. He was an almost adult individual but he shows the development of the sternum similar to those of six years (Scheuer, Black 2000) with shaped manubrium, S1 completed, S2 divided and S3 and S4 developed without sternebra fusion.

In the clinical literature, different types of congenital anomalies of the sternum are described. Some of them require treatment because they could affect vital internal structures; by contrast there are others, such as sternal aperture, that are asymptomatic and do not require treatment. *Pectus excavatum* is the most common sternum anomaly and is characterized by its posterior displacement, and as a consequence, the ribs protrude anteriorly. In contrast, the sternum in *pectus carinatum* is anteriorly displaced. The anomalous manubrium-mesosternal joint is much more uncommon. It occurs when the fibrous lamina is misplaced between the first and the second sternebrae, instead of between the manubrium and the first sternebra (Barnes 2012). The incomplete cohesion of a portion of the lower end of the embryonic sternal bands generates the sternal foramen that develops in the third and fourth segment of the mesosternum. *Synchondrosis sternii* can appear as incomplete ossification of the sternum retaining some space between the sternebrae. Finally, sternal cleft (or fissure) is a rare malformation characterized by a medial longitudinal fissure due to a partial or total failure of sternal fusion at an early stage of embryonic development (Nuss, Kelly 2009). The fissure may be occupied by a fibrous membrane. This congenital malformation can be total or partial (superior or



inferior) (Canepa, Stella 2002). In medicine literature cleft sternum is reported associated with other anomalies like craniofacial emangiomas or other vascular malformations. The inferior cleft usually is related to Cantrell's pentalogy, a syndrome that include cardiac malformations (Tuncer *et al.* 2009).

However no pathologies are unequivocally associated with partial sternal cleft and sometimes are a simply radiographic report. Taking into account the absence of other anomalies or pathological skeletal problems in CR-16.1, asymptomatic condition must be considered, despite other health circumstances affecting thoracic organs could not be excluded.

Regarding the paleopathological literature, the first description comes from Brothwell (1981: 171–172) who described several congenital anomalies. He briefly listed a number of minor deformities and regarding breast bones stated that "*occasionally the body of a sternum is found to be segmented in the adult*" and displayed a picture of several sternums with anomalies from Anglo-Saxon and early Nubian skeletal remains. Twenty years later, Fily *et al.* (2001) described a case of sternal aperture in an adult male from Nagada IIA predynastic burial of Adaima, Upper Egypt dating around 3400 B.C. Two cases of *pectus excavatum* are described by Tóth and Buda (2001). These breast bones came from a cemetery of the 10<sup>th</sup>–16<sup>th</sup> centuries in Transdanubia, Hungary, and one of them belonged to an adult female. Groves *et al.* (2003) found a *pectus carinatum* in a skeleton of a young adult female buried in the Ripon Cathedral in North Yorkshire in the late 15<sup>th</sup> century AD. The skeleton revealed various changes to the bones of the thoracic cavity. The condition of sternal cleft is very rare in the paleopathological literature. Van de Merwe *et al.* (2013) presented a case of superior sternal cleft or bifid sternum in an adult female from a 19<sup>th</sup> century Dutch psychiatric asylum cemetery in Bloemendaal, The Netherlands. The manubrium was not recovered and the sternum body had a superiorly bifid/cleft with a wide U-shaped morphology extending down to the fourth costal attachment.

Aside from isolated cases, Farkas *et al.* (2004) studied a huge number of skeletons (3,782 individuals) from the site of Bátmonostor-Pusztafalu in Hungary. The cemetery dates back to the 14<sup>th</sup>–15<sup>th</sup> century AD. Anomalies of the sternum were detected in 40 individuals. Changes in the xiphoid process were detected in four cases, *synchondrosis sternii* was recorded in seven cases and *sternum bifidum* was observed in five cases. Several cases of *fenestration* and

*pectus carinatum* were also detected. Noteworthy Barnes (1994, 2012) wrote a book about developmental defects of the axial skeleton and dedicates an entire chapter of an atlas of developmental field anomalies to the sternum.

In the paleopathological literature only transversal defects of fusion are described, significantly lacking those of the sagittal axis. Perhaps the most similar case to the one described here are that of failed union of the mesosternum originating from an adult male from Byzantine Petras, Crete (Barnes 2012), and the vertical fissure of the body of the sternum from a young girl from the Roman city of Ercolano, Naples (Capasso 2001).

The sternum from individual CR16.1 can be considered as congenitally anomalous, probably originated from the lack of midline fusion of ossification centers from sternebrae two, three and four. The processus xiphoideus is absent and maybe it had never developed. This variability may be the result of that lack of coordination between the incomplete cohesion of the lateral sternal bands and the appearance of the ossification centers. The age at death of the individual, between 17 and 21 years, is critical because the change in the sternum morphology occur between the childhood and young adulthood, but usually in this period the ossification of the centers is complete.

## CONCLUSION

The skeletal remains from grave CR16.1 show a non fusion in the caudal portion of the sternum. This represents a rare malformation, but no other skeletal abnormalities were found and no associated pathological conditions affecting other structures were detected. The reason for this incomplete fusion in the midline of the mesosternum is most certainly idiopathic and sometimes it requires a treatment in the first phase of the individual's life. Despite no clear health problems can be determined, the sternum body of this young adult should be already fused. Therefore, a link could be established between this skeletal thoracic anomaly and the overall fitness conditions.

## ACKNOWLEDGEMENTS

The authors would like to acknowledge the support from Generalitat de Catalunya (2014 SGR 1420).

## REFERENCES

- ACASTELLO E., MAJLUF F., GARRIDO P., BARBOSA L. M., PEREDO A., 2003: Sternal cleft: a surgical opportunity. *Journal of Pediatric Surgery* 38, 2: 178–183.
- ASHLEY G. T., 1956: The relationship between the pattern of ossification and the definitive shape of the mesosternum in man. *Journal of Anatomy* 90: 87–105.
- BABINSKI M. A., RAFAEL F. A., STEIL A. D., SOUSA-RODRIGUES C. F., SGROTT E. A., DE PAULA R. C., FERNANDES R. M. P., 2012: High prevalence of sternal foramen: quantitative, anatomical analysis and its clinical implications in acupuncture practice. *International Journal of Morphology* 30, 3: 1042–1049.
- BARNES E., 1994: *Developmental defects of the axial skeleton in paleopathology*. University press of Colorado, Colorado.
- BARNES E., 2012: *Atlas of developmental field anomalies of the human skeleton: a paleopathology perspective*. John Wiley & Sons, Inc., Hoboken, New Jersey.
- BONGIOVANNI R., SPRADLEY M. K., 2012: Estimating sex of the human skeleton based on metrics of the sternum. *Forensic Science International* 219, 1–3: 290.e1–290.e7.
- BROTHWELL D. R., 1981: *Digging up bones*. 5<sup>th</sup> ed. Oxford University press, Oxford.
- BUIKSTRA J. E., UBELAKER D. H., 1994: *Standards: for data collection from human skeletal remains*. Arkansas archeological survey research series No. 44, Arkansas.
- CANEPA G., STELLA G., 2002: *Trattato di ortopedia pediatrica. Clinica-terapia medica e tecniche chirurgiche*. Volume 1. Piccin, Padova.
- CAPASSO L., 2001: *I fuggiaschi di Ercolano: paleobiologia delle vittime dell'eruzione vesuviana del 79 d.C.* "L'Erma" di Bretschneider, Roma.
- COOPER P. D., STEWART J. H., MCCORMICK W. F., 1988: Development and morphology of the sternal foramen. *The American Journal of Forensic Medicine and Pathology* 9, 4: 342–347.
- CRETOT M., 1978: *L'arcade dentaire humaine morphologie*. Julien Prélat, Paris.
- DIAZ DE VILLABONA N., 2010. *Bahia de Alcúdia, Mallorca: un crisol genético en el Mediterráneo*. PhD thesis, Universitat Autònoma de Barcelona. <http://www.tdx.cat/handle/10803/3712>
- FARKAS G. L., JÓZSA L., PAJA L., 2004: Developmental anomalies and other pathological lesions of the sternum in a medieval osteological sample. *Acta Biologica Szegediensis* 48, 1–4: 39–42.
- FEREMBACH D., SCHWIDETZKY I., STLOUKAL M., 1979 : Recommendations pour déterminer l'âge et le sexe sur le squelette. *Bulletin et Mémoires de la Société d'Anthropologie de Paris* 6, 13: 7–45.
- FILY M. L., CRUBEZY E., LUDES B., ROUGE D., MIDANT-REYNES B., 2001: Sternal perforation and bifid ribs. *Bulletin et Mémoires de la Société d'Anthropologie de Paris* 13, 1–2. <http://bmsap.revues.org/5453>.
- FOKIN A. A., STEUERWALD N. M., AHRENS W. A., ALLEN K. E., 2009: Anatomical, histologic, and genetic characteristics of congenital chest wall deformities. *The Journal of Thoracic and Cardiovascular Surgery* 21: 44–57.
- GARCÍA SÍVOLI C., 2009: *Estudio diacrónico de los rasgos dentales en poblaciones del Mediterráneo occidental: Mallorca y Cataluña*. PhD thesis, Universitat Autònoma de Barcelona. <http://www.tdx.cat/handle/10803/3706>
- GROVES S., ROBERTS C., JOHNSTONE C., HALL R., DOBNEY K., 2003: A high status burial from Ripon Cathedral, North Yorkshire, England: differential diagnosis of a chest deformity. *International Journal of Osteoarchaeology* 13: 358–368.
- MATHES S. J., SEYFER A. E., MIRANDA E. P., 2006: Congenital anomalies of the chest wall. In: S. J. Mathes (Eds): *Plastic surgery*. 2<sup>nd</sup> ed. Pp. 1–81. Saunders Elsevier, Philadelphia.
- NUSS D., KELLY Jr. R. E., 2009: Congenital chest wall deformities. In: G. Holcomb, J. Murphy (Eds.): *Ashcraft's pediatric surgery*. 5<sup>th</sup> ed. Pp. 249–265. Saunders Elsevier, Philadelphia.
- ORFILA M., 2000: *El forum de Pollentia. Memòria de les campanyes d'excavacions realitzades entre els anys 1996 i 1999*. Ajuntament d'Alcúdia, Àrea de Patrimoni, Alcúdia.
- ORTEGA B., CHIMENOS E., MALGOSA A., 2003: Aproximación a la salud oral de los individuos tardo-romanos de Alcudia (Mallorca). In: M. P. Aluja, A. Malgosa, R. M. Nogués (Eds): *Antropología y biodiversidad*. Vol. I, Pp. 386–393. Bellaterra, Barcelona.
- RESTREPO C. S., MARTINEZ S., LEMOS D. F., WASHINGTON L., MCADAMS H. P., VARGAS D., LEMOS J. A., CARRILLO J. A., DIETHELM L., 2009: Imaging appearances of the sternum and sternoclavicular joints. *Radiographics* 29: 839–859.
- RIACH I. C. F., 1967: Ossification in the sternum as a means of assessing skeletal age. *Journal of Clinical Pathology* 20: 589–590.
- SCHEUER L., BLACK S., 2000: *Developmental juvenile osteology*. University Press, Cambridge.
- TÓTH G., BUDA B. L., 2001: Funnel chest (pectus excavatum) in 10–16<sup>th</sup> century fossil material. *International Journal of Paleopathology* 13: 63–66.
- TUNCER, M. C., ALUCLU, M. U., KARABULUT, O., ULKU, R., HATİPOĞLU, E. S., NAZAROĞLU, H. 2009. The demonstration of the inferior sternal cleft using three-dimensional reconstruction: a case report. *Romanian Journal of Morphology and Embryology*, 50, 3: 513–516.
- UBELAKER, D. H. 1989a. *Human Skeletal Remains*. 2<sup>nd</sup> ed. Taraxacum Press: Washington, D.C.
- UBELAKER, D. H. 1989b. The estimation of age at death from immature human bone. In M.Y. Iscan (Eds): *Age markers in the human skeleton*. Pp. 55–70. Charles C. Thomas, Springfield, Illinois.
- ZALEL Y., LIPITZ S., SORIANO D., ACHIRON R., 1999: The development of the fetal sternum: a cross-sectional

sonographic study. *Ultrasound Obstetrics & Gynecology* 13: 187–190.

VAN DE MERWE A. E., WESTON D.A., OOSTRA R. J., MAAT G. J. R., 2013: A review of the embryological development and associated developmental abnormalities of the sternum in the light of a rare palaeopathological case of sterna clefting. *Homo* 64: 129–141.

Elena Fiorin  
Assumpció Malgosa  
Unitat d'Antropologia Biològica  
Dpt. Biologia Animal,  
Biologia Vegetal i Ecologia  
Universitat Autònoma de Barcelona  
Spain  
E-mail: elenafiorin84@gmail.com  
E-mail: assumpcio.malgosa@uab.cat

Albert Isidro  
Hospital Universitari Sagrat Cor  
Barcelona  
Spain  
E-mail: aisidro.cot@gmail.com

Douglas H. Ubelaker  
Department of Anthropology  
National Museum of Natural History  
Smithsonian Institution  
Washington, D.C.  
United States  
E-mail: ubelaked@si.edu

