



OPEN ACCESS

CASE REPORT

Eculizumab in a child with atypical haemolytic uraemic syndrome and haemophagocytic lymphohistiocytosis triggered by cytomegalovirus infection

Gloria M Fraga-Rodriguez,¹ Sonia Brió-Sanagustin,¹ Eulalia Turón-Viñas,¹ Bradley P Dixon,² Eduardo Carreras-González¹

¹Hospital de la Santa Creu i Sant Pau, Universitat Autònoma de Barcelona, Barcelona, Catalunya, Spain
²Cincinnati Children's Hospital Medical Center, Cincinnati, Ohio, USA

Correspondence to

Dr Gloria M Fraga-Rodriguez, gfraga@santpau.cat

Accepted 12 April 2017

SUMMARY

We present the case of a 21-month-old girl with two rare and life-threatening conditions, atypical haemolytic uraemic syndrome (aHUS) and haemophagocytic lymphohistiocytosis (HLH), triggered by a cytomegalovirus (CMV) infection. Soon after admission, the girl became anuric and required continuous venovenous haemodiafiltration. Initial treatments included methylprednisolone, fibrinogen and plasma infusion (for HLH), plasmapheresis (for thrombotic microangiopathy), immunoglobulins (for inflammation), ganciclovir (for CMV infection) and the antibiotic cefotaxime. On day 5, eculizumab (600 mg) was given for aHUS, with rapid improvement in haematological and nephrological parameters. Despite a subsequent isolated episode of right heart thrombosis that resolved with heparin treatment, the patient showed a favourable response to eculizumab (300 mg/15 days), with improved renal function, normal haematological values, and no treatment complications. In conclusion, eculizumab effectively treated aHUS in this case despite a comorbid immunological disease.

BACKGROUND

Atypical haemolytic uraemic syndrome (aHUS) accounts for 5%–10% of paediatric cases of HUS^{1,2} and around 60% of patients with aHUS have an identified complement abnormality.³ In aHUS, uncontrolled complement activation causes thrombotic microangiopathy (TMA) which leads to multiorgan damage with significant morbidity and mortality.² Patients typically present with thrombocytopenia, Coombs negative microangiopathic haemolytic anaemia (MAHA) and acute renal failure.^{2,4} aHUS sometimes presents following an event causing complement amplification in combination with a genetic complement abnormality. Such events can be a common infection or, for example, malignancy, organ transplant or various drugs.^{2,4}

Haemophagocytic lymphohistiocytosis (HLH) is a potentially life-threatening disorder characterised by overwhelming immune activation and inflammation.⁵ Patients with HLH typically present with high-grade fever, progressive cytopenias, liver dysfunction and coagulopathy.⁶ HLH and aHUS are both rare conditions with distinct diagnostic

criteria,^{2,4,5} their coexistence only reported previously in two cases.^{7,8}

Eculizumab, a humanised anti-C5 monoclonal antibody, blocks the terminal complement pathway and is approved in many countries to treat aHUS. In prospective clinical trials, eculizumab inhibited TMA progression and prevented, or even reversed, organ damage.^{9,10} Rapid initiation of eculizumab treatment is beneficial as treatment delay can impair recovery of renal function.^{9,10} To our knowledge, we present the first published case of comorbid aHUS and HLH in which aHUS was treated with eculizumab. The case also reviews the diagnostic pathway to reach each individual diagnosis.

CASE PRESENTATION

A previously healthy 21-month-old girl presented with a 12-day history of fever and mild respiratory symptoms. Following presentation, her general condition worsened, with prostration, slight pallor of the skin and mucosa, and punctiform petechiae on the lower extremities. Apart from a slight hepatomegaly, no organomegaly was observed.

INVESTIGATIONS

Initial investigations for influenza antigen and adenovirus in nasopharyngeal mucus were negative. Blood and urine cultures were negative, and chest X-ray was normal.

Blood tests revealed subnormal levels of haemoglobin (8.7 g/dL), haematocrit (28%), red blood cell (RBC) count ($3.2 \times 10^{12}/L$; normal range $3.9\text{--}5.2 \times 10^{12}/L$), platelet count ($139 \times 10^9/L$, decreasing to $98 \times 10^9/L$; normal range $150\text{--}450 \times 10^9/L$) and haptoglobin (3.2 g/L, decreasing to <0.06 g/L; normal range 0.3–2.0 g/L). Schistocytes were present, the direct Coombs test was negative, and lactate dehydrogenase (LDH) was elevated (3600 U/L; normal range 125–243 U/L). Creatinine was raised (4.5 mg/dL; normal range 0.17–0.35 mg/dL) and estimated glomerular filtration rate was $7 \text{ mL/min/1.73 m}^2$ (normal $90 \text{ mL/min/1.73 m}^2$). Urine biochemistry showed microhaematuria and proteinuria (100 mg/dL). The patient became anuric with severe proteinuria (1200 mg/mmol creatinine, normal range up to 22 mg/mmol) within the first few hours of hospitalisation,



CrossMark

To cite: Fraga-Rodriguez GM, Brió-Sanagustin S, Turón-Viñas E, et al. *BMJ Case Rep* Published Online First: [please include Day Month Year]. doi:10.1136/bcr-2016-219065

indicating TMA and organ damage. Serum homocysteine ($3.15 \mu\text{mol/L}$; normal range $<14 \mu\text{mol/L}$) and methylmalonic acid ($<0.05 \mu\text{mol/L}$; normal range $<0.5 \mu\text{mol/L}$) levels were low.

Abdominal ultrasound revealed nephromegaly, with increased renal cortical echogenicity and normal arterial and venous flow in both kidneys; an echocardiogram was normal. Antinuclear antibodies were detected at a titre of 1/80 (speckled; normal limit $<1:40$); antimitochondrial antibodies, antigastric-mucosa antibodies, antismooth-muscle antibodies were all negative. Lymphocyte ($4.07 \times 10^3/\mu\text{L}$; normal range $2.9\text{--}5.1 \times 10^3/\mu\text{L}$) and natural killer cell ($115 \times 10^6/\text{L}$) counts were normal.

Laboratory results revealed high ferritin ($4292 \mu\text{g/L}$; normal range $12\text{--}156 \mu\text{g/L}$) and triglyceride (2.5mmol/L ; maximum 8.14mmol/L (normal limit $<1.65 \text{mmol/L}$)) levels, and elevated D-dimer ($5443 \mu\text{g/L}$; normal limit $<500 \mu\text{g/L}$). Fibrinogen levels dropped from 3.9g/L to 0.76g/L (normal range $1.5\text{--}4 \text{g/L}$) leading to suspicion of haemophagocytic syndrome.

DIFFERENTIAL DIAGNOSIS

When a child, without prior relevant medical history, presents with the classical features of TMA and renal failure, the most common cause would be Shiga toxin-producing *Escherichia coli* (STEC)-HUS. However, the rarer atypical form of HUS and thrombotic thrombocytopenic purpura (TTP) should also be considered.

In our patient, tests for classic, enterotoxigenic, enterohaemorrhagic and enteroinvasive *E. coli* were negative. Although initial ADAMTS13 activity was borderline normal ($\approx 10\%$), TTP was subsequently ruled out as ADAMTS13 activity increased to 43% and then 108% at most recent follow-up, with no inhibitors.

A differential diagnosis of either STEC-HUS, aHUS or TTP is important at an early stage due to different management strategies for optimal outcome. Immunological tests demonstrated functional haemolytic activity ($\text{CH}_{50} 66.9\%$), low C3 (58.8mg/dL , normal range $85\text{--}193$) and normal C4 (19.0mg/dL). Levels of complement factor (CF) H and CFI in plasma, and membrane cofactor protein (MCP) in peripheral blood lymphocytes, were normal. No anti-CFH antibodies were detected, and the CFH functional assay was negative. Low levels of homocysteine and methylmalonic acid excluded cobalamin C deficiency from the diagnosis.

A diagnosis of aHUS was made, based on normal ADAMTS13 activity, no STEC, low homocysteine levels, low haptoglobin levels, elevated LDH, acute renal failure, the presence of thrombocytopenia, anaemia and schistocytes.

The presence of fever, hypofibrinogenaemia, hyperferritinaemia, hypertriglyceridaemia and bicytopenia also suggested haemophagocytic syndrome. Rapid diagnosis and prompt initiation of treatment is essential for the survival of these patients. A diagnosis of HLH was made following the detection of increased soluble interleukin (IL) 2 receptor levels (4924U/mL), hypercellular bone marrow with polymorphic haematopoiesis and granulopoietic hyperplasia, and macrophages with haemophagocytosis. Six of the eight criteria for a diagnosis of HLH established by the Histiocyte Society were met (at least 5 have to be met).⁵

TREATMENT

Fever and mild respiratory symptoms were treated with amoxicillin prior to presentation.

Initial treatment comprised continuous venovenous haemodiafiltration (CVVHDF), RBC transfusion and empirical antibiotic

coverage (cefotaxime). Cytomegalovirus (CMV) infection was detected by PCR and analysis of IgG (97.70AU/mL) and positive IgM, and successfully treated with ganciclovir (5mg/kg/day). Ganciclovir was discontinued after 21 days and negative PCR results for CMV.

Initial TMA management involved two sessions of plasmapheresis, while for HLH management, four doses of fibrinogen were given with plasma infusion to address the hypofibrinogenaemia, while a single dose of immunoglobulins (1g/kg), and daily methylprednisolone (2mg/kg) were administered to reduce inflammation.

Following confirmation of aHUS, eculizumab (600mg) was initiated on the 5th day postadmission. The patient improved substantially, with haematologic normalisation and clear nephrological improvement (figure 1). Four days later, the patient was haemodynamically stable with no neurological, respiratory or gastrointestinal symptoms. Renal replacement therapy (CVVHDF for 10 days and two haemodialysis sessions) was given for a total of 15 days postadmission.

Twenty-four hours later, however, she presented with right heart thrombosis (figure 2A) with ventricular and supraventricular extrasystole. Platelets were $63 \times 10^9/\text{L}$, and D-dimer was $45446 \mu\text{g/L}$. A two-way right femoral catheter was inserted, and clinical and sonographic progression with intravenous heparin treatment were highly satisfactory (figure 2B). There was no family history of thrombotic events, and thrombosis testing revealed no abnormalities. The patient received corticosteroids for 8 weeks, which were tapered until discontinuation. Hypertension was managed with amlodipine, which was subsequently discontinued.

OUTCOME AND FOLLOW-UP

While genetic screening for complement mutations does not impact on immediate patient management, it does inform for long-term treatment decisions. A complete genetic workup revealed no genetic defects in CFH, CFHR1–5, C3, CFI, MCP, complement factor B (CFB), thrombomodulin, diacylglycerol kinase epsilon, complement factor properdin or ADAMTS13 but a heterozygous risk haplotype was found in CFH (CFH-H3).

At most recent follow-up (June 2016) the patient remains healthy, without further complications, and with stable haematological and renal parameters. The decision to discontinue eculizumab treatment, after more than 2 years, was based on the improved clinical status of the patient and the absence of identified pathogenic variants.

DISCUSSION

Our patient's history suggests that both aHUS and HLH were triggered by CMV infection. Infectious events, particularly in the upper respiratory tract, are responsible for new TMA manifestations in 50%–80% of patients with aHUS,^{11–13} while infection— notably herpesvirus infection—is one of the two most common settings for secondary HLH in children.^{5,14} aHUS was suggested in our patient by the combination of MAHA (negative Coombs test, schistocytes, increased LDH, low haptoglobin), thrombocytopenia and acute oligoanuric renal insufficiency. Initial ADAMTS13 measurement ($\approx 10\%$) may suggest TTP, which, unlike aHUS, is typically associated with ADAMTS13 deficiency, however, the subsequent normalisation of ADAMTS13 ruled out TTP.^{15,16} aHUS is a rare disease that is complex to diagnose because of its heterogeneity. aHUS is a complement-mediated disease, yet 30%–50% of patients are diagnosed without an identified mutation, conversely incomplete penetrance of

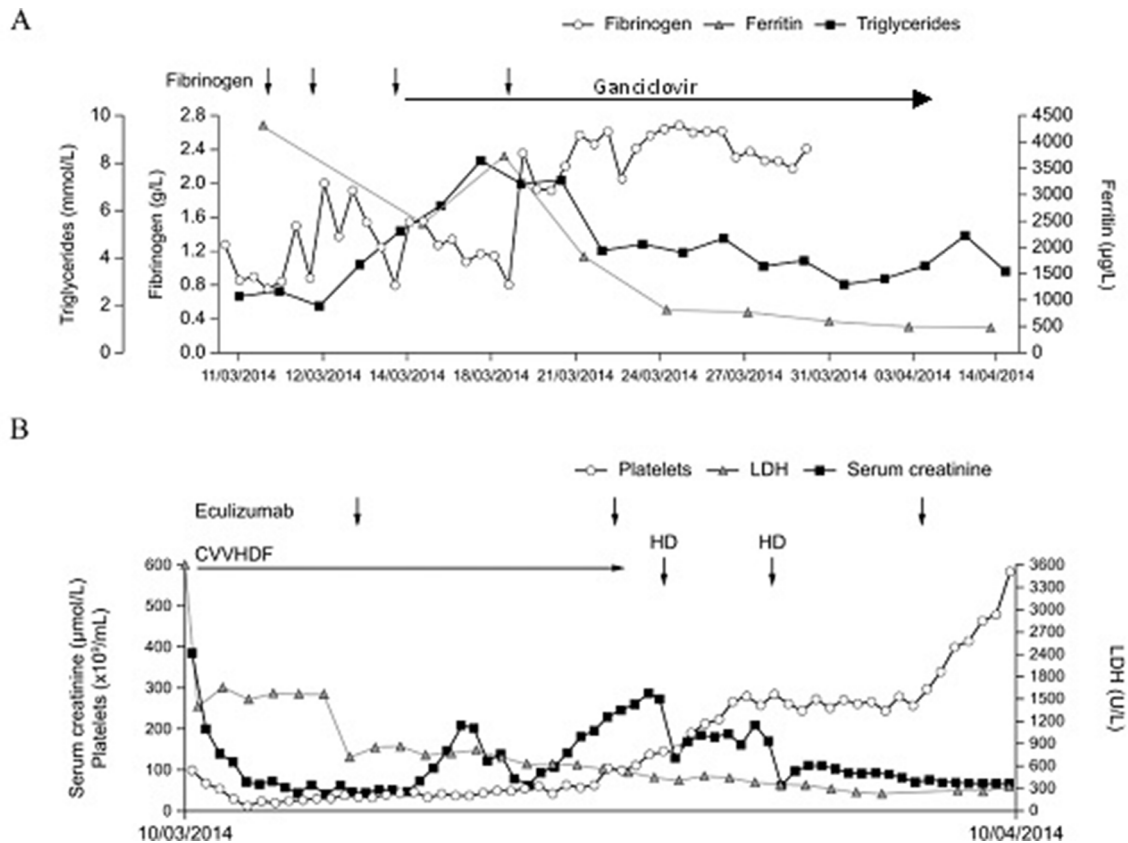


Figure 1 Levels of (A) fibrinogen, ferritin and triglycerides, and (B) platelets, lactate dehydrogenase (LDH) and serum creatinine over the initial treatment period. CVVHDF, continuous venovenous haemodiafiltration.

complement gene mutations is 48%–64%.¹² Similarly, normal C3 levels can be present in up to 70% of patients with aHUS as complement consumption occurs on the endothelial surface and not necessarily in plasma, making C3 an unreliable diagnostic criterion for aHUS.³ However, low C3 and normal C4 levels can be indicative of alternative pathway complement consumption and lead to the clinical suspicion of complement-activated diseases like aHUS, even in patients with no identified complement abnormality. The number of complement mutations known to be associated with aHUS is increasing, indicating some of these patients may have an unknown mutation.¹⁴ Importantly, in case studies and prospective clinical trials, patients respond to eculizumab irrespective of mutation status.^{3 10}

Diagnosing HLH can be difficult due to its rarity, variable presentation and the time needed to perform diagnostic tests for patients who often present in a critical condition. In our patient, six of the eight criteria for diagnosis of HLH were met based on the 2013 update of the Histiocyte Society 2004 guidelines.^{5 6} These include presence of haemophagocytosis in bone marrow (in the absence of malignancy or other disorders), hyperferritinaemia (>500 µg/L), fever, cytopenia in up to two lineages, hypertriglyceridaemia and hypofibrinogenaemia, and soluble IL-2 receptor >2400 U/mL.

With the exception of Epstein-Barr virus-driven HLH, there are no specific management guidelines for infection-associated forms of HLH. Management of infection alone is often insufficient for clinical improvement. Some form of immunosuppressive/immunomodulatory therapy might be necessary to manage the hyperinflammatory state.¹⁴ We elected to manage with fibrinogen and administration of plasma given the hypofibrinogenaemia, as well as plasma exchange while

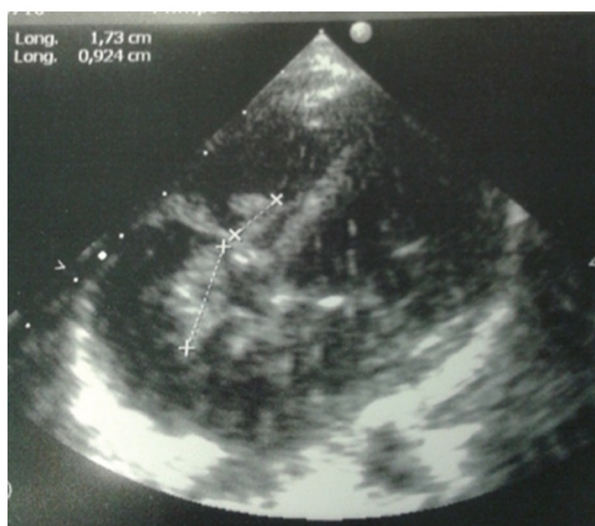HLH investigations were completed. Immunoglobulins at 1 g/kg and methylprednisolone at 2 mg/kg/day were administered to reduce inflammation.

The cause of the serious cardiac thrombosis, which occurred 10 days after admission, is unclear. Numerous interventions had been made prior to the thrombosis including administration of fibrinogen. aHUS may also be associated with the development of thromboses due to endothelial damage.² A single dose of eculizumab had been administered prior to the thrombosis; clinical trials of eculizumab have not reported an increased risk of clot formation.^{10 17}

Only one prior paediatric case of comorbid aHUS and HLH has been described—an 8-year-old boy presenting with low C3 which was managed with plasma exchange, fresh frozen plasma, haemodialysis, erythrocyte transfusion and low-dose oral steroids.⁸ No information on ADAMTS13 levels or genetic/functional analysis of complement regulatory proteins was reported, and the follow-up was only 45 days. An earlier paper described an 18-year-old girl with TMA (kidney biopsy) and haemophagocytic syndrome that were probably secondary to infection, although no causal agent was identified.⁷ Again, no ADAMTS13 levels or genetic/functional complement analysis were described, although the patient did have C3 hypocomplementaemia, suggestive of complement upregulation. Treatment with RBC transfusion, methylprednisolone and immunoglobulins was associated with no further disease manifestations over more than 3 years of follow-up.⁷ Neither of these cases was treated with eculizumab.

Our patient remained on eculizumab until June 2016 as the initial presentation was severe and the risk of further TMA manifestations was deemed too great to attempt discontinuation.

A



B

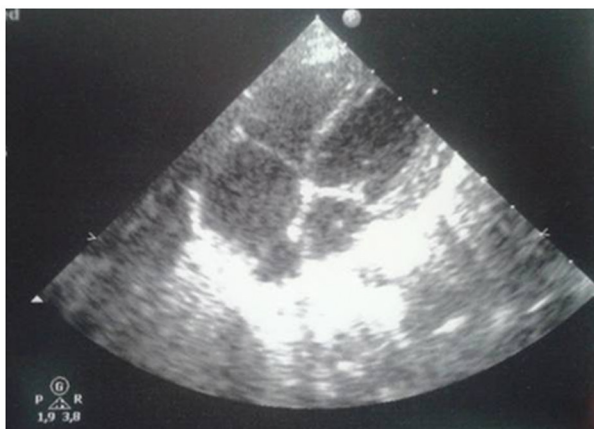

Figure 2 Echocardiogram showing (A) cardiac thrombosis (hyperdense image (30 mm × 4 mm) with tricuspid valve attached to both the atrial and ventricular faces) and (B) resolution after heparin treatment.

When evaluating eculizumab discontinuation we considered the clinical status of the patient and their individual risk benefit profile (including genetic analysis). The topic of eculizumab discontinuation is important yet without consensus. A recent study stated that it is not yet clear whether patients with or without identified genetic mutations are at higher risk of new TMA manifestations when eculizumab is discontinued.¹⁸ However, another suggests eculizumab discontinuation may be safer in patients with no documented complement gene variants after 6–12 months of treatment.¹⁹ Recommendations on treatment discontinuation may become clearer as this is tested in prospective studies and as evidence accumulates in the literature. At current evidence level the decision of length of eculizumab treatment is taken on a case-by-case basis. The decision on treatment strategy should consider the patient's unique clinical situation, age, TMA and family history, as well as recognition of the complex and unpredictable nature of aHUS. If discontinuation of eculizumab is to be considered, the patient must: have been treated for a sufficiently long period to ensure maximal organ function recovery; be monitored closely for signs and/or symptoms of TMA; and have

immediate access to eculizumab so treatment can be restarted at the first signs and/or symptoms of TMA.

In conclusion, we report a rapid and favourable response to aHUS with eculizumab treatment in a patient with comorbid aHUS and HLH. Eculizumab was well tolerated and treatment was subsequently discontinued after more than 2 years of treatment. The patient has suffered no further complications so far, but is closely monitored.

Learning points

- ▶ Eculizumab treatment led to an improvement in kidney function despite the presence of a comorbid immunological condition.
- ▶ Favourable renal recovery demonstrates the importance of rapid diagnosis and treatment of patients with atypical haemolytic uraemic syndrome (aHUS).
- ▶ Infections such as cytomegalovirus may unmask aHUS by activating the alternative complement pathway even in patients without an identified complement abnormality.

Acknowledgements The authors thank Matthew deSchoolmeester, PhD, of Bioscript Medical Ltd for medical writing support.

Contributors GMF-R and BPD wrote the manuscript. GMF-R managed the patient (nephrology) and prescribed eculizumab. EC-G, SB and ET managed the patient in the ICU and coordinated the different specialists involved in the case. All authors provided critical revision of content, and read and approved the final manuscript.

Funding Alexion Pharma GmbH.

Competing interests GMF-R has received lecture honoraria from Alexion Pharma GmbH. The other authors declare no competing financial interests.

Patient consent Obtained.

Provenance and peer review Not commissioned; externally peer reviewed.

Open Access This is an Open Access article distributed in accordance with the Creative Commons Attribution Non Commercial (CC BY-NC 4.0) license, which permits others to distribute, remix, adapt, build upon this work non-commercially, and license their derivative works on different terms, provided the original work is properly cited and the use is non-commercial. See: <http://creativecommons.org/licenses/by-nc/4.0/>

© BMJ Publishing Group Ltd (unless otherwise stated in the text of the article) 2017. All rights reserved. No commercial use is permitted unless otherwise expressly granted.

REFERENCES

- 1 Ariceta G, Besbas N, Johnson S, *et al*. Guideline for the investigation and initial therapy of diarrhea-negative hemolytic uremic syndrome. *Pediatr Nephrol* 2009;24:687–96.
- 2 Noris M, Remuzzi G. Atypical hemolytic-uremic syndrome. *N Engl J Med* 2009;361:1676–87.
- 3 Fremeaux-Bacchi V, Fakhouri F, Garnier A, *et al*. Genetics and outcome of atypical hemolytic uremic syndrome: a nationwide french series comparing children and adults. *Clin J Am Soc Nephrol* 2013;8:554–62.
- 4 Loirat C, Frémeaux-Bacchi V. Atypical hemolytic uremic syndrome. *Orphanet J Rare Dis* 2011;6:60.
- 5 Chandrakasan S, Filipovich AH. Hemophagocytic lymphohistiocytosis: advances in pathophysiology, diagnosis, and treatment. *J Pediatr* 2013;163:1253–9.
- 6 Henter JI, Horne A, Aricó M, *et al*. HLH-2004: diagnostic and therapeutic guidelines for hemophagocytic lymphohistiocytosis. *Pediatr Blood Cancer* 2007;48:124–31.
- 7 Chiang WC, Wu MS, Tsai CC, *et al*. Thrombotic microangiopathy in hemophagocytic syndrome: a case report. *J Formos Med Assoc* 2002;101:362–7.
- 8 Akyüz SG, Kara A, Çaltık Yılmaz A, *et al*. An unusual patient with atypical haemolytic uraemic syndrome who developed haemophagocytic lymphohistiocytosis. *Turk Nephrol Dial Transplant* 2013;22:224–8.
- 9 Zuber J, Fakhouri F, Roumenina LT, *et al*. French Study Group for aHUS/C3G. Use of eculizumab for atypical haemolytic uraemic syndrome and C3 glomerulopathies. *Nat Rev Nephrol* 2012;8:643–57.
- 10 Legendre CM, Licht C, Muus P, *et al*. Terminal complement inhibitor eculizumab in atypical hemolytic-uremic syndrome. *N Engl J Med* 2013;368:2169–81.
- 11 Sellier-Leclerc AL, Fremeaux-Bacchi V, Dragon-Durey MA, *et al*. Differential impact of complement mutations on clinical characteristics in atypical hemolytic uremic syndrome. *J Am Soc Nephrol* 2007;18:2392–400.

- 12 Noris M, Caprioli J, Bresin E, *et al.* Relative role of genetic complement abnormalities in sporadic and familial aHUS and their impact on clinical phenotype. *Clin J Am Soc Nephrol* 2010;5:1844–59.
- 13 Loirat C, Noris M, Fremeaux-Bacchi V. Complement and the atypical hemolytic uremic syndrome in children. *Pediatr Nephrol* 2008;23:1957–72.
- 14 Roupael NG, Talati NJ, Vaughan C, *et al.* Infections associated with haemophagocytic syndrome. *Lancet Infect Dis* 2007;7:814–22.
- 15 Furlan M, Robles R, Galbusera M, *et al.* von Willebrand factor-cleaving protease in thrombotic thrombocytopenic Purpura and the hemolytic-uremic syndrome. *N Engl J Med* 1998;339:1578–84.
- 16 Tsai HM, Lian EC. Antibodies to von Willebrand factor-cleaving protease in acute thrombotic thrombocytopenic Purpura. *N Engl J Med* 1998;339:1585–94.
- 17 Licht C, Greenbaum LA, Muus P, *et al.* Efficacy and safety of eculizumab in atypical hemolytic uremic syndrome from 2-year extensions of phase 2 studies. *Kidney Int* 2015;87:1061–73.
- 18 Macia M, de Alvaro Moreno F, Dutt T, *et al.* Current evidence on the discontinuation of eculizumab in patients with atypical haemolytic uraemic syndrome. *CKJ* 2016:1–10.
- 19 Fakhouri F, Fila M, Provôt F, *et al.* Pathogenic variants in Complement genes and risk of atypical hemolytic uremic syndrome relapse after Eculizumab Discontinuation. *Clin J Am Soc Nephrol* 2017;12:50–9.

Copyright 2017 BMJ Publishing Group. All rights reserved. For permission to reuse any of this content visit <http://group.bmj.com/group/rights-licensing/permissions>.
BMJ Case Report Fellows may re-use this article for personal use and teaching without any further permission.

Become a Fellow of BMJ Case Reports today and you can:

- ▶ Submit as many cases as you like
- ▶ Enjoy fast sympathetic peer review and rapid publication of accepted articles
- ▶ Access all the published articles
- ▶ Re-use any of the published material for personal use and teaching without further permission

For information on Institutional Fellowships contact consortiasales@bmjgroup.com

Visit casereports.bmj.com for more articles like this and to become a Fellow