



Case Report

High-dose benznidazole in a 62-year-old Bolivian kidney transplant recipient with Chagas central nervous system involvement



M. Montero^{a,*}, M. Mir^b, E. Sulleiro^c, J.L. Avalos Esquivel^b, E. García López^a,
D. Molina-Morant^d, I. López Montesinos^a, L. Sorlí^a, G. Veliz Espinosa^b,
E. Monteis Oliva^d, M. Crespo^b, I. Monge^e, J.P. Horcajada^a, S. Grau^e, J. Pascual^b

^a Infectious Diseases Service, Hospital del Mar, Infectious Pathology and Antimicrobials Research Group (IPAR), Institut Hospital del Mar d'Investigacions Mèdiques (IMIM), Universitat Autònoma de Barcelona (UAB), CEXS-Universitat Pompeu Fabra, Barcelona, Spain

^b Department of Nephrology, Hospital del Mar, Institut Hospital del Mar d'Investigacions Mèdiques (IMIM), Universitat Autònoma de Barcelona (UAB), CEXS-Universitat Pompeu Fabra, Barcelona, Spain

^c Microbiology Department, H. Universitari Vall d'Hebron. PROSICS Barcelona (International Health Program of the Catalan Health Institute), Universitat Autònoma de Barcelona, Barcelona, Spain

^d Tropical Medicine Unit, Infectious Diseases Department, PROSICS Barcelona (International Health Program of the Catalan Health Institute), Hospital Universitari Vall d'Hebron, Universitat Autònoma de Barcelona, Barcelona, Spain

^e Department of Pharmacy, Hospital del Mar, Infectious Pathology and Antimicrobials Research Group (IPAR), Institut Hospital del Mar d'Investigacions Mèdiques (IMIM), Universitat Autònoma de Barcelona (UAB), CEXS-Universitat Pompeu Fabra, Barcelona, Spain

ARTICLE INFO

Article history:

Received 16 August 2018

Received in revised form 16 October 2018

Accepted 19 October 2018

Corresponding Editor: Eskild Petersen, Aarhus, Denmark

Keywords:

Chagas disease

Kidney transplant recipient

Chagoma

Benznidazole dose

Benznidazole PK/PD

ABSTRACT

There is little published data on benznidazole dosing, or levels in cerebrospinal fluid. In this report, we describe the clinical course of an immunosuppressed patient with Chagas central nervous system involvement. He was treated successfully with larger benznidazole doses than are recommended, in order to reach therapeutically effective concentrations in the brain.

© 2018 The Authors. Published by Elsevier Ltd on behalf of International Society for Infectious Diseases.

This is an open access article under the CC BY-NC-ND license (<http://creativecommons.org/licenses/by-nc-nd/4.0/>).

Introduction

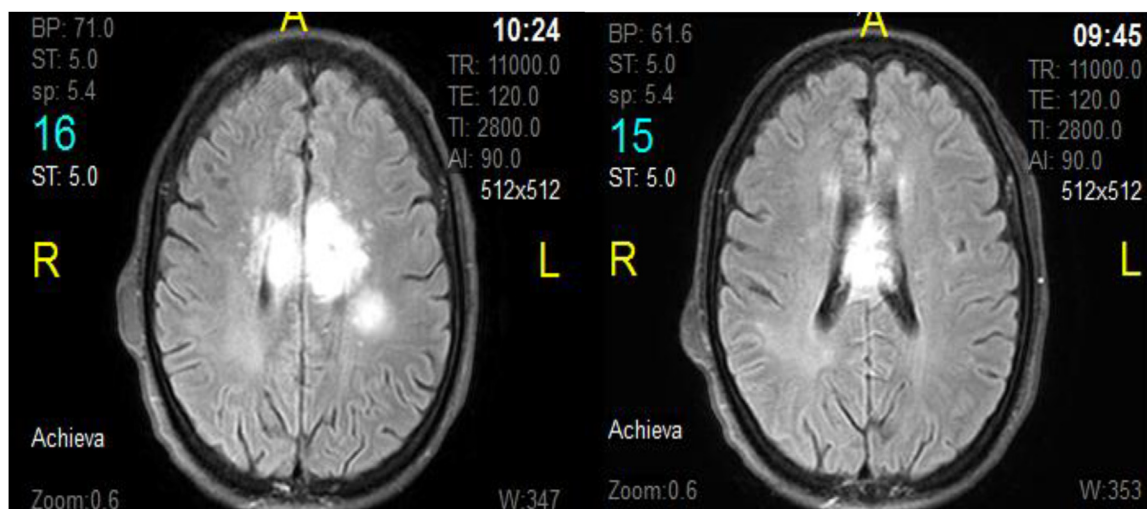
Currently, only two effective drugs are available for the treatment of Chagas disease: benznidazole and nifurtimox (World Health Organization, 2018; Pérez-Molina and Molina, 2017). Information on the pharmacokinetics of benznidazole is limited (Molina et al., 2017). Here, we present the case of a kidney transplant recipient with Chagas disease and central nervous system (CNS) involvement, whose poor clinical course required treatment with much higher doses of benznidazole than are recommended.

Case report

A 62-year-old man from Bolivia was admitted to hospital because of focal neurological deficits. The patient, who had been living in Spain for more than 10 years, had a medical history of chronic kidney disease on haemodialysis treatment starting in 2012. He underwent a kidney transplantation from a deceased donor in 2014, and was receiving long-term immunosuppression with prednisone 5 mg/24 h, tacrolimus at a dose to achieve trough levels of 6–8 ng/ml, and mycophenolic acid at 360 mg twice daily. In July 2016, he showed an increase in proteinuria and his graft was biopsied. The findings were consistent with chronic active antibody-mediated rejection, without HLA donor-specific antibodies. Therefore, steroid pulses at 10 mg/kg/day were administered for 5 days.

* Corresponding author at: Hospital del Mar, Passeig Marítim, 25–29, 08003 Barcelona, Spain.

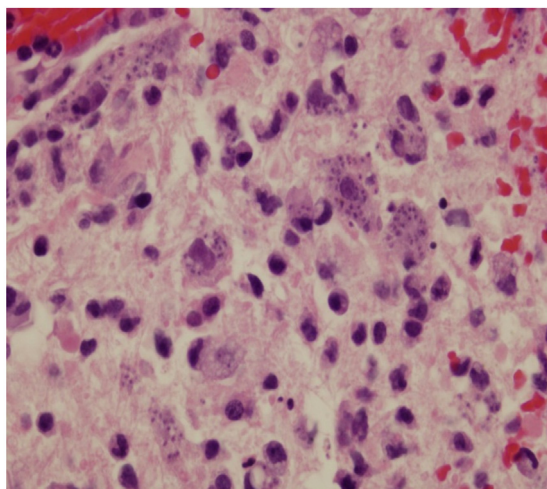
E-mail address: 95422@parcdesalutmar.cat (M. Montero).



Brain T1 MRI: focal lesion in corpus callosum with surrounding edema

Figure 1. Brain T1 Magnetic resonance imaging (MRI).

In January 2017, the patient was admitted because of difficulty moving his left arm, headache, and loss of balance for the previous 5 days. On initial examination, he showed left arm paresis and bradypsychia. There were no signs or symptoms of infection. Magnetic resonance imaging (MRI) of the brain showed a focal lesion in the corpus callosum surrounded by oedema and suggestive of lymphoma or glioblastoma (Figure 1); hence, high-dose corticosteroid therapy was prescribed. However, during the first week of admission the patient experienced clinical deterioration and a decrease in level of consciousness. A brain biopsy was performed, with findings of acute and chronic inflammation, abscess formation, and histiocytes containing intracytoplasmic microorganisms (Figure 2). Chemiluminescence immunoassays



Pathological study of brain biopsy specimen shows acute and chronic inflammation with abscessification and the presence of histiocytes containing intracytoplasmic microorganisms.

Figure 2. Pathological study of brain biopsy.

(CLIA) (Liaison XL Murex) (Malan et al., 2006) and immunochromatography for serological diagnosis of *Trypanosoma cruzi* were positive, as was the CLIA for *Toxoplasma gondii*.

Empirical treatment was started with benznidazole, sulfadiazine, and pyrimethamine. The initial benznidazole regimen was 100 mg/8 h, in accordance with the recommended dosage for the treatment of *T. cruzi* infection (Pierrotti et al., 2018). Real-time PCR (RT-PCR) (Molina et al., 2017; Piron et al., 2007) for the determination of *T. cruzi* DNA was positive in both blood and brain specimens, whereas RT-PCR for *T. gondii* was negative in brain; hence, sulfadiazine and pyrimethamine were discontinued. HIV testing was negative. The *T. cruzi* parasite load, estimated by the amplification cycle threshold (Ct), was higher in the brain biopsy than in the blood sample (12.35 vs. 30.43).

Approximately 2 weeks after receiving the appropriate antiparasitic treatment, the patient's clinical and neurological status worsened and he required orotracheal intubation. Electroencephalography ruled out non-convulsive status epilepticus, but was consistent with diffuse encephalopathy. A new brain MRI study detected an increase in the size of the Chagas lesion, although RT-PCR analyses for *T. cruzi* in blood samples were repeatedly negative. In view of this scenario, it was decided to progressively escalate the benznidazole dose up to 300 mg/12 h (15 mg/kg/day) at 24 days after starting this treatment, in order to reach therapeutically effective concentrations in the cerebrospinal fluid (CSF). This amount was well above the recommended dose of 5–10 mg/kg/day (Perin et al., 2017).

After 2 months of treatment with the new dosing regimen (at steady state), blood benznidazole samples were taken at different time points: 1 h, 3 h, 5 h, 8 h, and 12 h after administration. The measured benznidazole concentrations were 14.6 mg/l, 14.8 mg/l, 14.1 mg/l, 10.5 mg/l, and 8.8 mg/l, respectively, all values being above the in vitro trypanosomicidal range (3–6 mg/l) (Raafilaub, 1980). The plasma area under the concentration–time curve from 0 to 12 h (AUC_{0-12}) was 133.2 mg*h/l. In addition, CSF and blood peak (C_{max}) samples (3 h after the dose) were taken 2 weeks later. The concentrations achieved were 8.3 mg/l in CSF and 17.2 mg/l in blood, which yielded a CSF/blood C_{max} ratio of 48.3% (Figure 3). The patient's neurological status gradually improved and he was

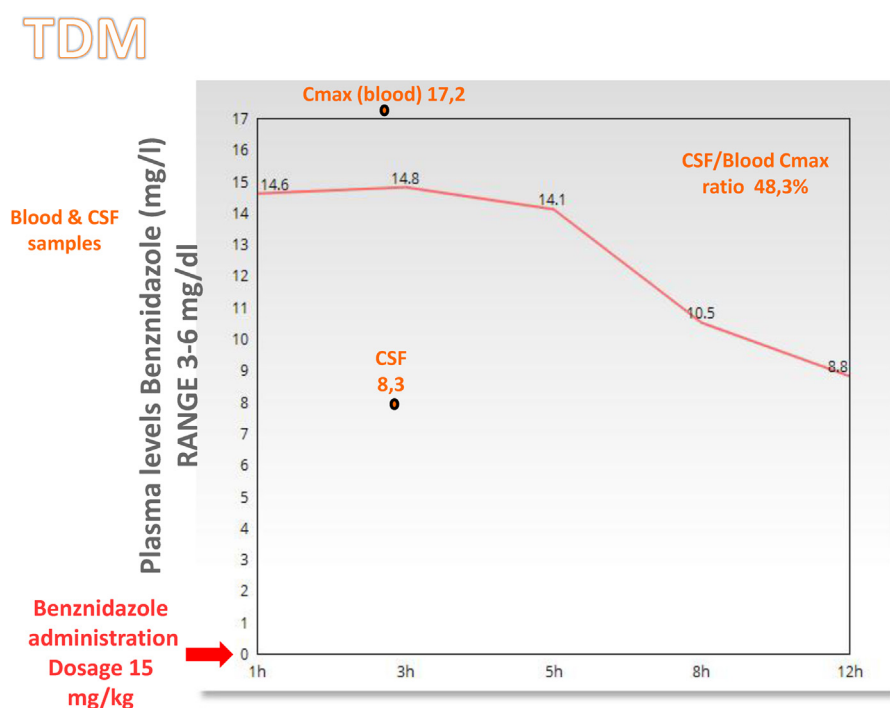


Figure 3. Plasma levels benznidazole (mg/dl).

weaned off orotracheal intubation. A new MRI showed a substantial decrease in the size of the brain mass and oedema. Four RT-PCR *T. cruzi* parasitemia analyses were conducted at different time points, with negative results; hence, after more than 3 months of benznidazole at 300 mg/12 h, the antiparasitic therapy was discontinued.

Two months after hospital discharge, the patient's clinical outcome was favourable with functional neurological rehabilitation. His situation was nearly back to normal except for the left arm paresis.

Discussion

Information on benznidazole penetration into the CNS is restricted to experimental animal studies, in which the reported mean brain/plasma benznidazole ratio varies considerably from 19% to 68.3%. Furthermore, the permeability of benznidazole through the blood–brain barrier of animals and humans may differ and this remains to be clarified (Perin et al., 2017; Workman et al., 1984). The relatively high concentration measured in the CSF of the patient described here suggests substantial passage of benznidazole through the blood–brain barrier.

The case patient showed good tolerability without the haematological and neurological side effects usually associated with the high doses of benznidazole he received. One study has investigated the relationship between benznidazole plasma concentrations and the development of toxicity (Pinazo et al., 2013). Patients received a dose of 5 mg/kg/day for 60 days, which is much lower than that administered to our patient. Although several cases of toxicity were observed, mainly changes in biochemical parameters and haematological manifestations of bone marrow depression (e.g., neutropenia, thrombocytopenia, anaemia, leukopenia), which resolved after treatment discontinuation, there were no correlations between plasma levels of the drug and these adverse events. It has been reported that plasma benznidazole concentrations below 20 mg/l do not seem to be related to the development of serious adverse events (Pinazo et al.,

2013). This is supported by the observations in our patient, whose highest benznidazole plasma concentration was 17.2 mg/dl.

In conclusion, *T. cruzi* reactivation may occur in immunosuppressed patients; hence, this eventuality should be considered in the differential diagnosis, mainly in patients from endemic areas. This was a challenging case because of the severe presentation and the dearth of available information on benznidazole dosage and the levels achieved in CSF. In conclusion, the experience described suggests that benznidazole can be safely administered in higher doses than those currently recommended for patients showing a torpid evolution, although close monitoring is advisable.

Funding

No specific funding was received for this study.

Ethical approval

All procedures were conducted with the full cooperation and adequate understanding of the patient, and have therefore been performed in accordance with the ethical standards of the Declaration of Helsinki.

Conflict of interest

The authors declare no conflicts of interest.

References

- Malan AK, Avelar E, Litwin SE, Hill HR, Litwin CM. Serological diagnosis of *Trypanosoma cruzi*: evaluation of three enzyme immunoassays and an indirect immunofluorescent assay. *J Med Microbiol* 2006;.
- Molina I, Salvador F, Sánchez-Montalvá A, Artaza MA, Moreno R, Perin L, et al. Pharmacokinetics of benznidazole in healthy volunteers and implications in future clinical trials. *Antimicrob Agents Chemother* 2017;61(March (4)).
- Pérez-Molina JA, Molina I. Chagas disease. *Lancet* 2017;391:82–94.
- Perin L, Da Silva RM, Da Silva Fonseca K, De Oliveira Cardoso JM, Mathias FAS, Reis LES, et al. Pharmacokinetics and tissue distribution of benznidazole after oral administration in mice. *Antimicrob Agents Chemother* 2017;61(4):1–30.

- Pierrotti LC, Carvalho NB, Amorin JP, Pascual J, Kotton CN, López-Vélez R. Chagas disease recommendations for solid-organ transplant recipients and donors. Transplantation [Internet] 2018;102(2S Suppl. 2):S1–7 Available from: <http://www.ncbi.nlm.nih.gov/pubmed/29381572><http://insights.ovid.com/cross-ref?an=00007890-201802002-00001>.
- Pinazo M-J, Guerrero L, Posada E, Rodríguez E, Soy D, Gascon J. Benznidazole-Related Adverse Drug Reactions and Their Relationship to Serum Drug Concentrations in Patients with Chronic Chagas Disease. Antimicrob Agents Chemother [Internet] 2013;57(1):390–5 Available from: <http://aac.asm.org/cgi/doi/10.1128/AAC.01401-12>.
- Piron M, Fisa R, Casamitjana N, López-Chejade P, Puig L, Vergés M, et al. Development of a real-time PCR assay for *Trypanosoma cruzi* detection in blood samples. Acta Trop 2007;103(3):195–200.
- Raaflaub J. Multiple-dose kinetics of the trypanosomicide benznidazole in man. Arzneimittelforschung [Internet] 1980;30(12):2192–4 [Cited 12 February 2018] Available from: <http://www.ncbi.nlm.nih.gov/pubmed/6783051>.
- Workman P, White RA, Walton MI, Owen LN, Twentyman PR. Preclinical pharmacokinetics of benznidazole. Br J Cancer 1984;.
- World Health Organization. Chagas disease (American tripanosomiasis). 2018 [Internet]. [Cited 20 January 2018]. Available from: <http://www.who.int/mediacentre/factsheets/fs340/en/>.