

Detection of SARS-CoV-2 in a cat owned by a COVID-19–affected patient in Spain

Joaquim Segalés^{a,b,1}, Mariona Puig^c, Jordi Rodon^a, Carlos Avila-Nieto^d, Jorge Carrillo^d, Guillermo Cantero^a, Maria Teresa Terrón^c, Silvia Cruz^c, Mariona Parera^d, Marc Noguera-Julian^{d,e}, Nuria Izquierdo-Useros^{d,f}, Víctor Guallar^{g,h}, Enric Vidal^a, Alfonso Valencia^{g,h}, Ignacio Blanco^f, Julià Blanco^{d,e,f}, Bonaventura Clotet^{d,e,f}, and Júlia Vergara-Alert^a

^aCentre de Recerca en Sanitat Animal, Institut de Recerca i Tecnologia Agroalimentàries, Campus Universitat Autònoma de Barcelona, 08193 Bellaterra, Spain; ^bDepartament de Sanitat i Anatomia Animals, Facultat de Veterinària, Universitat Autònoma de Barcelona, 08193 Bellaterra, Spain; ^cHospital Veterinari Sant Mori S.L., 08918 Badalona, Spain; ^dIrsiCaixa AIDS Research Institute, 08916 Badalona, Spain; ^eUniversity of Vic–Central University of Catalonia, 08500 Vic, Spain; ^fGermans Trias i Pujol Research Institute, 08916 Badalona, Spain; ^gBarcelona Supercomputing Center, 08034 Barcelona, Spain; and ^hCatalan Institution for Research and Advanced Studies, 08010 Barcelona, Spain

Edited by Tak W. Mak, University of Toronto, Toronto, ON, Canada, and approved August 22, 2020 (received for review May 27, 2020)

Severe acute respiratory syndrome coronavirus 2 (SARS-CoV-2), the etiological agent of COVID-19, is considered a zoonotic pathogen mainly transmitted human to human. Few reports indicate that pets may be exposed to the virus. The present report describes a cat suffering from severe respiratory distress and thrombocytopenia living with a family with several members affected by COVID-19. Clinical signs of the cat prompted humanitarian euthanasia and a detailed postmortem investigation to assess whether a COVID-19–like disease was causing the condition. Necropsy results showed the animal suffered from feline hypertrophic cardiomyopathy and severe pulmonary edema and thrombosis. SARS-CoV-2 RNA was only detected in nasal swab, nasal turbinates, and mesenteric lymph node, but no evidence of histopathological lesions compatible with a viral infection were detected. The cat seroconverted against SARS-CoV-2, further evidencing a productive infection in this animal. We conclude that the animal had a subclinical SARS-CoV-2 infection concomitant to an unrelated cardiomyopathy that led to euthanasia.

SARS-CoV-2 | COVID-19 | cat | transmission

The severe acute respiratory syndrome coronavirus 2 (SARS-CoV-2) is the etiological agent of COVID-19, declared as pandemic on March 11, 2020. Since its initial report at the end of 2019, the World Health Organization has reported more than 17.3 million human cases of COVID-19 causing over 674,000 deaths (accessed on August 1, 2020, <https://covid19.who.int/>). SARS-CoV-2 is believed to have originated in bats (1). However, the species barrier jump from bats to humans is considered unlikely, and the most probable hypothesis includes the existence of an intermediate host (2). Such a scenario points out the importance of animals in the emergence of COVID-19 in China, which further emphasizes the need of a One Health approach to tackle emerging diseases.

The role of animals in the context of COVID-19 is not only circumscribed to its origin and spillover events, but also at other key levels. First is the need to develop animal infection models for SARS-CoV-2 to accelerate the preclinical phase for developing vaccines and antiviral drugs against this novel agent. Several models for SARS-CoV-2 infection have been so far developed in animals, including Egyptian fruit bat, ferret, golden Syrian hamster, cat, humanized angiotensin-converting enzyme 2 (ACE2) transgenic mice (hACE2 mice), and some nonhuman primate species (3–8). Second, livestock and zoo animals as well as pets can be exposed to SARS-CoV-2 by contacts with COVID-19 patients or SARS-CoV-2 subclinically infected humans, resulting, eventually, in reverse zoonosis (human to animal transmission of a pathogen originated in animals). Such reverse zoonosis has been reported so far in at least four dogs (two in Hong Kong and two in the United States) (9), six cats (two in the

United States, and one each in Belgium, Hong Kong, France, and Germany), farmed minks (in at least four farms in The Netherlands) (10), and eight big felines in the Bronx Zoo in New York (five tigers and three African lions). Considering the number of infected people all over the world and the very few cases reported in different animal species, it is thought that animals play no or a negligible role in the epidemiology of SARS-CoV-2. Just very recently, there has been speculation on the possibility of a mink farm worker being exposed from an infected animal (10), which might be the first potential documented zoonosis event within the pandemic.

The present case report aims to describe evidence in Spain of SARS-CoV-2 infection in a 4-y-old domestic cat (European × Persian crossbreed). The owner of the animal died from COVID-19 (RT-PCR confirmed), and the animal was then taken by some relatives who were also diagnosed with a mild-to-moderate form of the disease, although SARS-CoV-2 infection was not confirmed at the laboratory. The animal (C1) had another cat mate (C2) at home that never showed any clinical sign.

Results

A relative of the deceased owner referred the cat (C1) to a veterinary hospital due to severe dyspnoea. The clinical examination of the pet was performed with personal protective

Significance

COVID-19 is the most devastating pandemic in recent history. As with many emerging infectious diseases, it is of zoonotic origin, meaning that animals played a major role in the initial transmission events. Despite SARS-CoV-2 being highly adapted to jump from human to human, several animal species are naturally susceptible to SARS-CoV-2, including pets such as cats. In the present report, a cat from a family with several relatives affected by COVID-19 developed severe respiratory clinical signs, leading to humanitarian euthanasia. Due to the suspicion of a potential COVID-19 infection in the cat, different antemortem and postmortem tests were assayed. The clinical condition was finally attributed to a feline hypertrophic cardiomyopathy, but the animal was also infected by SARS-CoV-2.

Author contributions: J.S. and J.V.-A. designed research; J.S., M. Puig, J.R., C.A.-N., J.C., G.C., M.T.T., S.C., M.N.-J., N.I.-U., E.V., and J.V.-A. performed research; C.A.-N., J.C., M. Parera, N.I.-U., V.G., A.V., and I.B. contributed new reagents/analytic tools; J.S., J.C., M. Parera, E.V., J.B., B.C., and J.V.-A. analyzed data; and J.S. wrote the paper.

The authors declare no competing interest.

This article is a PNAS Direct Submission.

This open access article is distributed under [Creative Commons Attribution-NonCommercial-NoDerivatives License 4.0 \(CC BY-NC-ND\)](https://creativecommons.org/licenses/by-nc-nd/4.0/).

¹To whom correspondence may be addressed. Email: joaquim.segalés@irta.cat.

First published September 18, 2020.

equipment (PPE) consisting of laboratory coat, face shield, mask, and a double pair of gloves. The animal was normothermic, and blood analyses revealed mild anemia and severe thrombocytopenia. Radiographically, a moderate bronchointerstitial pattern was observed bilaterally, but with more intensity in cranoventral areas and right side of the lung. The proBNP (Brain Natriuretic Peptide) test (IDEXX SNAP Feline proBNP Test) resulted positive; this test measures the B-type natriuretic peptide in blood, which is increased in response to excessive stretching of heart muscle cells. In consequence, cardiac insufficiency was suspected, and feline hypertrophic cardiomyopathy was subsequently diagnosed after echocardiography. Tests to detect antigen against feline immunodeficiency virus and feline leukemia virus resulted negative. The animal was kept at the veterinary hospital overnight, but the course worsened during the following afternoon, with lateral decubitus, shortness of breath, agonic violent respiratory efforts, and apnoea. The current owner, following the advice of the veterinary clinician, decided to humanely euthanize the cat.

Due to the nature of the case, the necropsy was performed at the biosafety level 3 facilities at the Centre de Recerca en Sanitat Animal (Institut de Recerca i Tecnologia Agroalimentàries [IRTA-CReSA]). For such necropsy, the PPE used consisted of double overall, triple glove pairs, FFP3 mask, and a belt-mounted powered air-purifying respirator. Externally, the animal had abundant fat resources, remnants of blood in the nostrils and mouth, and evidence of tearing at the medial eye edges. At necropsy, the most significant gross findings included moderate to severe hypertrophy of the left ventricular and interventricular wall with no cardiomegaly; lack of pulmonary collapse with marked redness of lung lobes; 15 mL of thoracic serosanguineous fluid; liver paleness; presence of blood in mouth, trachea, stomach, and intestines; and marked redness of the nasal turbinates. Samples from lung, trachea, turbinates, lymph nodes (mediastinal, submandibular, and mesenteric), tonsil, spleen, bone marrow, heart (ventricles and atria), skeletal muscle, pancreas, stomach, small and large intestines, adrenal gland, parotid gland, brain, and skin were taken and fixed by immersion in 10% buffered formalin for subsequent histopathological and immunohistochemistry studies. A second set of similar samples were taken within Dulbecco's modified Eagle's medium to perform SARS-CoV-2 real-time RT-PCR (11). In addition, nasal swabs, rectal swabs, and lung swabs were taken for virological analyses.

The most significant histological features consisted of severe pulmonary edema, congestion and hemorrhages, pulmonary thrombosis of capillaries and small/medium-sized blood vessels, nasal turbinate hemorrhages, interstitial fibrosis of left ventricular and interventricular walls, mild hepatic lipidosis, splenic hematopoiesis, mild membranoproliferative glomerulonephritis, and focal nodular adrenal hyperplasia.

In addition, blood, plasma, and rectal and nasal swabs from C2 were obtained, and plasma from C1 taken by the veterinarian the day before the euthanasia was also available. RT-qPCR and/or antibody detection was also performed in these extra samples.

Results of RT-qPCR to detect three SARS-CoV-2 genes are shown in Table 1. Viral genome was found in nasal swabs and turbinates as well as mesenteric lymph node of C1, although with high Ct values. The rest of the analyzed tissue results and C2 swabs were negative for the RT-qPCR methods. Immunohistochemistry to detect SARS-CoV-2 antigen in formalin-fixed, paraffin-embedded tissues also gave negative results.

The serum from both C1 and C2 yielded positive ELISA titers of $\geq 1:4,000$ for spike, S2, and receptor binding domain (RBD), but was negative for N protein (Fig. 1). Also, both animals had SARS-CoV-2 neutralizing antibodies (reciprocal dilution of the half maximal inhibitory concentration, IC_{50} , of 191 and 205 for C1 and C2, respectively).

Table 1. Real-time RT-PCR testing for SARS-CoV-2

Animal ID	Sample type	RT-qPCR detection		
		UpE	RdRp	N
C1	Nasal swab (left)	33.69	34.01	35.11
C1	Nasal swab (right)	36.25	37.14	39.02
C1	Nose frontal	34.80	37.78	39.44
C1	Nose medial	33.70	34.90	BDL
C1	Nose caudal	39.05	BDL	BDL
C1	Mesenteric lymph node	32.55	35.14	33.87

Results are expressed as Ct values of the RT-qPCR test (BDL, below the detection limit, Ct > 40). UpE, upstream E gene; RdRp, RNA dependent-RNA polymerase gene; N, nucleocapsid gene.

Viral genome could be partially obtained from the lymph node sample of C1 (Global Initiative on Sharing Avian Influenza Data, GISAID acc. EPI_ISL_482820) showing high identity (99.997%) with the genomic sequence obtained from the initial animal owner (GISAID acc. EPI_ISL_483059).

Discussion

Considering the clinical signs and both gross and microscopic lesions, it was concluded that the cat developed cardiorespiratory failure due to hypertrophic cardiomyopathy and secondary thromboembolism. The severity of the condition during the visit and the poor prognosis prompted the suggestion to euthanize the animal. The detection of SARS-CoV-2 RNA in several samples of C1, all of them with Ct values over 30 (low viral load), and presence of antibodies (neutralizing and nonneutralizing) in both C1 and C2, indicated both animals suffered from a productive viral infection, probably linked to the exposure of the cats to COVID-19-affected owners.

Experimental studies have demonstrated that cats are susceptible to SARS-CoV-2 infection and able to transmit it to direct contact mates (4, 7). Those authors did not find clinical signs in any of the inoculated cats. However, a certain degree of interstitial pneumonia, and loss of cilia and epithelial necrosis and inflammation in nasal turbinates and trachea, were observed in one of these studies (7). Importantly, virus antigen was found in epithelial cells of the nasal turbinates, necrotic debris in the tonsil, submucosal glands of the trachea, and enterocytes of the small intestine.

These experimental results, together with the few reports on SARS-CoV-2 detection in domestic cats and wild felids, indicate that felines are susceptible to infection by the novel coronavirus. Moreover, the presence of lesions in the respiratory tract and detection of viral antigen in both respiratory and digestive tracts are compatible with the mild to moderate clinical course with dyspnoea and diarrhea already seen in some of these naturally exposed felines. Since the cat referred to in the present report showed severe respiratory clinical signs and came from a COVID-19 environment, a serious concern regarding the cause of the signs was established. However, the clinical and pathological diagnostic efforts indicated that the animal had significant previous comorbidities such as feline hypertrophic cardiomyopathy (12) and severe thrombocytopenia. Therefore, the presence of pulmonary edema, congestion and hemorrhage, and pulmonary thrombosis and hydrothorax, all of them attributable to the preexisting condition, accounted for the severity of the clinical signs of the studied cat, and was the major reason to recommend euthanasia. In fact, no evidence of viral pneumonia was found, and no SARS-CoV-2 was retrieved from the lungs, findings that have been observed in experimentally infected cats (7). The detection of SARS-CoV-2 RNA in the mesenteric lymph node may be explained by the tropism of the virus to the digestive tract as well (7), since the virus seems to replicate in enterocytes, and

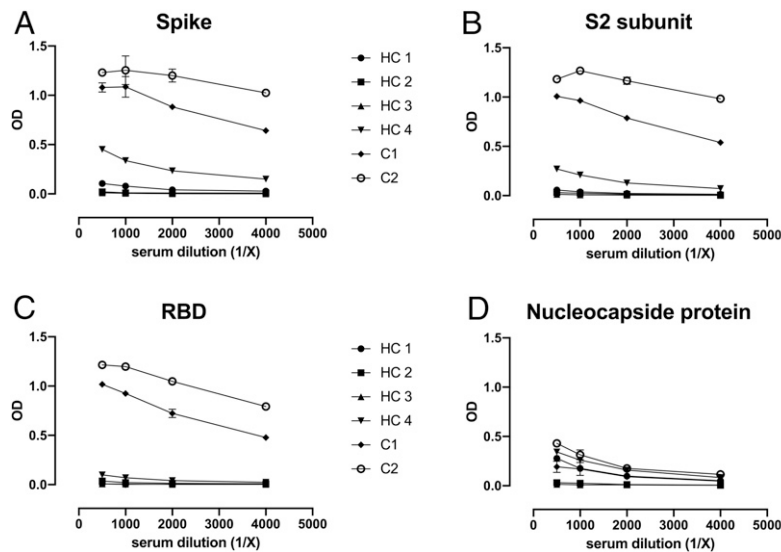


Fig. 1. Analysis of humoral response to SARS-CoV-2 in infected cats. The presence of anti-SARS-CoV-2 antibodies was evaluated in serum samples from two SARS-CoV-2-infected (C1 and C2) and four uninfected (HC1, HC2, HC3, and HC4) cats. Corrected OD after background subtraction and serum dilution factor is shown in y and x axes, respectively. Four SARS-CoV-2 antigens were evaluated: (A) whole spike, (B) spike S2-subunit, (C) spike RBD, and (D) nucleocapsid protein.

it would be feasible that remnants of virus or viral RNA may reach the mesenteric lymph node by draining the small intestine. In the cat of the present report, however, no lesions were observed in the digestive tract. Therefore, no evidence of clinical signs or lesions potentially caused by SARS-CoV-2 was attributed to C1. The second animal (C2) never showed any clinical sign compatible to SARS-CoV-2 infection, but this is not surprising, since such infection can remain completely asymptomatic (4).

To date, all described cases in cats have been related to COVID-19-affected owners or other people that came into

contact with them. For the wild felids in New York, it has been speculated that they were infected by an asymptomatic animal caretaker or, alternatively, by one in a preclinical phase of the COVID-19. This is also the situation of the present report's cats. Since the owner (who finally died because of the disease) and several relatives suffered from COVID-19, it is very likely that the pet was exposed, in a relatively continuous manner, to SARS-CoV-2. Although the exact moment of exposure or infection was not possible to determine based on the reconstruction of the chronological events around the present case (Fig. 2),

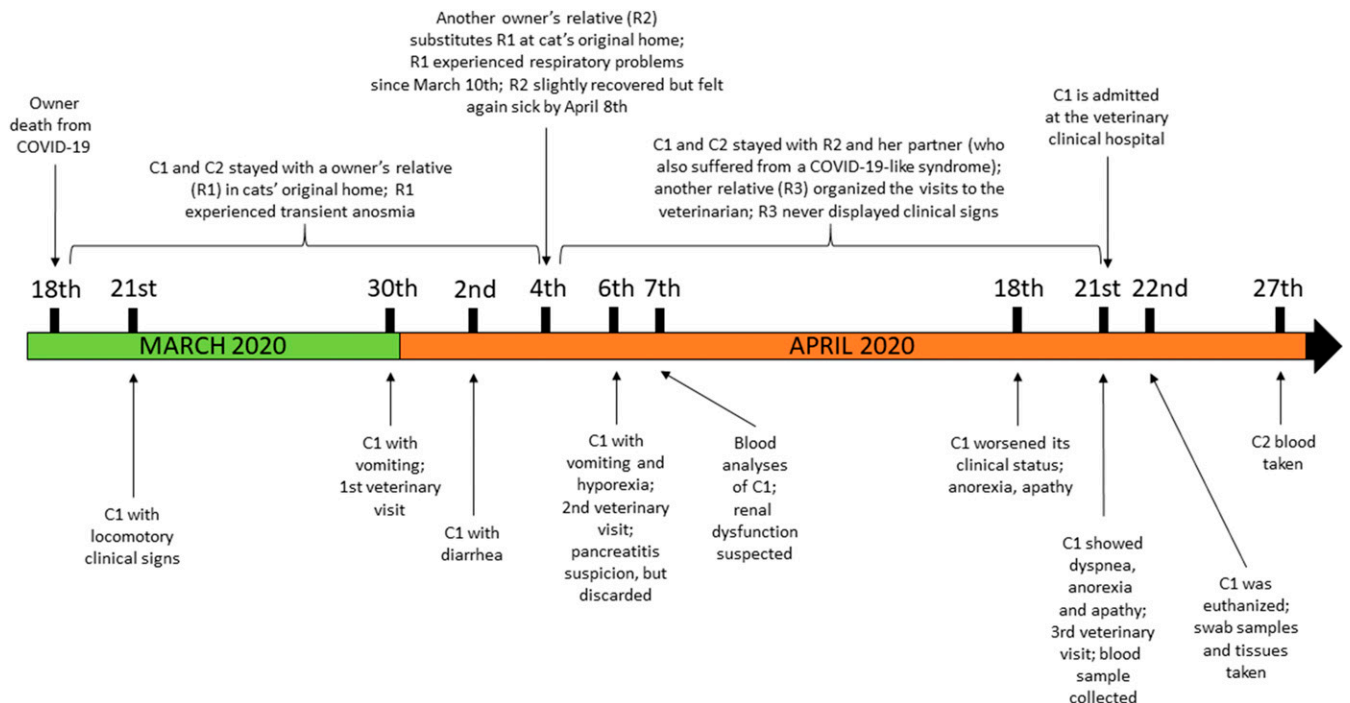


Fig. 2. Chronological events relating the clinical evolution of C1 in respect to the cat owners' situation; besides the diagnosis of COVID-19 of the initial owner, no SARS-CoV-2 testing was applied to relative 1 (R1), R2, and R3.

the low amount of SARS-CoV-2 (Ct values of >32) found in positive samples of C1, evidence of SARS-CoV-2 seroconversion, the lack of compatible lesions with a viral disease, and the preexisting morbid conditions suggest that SARS-CoV-2 infection in C1 was an incidental epidemiological finding. Therefore, it was concluded that the cause of death of the studied cat was unrelated to the novel coronavirus. However, since the susceptibility of domestic cats has now been established, extensive studies on domestic cat SARS-CoV-2 prevalence are needed to precisely ascertain the role of this sympatric species in the COVID19 pandemic. In addition, although highly speculative at this stage, it would be important to ascertain whether SARS-CoV-2 infection may be able to worsen already existing disorders in cats and other animal species.

Materials and Methods

Immunohistochemistry. A previously described immunohistochemistry technique to detect SARS-CoV-2 antigen (6), using the monoclonal antibody 40143-R019 (Sino Biological) at dilution 1:1,000, was applied on nasal turbinates, trachea, lung, mesenteric lymph nodes, and intestine.

In-House ELISA and Virus Neutralizing Tests. In-house ELISA techniques to detect antibodies against SARS-CoV-2 spike, S2, and nucleocapsid protein (N) as well as RBD were assayed on the plasma samples of C1 and C2. Briefly, Nunc maxisorp ELISA plates were coated with 50 ng per well of Spike, S2, RBD, or nucleocapsid protein (SinoBiologicals) in phosphate-buffered saline (PBS) overnight at 4 °C. After washing with PBS + 0.05% of tween-20 (Sigma-Aldrich), plates were blocked using PBS/1% of bovine serum albumin (Miltenyi Biotec) for 2 h at room temperature. Four serial dilutions of serum samples were added in duplicate starting at 1/500 dilution in blocking buffer for 1 h at room temperature. To calculate the specific signal, the background obtained using antigen-free wells was subtracted. Serum samples from four cats collected before 2019 were used as negative controls. All samples were assayed in parallel in the same plate. The horseradish peroxidase-conjugated Goat anti-Cat IgG (H+L) (1/20,000) (Jackson ImmunoResearch) was

used as detection antibodies. Plates were revealed with o-Phenylenediamine dihydrochloride (Sigma Aldrich) and stopped using 2 N of H₂SO₄. The signal was analyzed as the optical density (OD) at 492 to 620.

A virus neutralization assay in plasma of both C1 and C2 was performed following a previously published protocol (13).

SARS-CoV-2 Genome Sequencing. Viral RNA was extracted directly from C1 samples using the Indimag Pathogen kit (Indical Bioscience) and transcribed to complementary DNA with the PrimeScript RT reagent Kit, using a combination of oligo-dT and random hexamers, according to the manufacturer's protocol. For human nasopharyngeal swab samples, RNA was extracted using MagMAX Pathogen RNA/DNA Kit (ThermoFisher Scientific Inc.). DNA library preparation was performed using Swift amplicon SARS-CoV-2 panel (Swift Biosciences). Sequencing-ready libraries were then loaded onto Illumina MiSeq platform and a 300-base pair paired-end sequencing kit. Sequence reads were quality filtered, and primer sequences were trimmed off using cutadapt (14). Paired-end reads were matched using pear (15) and mapped against coronavirus reference (NC_045512.2) using bowtie2 tool (16). Consensus genomic sequence was called using samtools from the resulting alignment at a 20× coverage for frontal nasal turbinate and mesenteric lymph node samples of C1 (GISAID accid EPI_ISL_482820) and human sample (GISAID accid EPI_ISL_483059). Only genomic positions with at least 5× Q25 coverage were used. The nasal swab and other nasal turbinate samples (medial and caudal) from C1 failed to provide sufficient data to perform the analysis.

Data Availability. All study data are included in the article.

ACKNOWLEDGMENTS. We appreciate the collaboration of Esther Zamora, Carla Zamora, and their relatives, the owners of Negrito (C1) and Whisky (C2). We also thank Mónica Pérez from IRTA-CReSA for the histopathology laboratory work, and M. Pilar Armengol and the translational genomics platform team at the Institut de Recerca Germans Trias i Pujol for the sequencing studies. We also acknowledge the crowdfunding initiative of IrsiCaixa, <https://www.yomecorono.com>.

1. P. Zhou et al., A pneumonia outbreak associated with a new coronavirus of probable bat origin. *Nature* **579**, 270–273 (2020).
2. K. G. Andersen, A. Rambaut, W. I. Lipkin, E. C. Holmes, R. F. Garry, The proximal origin of SARS-CoV-2. *Nat. Med.* **26**, 450–452 (2020).
3. L. Bao et al., The pathogenicity of SARS-CoV-2 in hACE2 transgenic mice. *Nature* **583**, 830–833 (2020).
4. P. J. Halfmann et al., Transmission of SARS-CoV-2 in domestic cats. *N. Engl. J. Med.* **383**, 592–594 (2020).
5. Y. I. Kim et al., Infection and rapid transmission of SARS-CoV-2 in ferrets. *Cell Host Microbe* **27**, 704–709.e2 (2020).
6. B. Rockx et al., Comparative pathogenesis of COVID-19, MERS, and SARS in a non-human primate model. *Science* **368**, 1012–1015 (2020).
7. J. Shi et al., Susceptibility of ferrets, cats, dogs, and other domesticated animals to SARS-coronavirus 2. *Science*, **368**, 1016–1020 (2020).
8. P. Yu et al., Age-related rhesus macaque models of COVID-19. *Animal Model. Exp. Med.* **3**, 93–97 (2020).
9. T. H. C. Sit et al., Infection of dogs with SARS-CoV-2. *Nature*, 10.1038/s41586-020-2334-5 (2020).
10. N. Oreshkova et al., SARS-CoV2 infection in farmed mink, Netherlands, April 2020. *bioRxiv*:10.1101/2020.05.18.101493 (18 May 2020).
11. V. M. Corman et al., Detection of 2019 novel coronavirus (2019-nCoV) by real-time RT-PCR. *Euro Surveill.* **25**, 2000045 (2020).
12. J. A. Abbott, Feline hypertrophic cardiomyopathy: An update. *Vet. Clin. North Am. Small Anim. Pract.* **40**, 685–700 (2010).
13. J. Rodon et al., Search for SARS-CoV-2 inhibitors in currently approved drugs to tackle COVID-19 pandemic. *bioRxiv*:10.1101/2020.04.23.055756 (24 April 2020).
14. M. Martin, Cutadapt removes adapter sequences from high-throughput sequencing reads. *EMBnet. J.* **17**, 10 (2011).
15. J. Zhang, K. Kobert, T. Flouri, A. Stamatakis, PEAR: A fast and accurate Illumina paired-end reAd mergeR. *Bioinformatics* **30**, 614–620 (2014).
16. B. Langmead, S. L. Salzberg, Fast gapped-read alignment with Bowtie 2. *Nat. Methods* **9**, 357–359 (2012).