






## CKJ REVIEW

# Thrombotic microangiopathies assessment: mind the complement

Miquel Blasco <sup>1,2,\*</sup>, Elena Guillén<sup>1,\*</sup>, Luis F. Quintana <sup>1,2</sup>,  
Adriana Garcia-Herrera<sup>3</sup>, Gastón Piñeiro<sup>1,2</sup>, Esteban Poch <sup>1,2</sup>,  
Enric Carreras<sup>4,5</sup>, Josep M. Campistol<sup>1,2</sup>, Maribel Diaz-Ricart<sup>5,6</sup> and  
Marta Palomo<sup>4,5,6</sup>

<sup>1</sup>Department of Nephrology and Kidney Transplantation, Hospital Clínic, Centro de Referencia en Enfermedad Glomerular Compleja del Sistema Nacional de Salud (CSUR), University of Barcelona, Barcelona, Spain,

<sup>2</sup>Institute of Biomedical Research August Pi i Sunyer (IDIPABS), Malalties Nefro-Urològiques i Trasplantament Renal, Barcelona, Spain, <sup>3</sup>Department of Pathology, Hospital Clínic, University of Barcelona, Barcelona, Spain,

<sup>4</sup>Josep Carreras Leukaemia Research Institute, Hospital Clínic/University of Barcelona Campus, Barcelona, Spain, <sup>5</sup>Barcelona Endothelium Team, Barcelona, Spain and <sup>6</sup>Department of Pathology, Hematopathology

Unit, Hospital Clínic of Barcelona, Biomedical Diagnosis Centre (CDB), Institute of Biomedical Research August Pi i Sunyer (IDIPABS), University of Barcelona, Barcelona, Spain

Correspondence to: Miquel Blasco; E-mail: miblasco@clinic.cat

\*These authors contributed equally to this work.

## ABSTRACT

When faced with microangiopathic haemolytic anaemia, thrombocytopenia and organ dysfunction, clinicians should suspect thrombotic microangiopathy (TMA). The endothelial damage that leads to this histological lesion can be triggered by several conditions or diseases, hindering an early diagnosis and aetiological treatment. However, due to systemic involvement in TMA and its low incidence, an accurate early diagnosis is often troublesome. In the last few decades, major improvements have been made in the pathophysiological knowledge of TMAs such as thrombotic thrombocytopenic purpura [TTP, caused by ADAMTS-13 (a disintegrin and metalloproteinase with a thrombospondin Type 1 motif, member 13) deficiency] and atypical haemolytic uraemic syndrome (aHUS, associated with dysregulation of the alternative complement pathway), together with enhancements in patient management due to new diagnostic tools and treatments. However, diagnosis of aHUS requires the exclusion of all the other entities that can cause TMA, delaying the introduction of terminal complement blockers, which have shown high efficacy in haemolysis control and especially in avoiding organ damage if used early. Importantly, there is increasing evidence that other forms of TMA could present overactivation of the complement system, worsening their clinical progression. This review addresses the diagnostic and therapeutic approach when there is clinical suspicion of TMA, emphasizing complement evaluation as a potential tool for the inclusive diagnosis of aHUS, as well as for the improvement of current knowledge of its pathophysiological involvement in other TMAs. The development of both new complement activation biomarkers and inhibitory treatments will probably improve the management of TMA patients in the near future, reducing response times and improving patient outcomes.

Received: 21.6.2020; Editorial decision: 31.8.2020

© The Author(s) 2020. Published by Oxford University Press on behalf of ERA-EDTA.

This is an Open Access article distributed under the terms of the Creative Commons Attribution Non-Commercial License (<http://creativecommons.org/licenses/by-nc/4.0/>), which permits non-commercial re-use, distribution, and reproduction in any medium, provided the original work is properly cited. For commercial re-use, please contact [journals.permissions@oup.com](mailto:journals.permissions@oup.com)

**Keywords:** complement system, C5b-9 deposits, endothelial cells (ECs), membrane attack complex (C5b-9), soluble C5b-9, thrombotic microangiopathies

## INTRODUCTION

Thrombotic microangiopathy (TMA) is a histological lesion common to multiple diseases and with variable clinical presentation due to its systemic nature [1, 2]. Recently, advances have been made in the understanding of the pathophysiological mechanisms involved [3, 4]. However, an accurate diagnosis and early start of aetiological treatment able to change the natural history of these serious conditions may be challenging. In addition, the development of new-generation functional and genetic studies has revealed an emerging role of the complement system—at different levels and degrees—in the pathogenesis of many of the entities that can produce TMA [5–10].

Given the high complexity of the clinical management of patients with TMA, this review attempts to shed light on the diagnostic process when there is clinical suspicion and/or histological confirmation of TMA, and stresses the need for complete and comprehensive assessment of complement activation. Complement status evaluation will not only improve our pathophysiological knowledge of the different TMA forms but could also have diagnostic and therapeutic implications. Due to the current development of multiple complement blockers [11, 12], these data could eventually allow inclusive diagnosis and personalized medicine.

## CLINICAL SUSPICION

Thrombotic microangiopathies are a group of disorders characterized by non-immune intravascular haemolysis and ischaemic organ dysfunction. The classical laboratory findings are thrombocytopenia (or >25% decrease in platelet count), resulting from platelet aggregation and consumption, and microangiopathic haemolytic anaemia (MAHA), resulting from erythrocyte fragmentation in the microcirculation due to partial occlusion by platelet aggregates [1, 13]. MAHA is defined by the presence of schistocytes (fragmented erythrocytes) that can be found on peripheral blood smear, reticulocytosis and a negative direct antiglobulin (Coombs) test. Other less specific laboratory findings for MAHA are: increased serum lactate dehydrogenase (LDH), as a result of tissue ischaemia and cell lysis; decreased haptoglobin levels, after its binding to circulating haemoglobin (Hb) released by haemolysis; and unconjugated hyperbilirubinaemia. The severity of all these findings reflects the extent of microvascular platelet aggregation [14].

From a clinical point of view, most patients present with non-specific symptoms that are a result of microvasculature injury. TMA patients often present with high blood pressure and, in some cases, with hypertensive retinopathy [2]. The results of coagulation tests [prothrombin time (PT) and activated partial thromboplastin time (aPTT)] are usually normal [13]. However, patients with very severe disease associated with disseminated intravascular coagulation (DIC) are the exception, as they frequently present with septic shock and prolongation of PT and aPTT [13]. The most commonly affected targets in TMA are the brain, kidneys, heart, skin and gastrointestinal system, although the clinical presentation can differ depending on the underlying aetiology of the disease [2].

Classically, thrombotic thrombocytopenic purpura (TTP) and haemolytic uraemic syndrome (HUS), both entities occurring with no associated underlying cause, have been classified as

primary TMA forms (Table 1). However, the classification of TMAs is challenging and constantly evolving [3, 13, 15]. On the basis of clinical findings, TTP often presents with ischaemia of the brain or gastrointestinal tract, and rarely causes severe acute kidney injury (AKI) [3]. Diagnosis of TTP relies on measurement of very low plasma ADAMTS-13 (a disintegrin and metalloproteinase with a thrombospondin Type 1 motif, member 13) activity (<10%) [3]. However, when ADAMTS-13 testing is unavailable and urgent therapy is needed, the PLASMIC score can be used, which is a valuable clinical tool based on clinical and laboratory findings [16]. If the predominant feature at presentation is severe AKI, then the disorder will most probably be classified as HUS. The most common form (90% of HUS)—typical HUS—is associated with bloody diarrhoea due to different pathogens, especially *Escherichia coli*. Atypical HUS (aHUS) is an ultra-rare disease (incidence 0.5–2 per million per year), and it is based on a clinical diagnosis after the exclusion of other causes of TMA. aHUS is caused by dysregulation of the alternative complement pathway, of either acquired or genetic origin [13, 17, 18].

TMAs classified as secondary forms can occur in multiple clinical settings (Table 1), among which the most important are: autoimmune diseases; cancer and its treatment; pregnancy-related TMA; solid organ transplantation (SOT) and haematopoietic cell transplantation (HCT); and multiple infections [13, 19].

## HISTOLOGY

Because the histological findings of TMA are not pathognomonic, histological confirmation is not mandatory to establish a diagnosis. Therefore, an aetiological diagnostic approach to TMA can be initiated once suspicion is established. However, as TMA can manifest as a diverse range symptoms and conditions, histological confirmation is useful, especially when the clinical presentation is uncommon or incomplete, as well as to determine prognosis [2]. Several organs may be affected by TMA, and histopathological findings in all of them have been described in the literature. Classic findings of TMA consist of endothelial cell (EC) swelling, often associated with luminal fibrin thrombi, and minimal or absent inflammation. Heart, lung and brain biopsies have only been described in autopsies, whereas the skin, gastrointestinal tract and gingiva are the suggested sites for sampling, whether or not there is a visible lesion [20–22]. Kidney tissue can also be sampled and remains the gold standard for kidney TMA diagnosis and to exclude other potential causes of kidney

**Table 1. Primary and secondary TMA forms**

Primary TMA	Secondary TMA
TTP	Autoimmune diseases
Hereditary TTP, acquired/immune-mediated TTP	Infections
HUS	Pregnancy
Acquired HUS: infectious causes (STEC-HUS, <i>S. pneumoniae</i> , <i>Shigella</i> , etc.); antibody against CFH (aHUS)	SOT
Hereditary HUS: complement gene mutations (aHUS)	HCT
	Methylmalonic acidemia
	Malignancy
	Medications
	Malignant hypertension

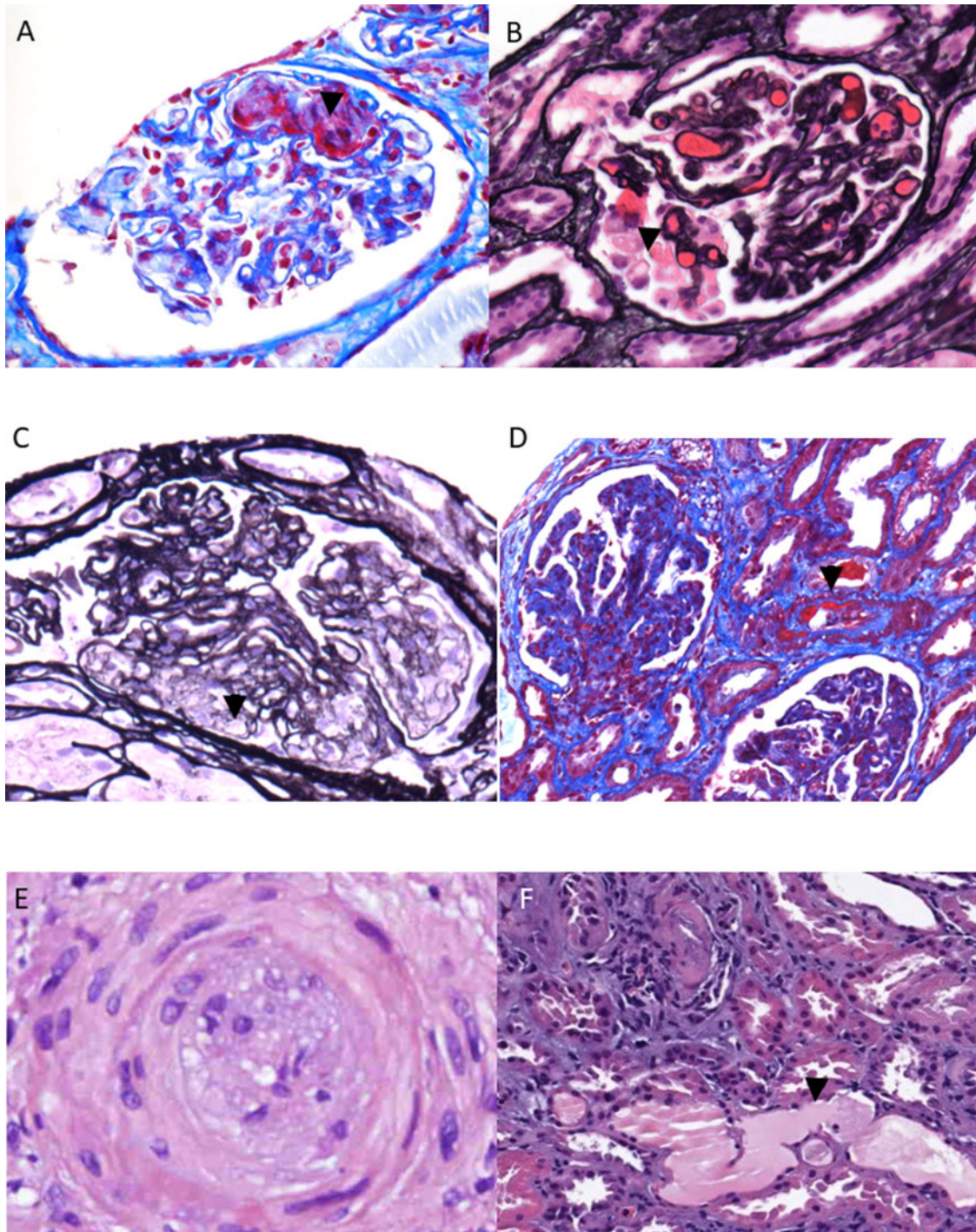


injury. However, the decision to perform a kidney biopsy must be individualized on a case-by-case basis, given that in patients with suspected TMA there is a high bleeding risk, due to the presence of high blood pressure, thrombocytopenia and uraemia, among other factors. The histopathological findings in kidney biopsy reflect tissue response to endothelial injury,

resulting in changes in different structures that progress over time [23]. These changes can be categorized as below.

#### Glomerular changes

In the acute phases of TMA, ECs may appear swollen and fibrin-platelet thrombi are identified within glomerular capillaries



**FIGURE 1:** Pathological findings of renal biopsy in acute and chronic TMA. (A) A thrombus is identified within glomerular capillaries (arrow head) (Masson's trichrome, 60 $\times$ ). (B) Segmental mesangiolysis is indicative of active lesion (arrow head) (silver, 40 $\times$ ). (C) Chronic lesions show reduplication of GBM (arrow head) (silver, 60 $\times$ ). (D) Necrosis of the arterial wall (arrow head) and glomeruli of shrunken appearance (Masson's trichrome, 20 $\times$ ). (E) Artery show intimal thickening with concentric appearance ('onion-skin') (haematoxylin and eosin, 60 $\times$ ) (F) Acute tubular necrosis (arrow head) is a finding resulting of ischemic changes (haematoxylin and eosin, 20 $\times$ ).

(Figure 1A). Other findings such as detachment of the ECs from glomerular basement membranes (GBMs), mesangiolytic or necrosis can be observed (Figure 1B). If TMA persists, then ECs continue to produce basement membrane material, leading to GBM remodelling with double contours and mesangial expansion, resulting in a membranoproliferative glomerulonephritis-like pattern indicative of chronic phases of TMA [24–26] (Figure 1C).

### Vascular changes

When the arterioles and arteries are involved, intimal swelling, mucoid change and proliferation, and necrosis of the arterial wall or thrombi in the lumen are observed (Figure 1D). In this context, glomeruli appear ischaemic and shrunken. In the chronic phase, these changes may lead to concentric lamination of intimal fibrosis causing 'onion-skin' appearance [24, 26] (Figures 1E).

### Tubulointerstitial changes

Acute tubular necrosis is a finding resulting from ischaemic changes. Severe TMA cases can show cortical necrosis, which is predictive of a poor outcome [25, 26] (Figure 1F).

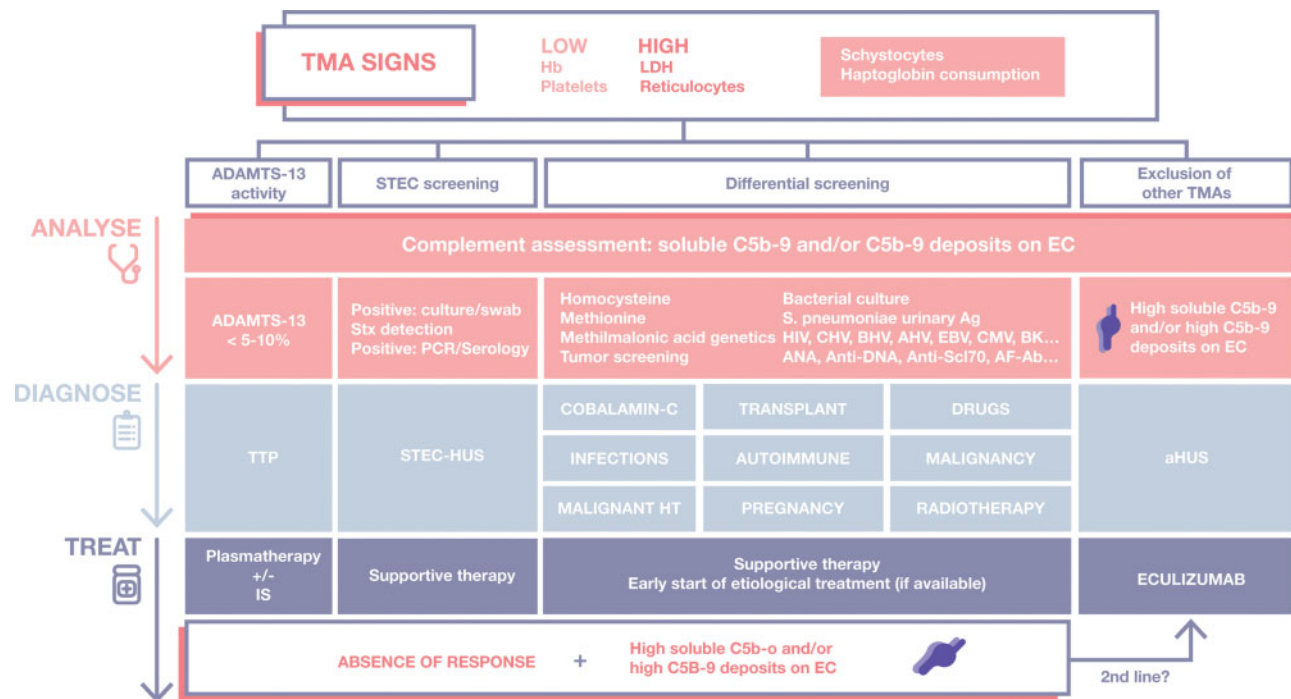
## DIFFERENTIAL DIAGNOSIS

When there is clinical suspicion and/or histological confirmation of TMA, a broad and rapid differential diagnosis must be made to achieve an aetiological diagnosis and reduce delay in

administering early specific treatment. With the aim of improving TMA management, we propose an algorithm describing the sequence of all the complementary tests that should be carried out according to patient characteristics and clinical settings (Figure 2).

### TTP

The cause of TPP is an ADAMTS-13 deficiency, which can be congenital or acquired. This deficiency results in unusually large von Willebrand factor (VWF) multimers and, therefore, a high risk of platelet thrombi in small vessels. Measurement of ADAMTS-13 activity and inhibitors is crucial to confirm the diagnosis of hereditary and autoimmune TTP, but there are still uncertainties about the interpretation of these data. Importantly, ADAMTS-13 activity is usually normal or modestly reduced (>20%) in pregnancy [27] and other forms of TMA associated with severe sepsis, HCT, systemic lupus erythematosus (SLE), disseminated malignancy, recent surgery, severe liver impairment and DIC [28–30]. Partial ADAMTS-13 deficiency (between 10% and 60% of activity) was found in 50% of aHUS patients and Shiga toxin (Stx)-producing *Escherichia coli* HUS (Stx *E. coli* HUS; STEC-HUS) [31]. The commercially available techniques to measure ADAMTS-13 activity, autoantibodies and antigen (Ag) differ, depending on the laboratories. Regarding activity, fluorogenic assays based on the use of a peptide containing 73 amino acid residues from the central A2 domain of VWF (FRET-VWF73) as a substrate, conjugated with



**FIGURE 2:** TMA management algorithm. When there are TMA signs, clinical and laboratory evaluation is needed to achieve an aetiological diagnosis and specific treatment. ADAMTS-13 activity assessment is urgent, and if <10%, a TTP should be diagnosed, followed by specific treatment. If Stx is detected, then diagnosis of STEC-HUS should be followed by supportive therapy. This supportive therapy, among early start of aetiological treatment, follows the differential diagnosis of all secondary TMA forms. When aHUS is suspected (by exclusion of other TMA forms), a complete evaluation of complement should be performed, eculizumab being the first-line treatment. Complement assessment though both *in vitro* evaluation of C5b-9 deposits on ECs and soluble C5b-9 levels is strongly encouraged in all cases of TMA, when possible. Especially in secondary forms, where if the patient shows complement overactivation and no response to the treatment of choice, a second-line treatment consisting of administration of complement terminal blockers may be contemplated. If complement assessment is not available—in secondary TMA forms—a therapeutic approach with eculizumab may be also considered (in the absence of response to aetiological treatment). ADAMTS-13, a disintegrin and metalloproteinase with a thrombospondin Type 1 motif, member 13; AF-ab, Anti-phospholipid antibodies; HAV, hepatitis A virus; HBV, hepatitis B virus; HCV, hepatitis C virus; CMV, cytomegalovirus; EBV, Epstein-Barr virus; HIV, human immunodeficiency virus.



fluorescence energy resonance transfer (FRETs), offers quick and reproducible results [32]. The International Society of Thrombosis and Haemostasis guidelines establish that when plasma ADAMTS-13 activity is <10IU/dL (often referred to as 10% of normal ADAMTS-13 activity), the diagnosis of TTP is more likely [33]. Autoantibodies against ADAMTS-13, usually immunoglobulin G, are the cause of acquired TTP, a rare autoimmune disease [34]. These antibodies show inhibitory activity primarily mediated by their binding to ADAMTS-13 spacer domain, critical for VWF recognition. However, there are also antibodies that may cause rapid clearance of ADAMTS-13. Regarding ADAMTS-13 Ag, the concentrations of this enzyme in human plasma range from 0.7 to 1.4 µg/mL (3.5–7.0 nM) [35] and can be severely reduced or even non-existent in congenital TTP. This very rare condition, with a prevalence of ~0.05–0.4/100 000, is transmitted by autosomal recessive inheritance [36].

### STEC-HUS

The most common cause of HUS, particularly in children, is Stx-producing bacteria, especially *E. coli* serotype O157:H7 [37]. STEC-HUS is usually initiated a few days after clinical gastroenteritis (typically bloody diarrhoea) caused by STEC. Stx, a potent cytotoxin, apparently initiates the disease process, playing a central pathophysiological role damaging ECs from the vasculature [6], among red cells and platelets [18]. This damage could constitute triggers leading to enhanced complement activation. The clinical manifestations of Stx-induced HUS overlap with those of other related syndromes, but the molecular mechanisms differ considerably. Accurate diagnosis of STEC infections is important for the appropriate management of infected patients. Candidates for the detection of all STEC serotypes include chromogenic agars, enzyme immunoassays, quantitative real-time polymerase chain reaction (qPCR) and, most recently, methods of whole-genome analysis [38].

### Autoimmune diseases

The main systemic disorders related to TMA are systemic sclerosis (SSc) and SLE, with or without associated antiphospholipid syndrome (APS). Their diagnosis requires the performance of a complete clinical assessment and autoimmune panel, including: serum antinuclear antibodies (ANA), anti-double-stranded DNA (ds-DNA) antibodies (using *Crithidia luciliae* indirect immunofluorescence test) and anti-extractable nuclear Ag antibodies, including anti-Sm, anti-SSA, anti-SSB and anti-RNP antibodies (the latter associated with overlap connective tissue diseases), as well as serum complement factors (C3, C4 and CH50) for SLE diagnosis; antitopoisomerase I (anti-Scl-70) antibody, anticentromere antibody (ACA) and anti-RNA polymerase III antibodies for SSc diagnosis; and anti-cardiolipin antibody, anti-β2GP-1 antibody and lupus anticoagulant (LA) for APS diagnosis [39].

### Infections

Many systemic infections have been identified as a TMA-causing agent [40]. Among them, the most important ones are: numerous viral infections (outlined in Figure 2); bacterial infections such as bacterial endocarditis, spotted fever rickettsiosis or infections caused by *Streptococcus pneumoniae* (the latter shows a positive Coombs test as a differentiating feature); and infections caused by red blood cell parasites (*Plasmodium falciparum*, *Plasmodium vivax*). In each particular case, and depending

on the clinical suspicion, different diagnostic tests should be performed (serological tests, qPCR, cultures, etc.) [41].

### Pregnancy-associated TMA

There are different circumstances in which TMA can occur during pregnancy. Haemolysis, Elevated Liver enzymes and Low Platelets (HELLP) syndrome, which usually occurs after the 20th week of pregnancy, is defined by the coexistence of thrombocytopenia, MAHA and liver damage. It can be associated with preeclampsia, defined by new-onset hypertension and proteinuria, with or without end-organ dysfunction. If seizures occur in a patient with preeclampsia, then the diagnosis changes to eclampsia [42]. Moreover, pregnancy may trigger new-onset TTP or a relapse, especially in the first trimester [8]. Additionally, in up to 20% of women, onset of aHUS occurs during the postpartum period [43–45]. In this case, it is hypothesized that there are different complement system regulatory proteins on the placental surface, and that their loss in conjunction with complement overactivation during delivery may be a perfect trigger [46].

### SOT and HCT

Aetiological diagnosis is challenging because TMA may be associated with several triggers, such as ischaemia–reperfusion injury and antibody-mediated rejection in the case of SOT, or induction treatment and graft-versus-host prevention regimens in HCT. Opportunistic infections and immunosuppressive treatment, mainly related to calcineurin and mammalian Target of Rapamycin (m-TOR) inhibitors, could be the cause of TMA in both transplantation modalities. TMA associated with HCT is especially recognized to be associated with excessive complement activation, likely triggered by endothelial injury, and new evidence suggests neutrophil extracellular trap (NETs) formation as the mechanistic link between these two entities [47]. NETs are deposits of antimicrobial proteins on a single DNA framework released by activated neutrophils [48], and can activate complement via both alternative and non-alternative pathways [49]. Levels of NETs are measured through quantification of circulating ds-DNA in a quick and easy assay, and could eventually constitute a new marker to be considered in the diagnosis of TA-TMA.

### Methylmalonic acidaemia and/or aciduria

This is an uncommon and heterogeneous congenital metabolic disorder of cobalamin (vitamin B12), resulting in methylmalonic acid and homocysteine accumulation in blood and tissues, with increased urinary excretion of both compounds. In this setting, endothelial damage is caused by high homocysteine levels, among other factors. Confirmatory genetic testing should be performed in patients with positive metabolic screening [50].

### Malignancy

If there is any symptomatic suggestion of malignancy or a history of cancer in the context of TMA, it is imperative to perform diagnostic tests (CT scan, bone marrow study, serum tumour markers). The evaluation of TMA in patients with cancer focuses on two principal aetiologies: (i) cancer-induced TMA, commonly caused by systemic metastases due to microvascular obstruction by tumour cells; and (ii) chemotherapy-induced TMA, caused by dose-dependent toxicity (with gradual onset of

TMA signs), or by an immune-mediated reaction (drug-dependent antibodies), the latter leading to rapid onset of TMA [51].

### Medications

In most cases, TMA is caused by dose-dependent direct endothelial damage (non-immune-mechanism). The most frequent forms of drug-induced TMA are summarized in Table 2 [52].

### Malignant hypertension

A direct damage of the endothelium is produced in this entity. Ocular fundus study may show hypertensive retinopathy Grades III–IV. In these patients, optimal blood pressure control is the most critical initial management and may be the only

treatment required. If, after optimal blood pressure control, there is no improvement in platelet count, other causes of TMA must be considered [2].

### aHUS

This entity is caused by a dysregulation of alternative complement pathway over cell surfaces [presence of complement proteins mutations or antibodies against complement factor H (CFH)], damaging ECs through complement terminal phase activation/membrane attack complex (MAC) formation [19, 53]. aHUS diagnosis is by exclusion of other TMA forms.

Table 2. Main drug-induced TMA

Cancer therapies	Immunosuppressants	Others
Cytotoxic agents: gemcitabine, mytomicin C VEGF inhibitors: bevacizumab, sunitinib Proteasome inhibitors: bortezomib, carfilzomib	Calcineurin inhibitors: cyclosporine, tacrolimus m-TOR inhibitors: sirolimus, everolimus	Biological agents: adalimumab, imatinib Antibiotics: ciprofloxacin, metronidazole, nitrofurantoin, trimethoprim/sulfamethoxazole Commonly used drugs: ibuprofen, ketorolac, clopidogrel, simvastatin, oestrogen/progesterone

### Complement system assessment

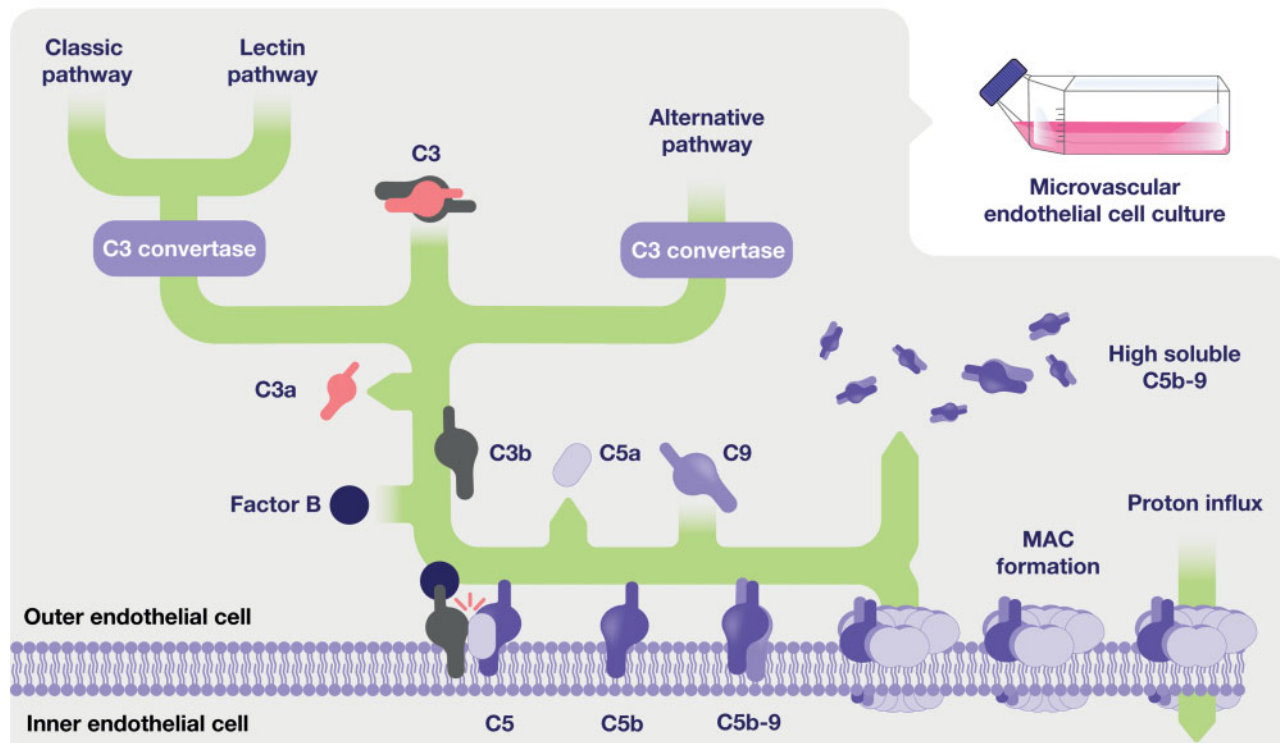


FIGURE 3: Complement system. The complement system is the first line of physical defence against pathogens and altered host cells and is composed of a cascade of several plasmatic and membrane proteins expressed on the cell surface. There are three different pathways through which the complement system can be activated: the classical, the lectin and the alternative pathway (upper part of the image). Each of the pathways leads to the activation of C3 convertase that cleaves C3 into C3a and C3b, which binds Factor B and generates active convertases on targeted surfaces. The terminal complement cascade is then initiated by the cleavage of protein C5 by C5 convertase, followed by C5a release (potent anaphylotoxin) and C5b-9 molecule assembly, forming the MAC. This structure becomes inserted into the target cell lipid bilayer and induces cell lysis through proton influx. Dysfunction of the complement cascade may be mediated by aberrations in the pathways of activation, complement regulatory proteins or complement deficiencies, whether genetic or acquired. Soluble C5b-9 levels and C5b-9 deposition induced by patient activated plasma on ECs *in vitro* are two of the most promising complement monitoring tools used to provide insight into the integrity of the entire complement reaction cascade.

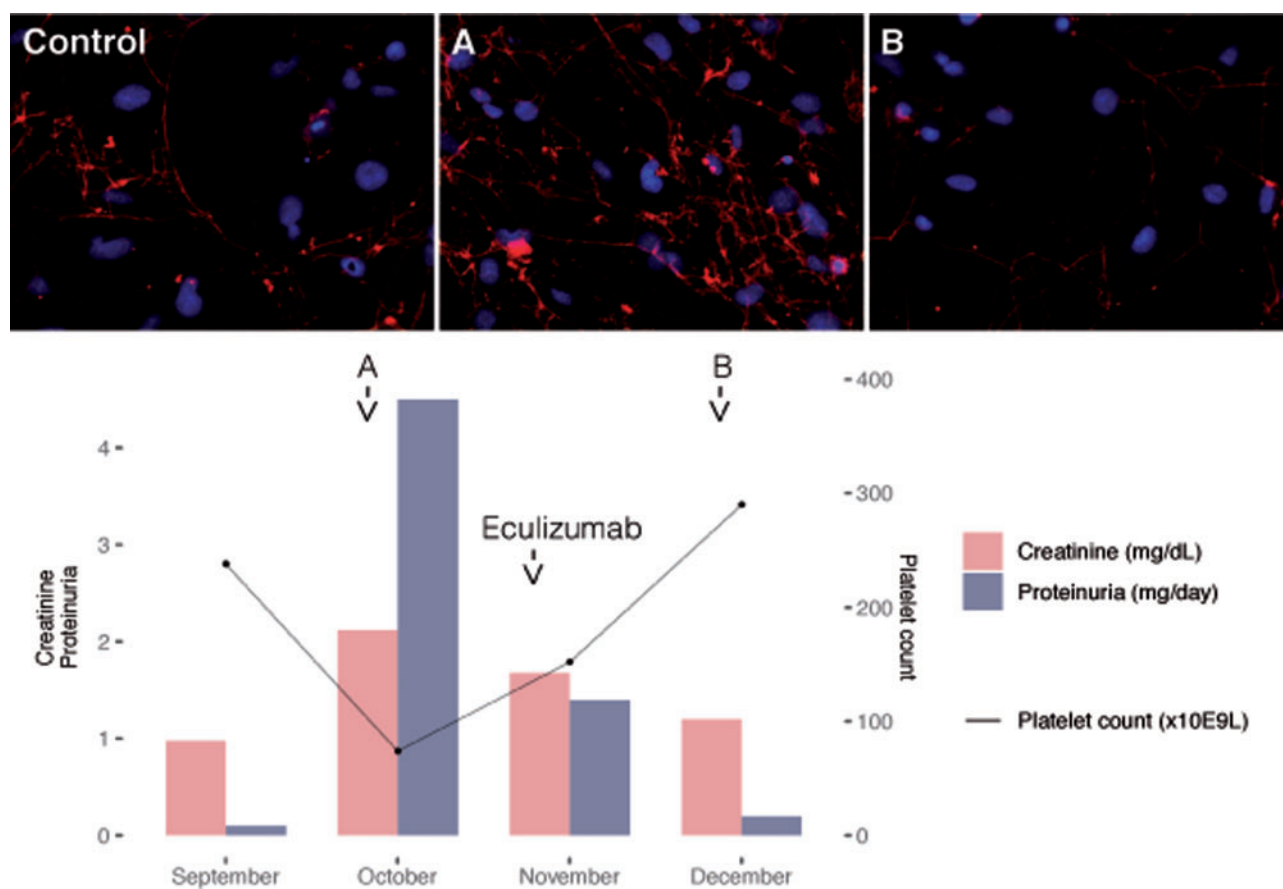
## COMPLEMENT ASSESSMENT IN TMA

Complement is a part of the innate immune surveillance system (Figure 3), its main functions being chemotaxis, opsonization, clearance of immunocomplexes and cell lysis through MAC formation. Complement dysregulation has been linked to several forms of TMA [5–10]. Therefore, we suggest a study of complement in all TMA patients, immediately after diagnosis and before any specific treatment (Figure 2). Among all the laboratory tests for complement assessment (discussed below), we strongly recommend, when possible, analysis of C5b-9 deposition on ECs in culture and quantification of soluble C5b-9 levels as useful markers of terminal complement pathway overactivation [54–60] (Figure 3). Although this assessment is not a quick procedure, and is not commercially available, knowledge of complement involvement may critically reduce diagnostic times when aHUS is strongly suspected (Figure 4), and could offer an

alternative therapeutic process when there is a lack of response to initial treatment in other forms of TMA [10, 61–63] (Figure 2).

## Functional analysis

Complement functional analyses provide insight into the integrity of the entire complement reaction cascade. These tests are suitable for investigating suspected complement deficiencies and must be interpreted in the context of the complete complement picture. However, there is still an open discussion about the utility of complement functional tests as biomarkers of complement activation in both TMA debut and response to therapy. Complement assays are performed on serum or plasma samples. It is important to maintain the samples on ice in order to limit the amount of ongoing tick-over. Functional complement activity assays are used as screening tests and are based on the ability of complement to induce lysis of erythrocytes.



**FIGURE 4:** Clinical case—complement assessment in TMA for early aetiological treatment. A 52-year-old man, with a past medical history of pancreatic ductal adenocarcinoma (cT1cN0M0), was treated with surgery and concomitant gemcitabine from March to August 2017. After 2 months, he showed nephrotic syndrome, MAHA, thrombocytopenia and progressive kidney failure. A kidney biopsy confirmed TMA both in the glomerulus and arterioles with negative immunofluorescence. To make a rapid differential diagnosis, we ruled out TTP (ADAMTS-13 activity: 87%), STEC-HUS (negative Stx detection), infections (negative cultures) and autoimmune diseases, among other causes of TMA. Concomitantly, we performed a complement assessment with plasma levels of complement components (C3, C4, CH50 and C5b-9) and also with C5b-9 deposition evaluation on ECs culture [57]. Complement levels were within the normal range, but 5 days after admission, we identified significant deposition of C5b-9 on EC ( $3.2 \pm 0.2$ -fold increase,  $P < 0.05$ ) (Figure 4) (A). Despite these results, we spent 4 weeks in the initial management of TMA and especially ruling out tumour recurrence (tumour markers, PET-CT) and gemcitabine-induced TMA. MAHA, thrombocytopenia, kidney failure and nephrotic syndrome persisted despite supportive therapy and plasma exchange (18 sessions). Finally, we reached a clinical diagnosis of aHUS by exclusion. At that point (November 2017), we started eculizumab following the data sheet, with TMA haematological response (normalization of platelet count, LDH, haptoglobin and reticulocytes) after 2 weeks, and normal kidney function with complete remission of nephrotic syndrome after 4 weeks, as well as a negativization of C5b-9 deposits (Figure 4) (B). Three months after admission, genetic study revealed a CFI mutation (heterozygous variant in exon 5, c.739T>G [p.Cys247Gly] considered as pathogenic) and risk haplotypes in heterozygosity for CFH and MCP. After 29 months, the patient maintained haematological and kidney remission on eculizumab. In conclusion, complement assessment in all TMA cases (the proposed algorithm in Figure 2) could critically reduce diagnostic times for aHUS (supporting physician suspicion) and establish the therapeutic potential of complement blockade in secondary TMA forms when aetiological treatment—if available—fails.

C5b-9 deposition on ECs in culture. This technique is used to screen for complement abnormalities. It was set up using aHUS as the gold standard disease in which complement is dysregulated over cell surfaces. Furthermore, it has been proven useful to monitor eculizumab treatment in aHUS patients, and to assess complement involvement in severe preeclampsia and HELLP syndrome or to exclude complement as a pathophysiological factor in malignant hypertension [57]. To evaluate complement activation, human dermal microvascular EC line CDC/EU. HMEC-1 (HMEC) [64] is seeded on gelatin-covered glass coverlips. Cells are washed with test medium [54] and are then incubated with activated plasma (a-plasma), obtained by mixing patients' plasma with control pooled sera (1:1) and diluting the mix with test medium. Control samples consist of mixing healthy plasma from donors with pooled serum from controls. Then, cultures are washed and fixed with paraformaldehyde. For C5b-9 detection, immunostaining is performed with an anti-human complement C5b-9 complex antibody followed by a fluorescent conjugated secondary antibody and DAPI. The area covered by C5b-9 deposits is calculated from fluorescent micrographs and expressed as the average fold increases of each condition versus control. This test is a modification of that developed by Noris et al. [54] but takes advantage of the multiple links between the complement and the clotting system [65] to enhance C5b-9 deposition and reduce the coefficient of variation obtained for each sample. However, a laboratory that offers this evaluation needs to have ECs in culture available constantly.

Total haemolytic complement (CH50) assay. This assay analyses the functional ability of serum complement components to lyse sheep red blood cells (SRBCs) pre-coated with rabbit anti-sheep antibodies. Therefore, it mainly evaluates the classic complement activation pathway. In this assay, serial dilutions of the sample are made and incubated with SRBC and the results are reported as the reciprocal of the dilution at which 50% haemolysis occurs (CH50) [66]. Low levels of CH50 may occur due to congenital complement deficiencies, increased consumption of complement components or insufficient synthesis of complement factors, and during infections, disease exacerbation in patients with SLE and in patients with immune complex diseases such as glomerulonephritis. Haemolytic and enzyme-linked immunosorbent assays are currently commercially available [67].

Complement alternative pathway (AP50) assay. This assay incubates serial dilutions of patients' sera with rabbit or guinea pig erythrocytes in conditions that specifically activate the alternative pathway [68]. A low AP50 result is associated with deficiencies in FB, FD, FH and properdin, glomerulonephritis, aHUS, STEC-HUS and consumption of complement proteins [67].

Modified Ham test. The principle of this technique is that paroxysmal nocturnal haemoglobinuria cells are more sensitive to alternative pathway of complement due to deficiency of complement regulatory proteins. The incubation of cells with this deficiency with sera from aHUS patients is supposed to result in a significant increase of nonviable cells compared with serum from healthy controls [69].

### Quantification of individual complement components and regulators and activation markers

Unfortunately, the quantification of levels of the different complement components in serum is not a straightforward approach in TMA diagnosis, as soluble levels are not reliable biomarkers of complement activation in any form of TMA,

including aHUS [58]. However, comprehensive knowledge of different complement components or/and complement activation marker levels could provide hints about possible complement pathway overactivation. The quantification of the majority of individual complement components can be performed through standard immunochemical assays [70]. C3 and C4 plasma levels have been available in routine diagnostic laboratories for decades. Low levels of these two components are associated with a number of pathologies such as aHUS (C3 consumption only in 30–50% of patients), TTP, STEC-HUS and glomerulonephritis, among others [67, 70, 71]. The quantification of Factor B levels could provide information regarding which pathway is actively consuming C3. Properdin quantification is available only in specialized laboratories, but knowledge of its levels could be useful as it is the only positive regulator of the alternative pathway and its levels could be reduced in cases of complement activation. The decay products of C3, C4, C5 and Factor B can be quantified in specialized laboratories and offer information about the activation state of the complement system. The main drawback to its use in clinical practice is that, in general, decay products have a very short decay time or half-life. From all the complement activation molecules evaluated, soluble C5b-9 (sC5b-9) may reflect the overall activation of the complement system as the activation of any of the three initiating complement pathways ultimately leads to the generation of the MAC. However, there are discrepant conclusions regarding the clinical value of this assay, especially in aHUS. Palomo et al. [57] and Noris et al. [54] reported that sC5b-9 is not a suitable biomarker of complement activation in aHUS as they found no correlation between levels of this molecule and clinical progression of the disease. Contrarily, Volokhina et al. [59] and Cataland et al. [60] suggested sC5b-9 as a helpful biomarker to confirm clinical diagnosis of aHUS as levels were elevated in patients at the acute phase of the disease and comparable to healthy controls when patients were in remission. Bu et al. [58] reported data suggesting that increased sC5b-9 levels are indicative of active disease (positive predictive value, 89%) but should be used in the context of other complement assays (negative predictive value, 46%).

### Genetic analysis

Molecular and genetic complement study is mandatory in patients with clinical suspicion of aHUS [23], reinforcing the diagnosis if pathogenic variants or CFH antibodies are identified (50–60% aHUS patients), and allowing genetic counselling and offering genotype–phenotype correlations that predict prognosis, treatment response and post-transplant recurrence risk [72]. Genetic testing must be carried out in reference

**Table 3. Genetic and acquired complement abnormalities in aHUS**

Complement regulatory factors	Complement activation factors	Coagulation-related factors
CFH	C3	THBD
CFH/CFHR hybrid gene	CFB	DGKE
CFI		PLG
MCP		
Anti-CFH antibodies		

CFHR, complement factor H related; CFI, complement factor I; MCP, membrane cofactor protein; C3, complement component C3; CFB, complement factor B; THBD, thrombomodulin; DGKE, diacylglycerol kinase epsilon; PLG, plasminogen.



complement laboratories, capable of identify genetic variants, risk haplotypes, complex genomic rearrangements and hybrid genes (Table 3). Its main limitations are its high cost and long response time; therefore, clinical diagnosis of aHUS, by exclusion, and initiation of an aetiological treatment should never be delayed. In other forms of TMA, there is increasing evidence of the presence of genetic variants in complement proteins that could be related to its pathophysiology [73–76]. However, there are no cost-effectiveness studies that allow a universal recommendation to carry out these studies in all TMA cases.

## TREATMENT OF DIFFERENT TMA FORMS

### Primary TMA forms

**TTP.** The mainstay treatment for hereditary TTP is plasma infusion to raise ADAMTS-13 activity. Regarding acquired TTP, current standard management consists in therapeutic plasma exchange (TPE). TPE involves removal of the patient's plasma by apheresis and replacement with donor plasma, thus removing ADAMTS-13 autoantibodies and replacing plasma with normal ADAMTS-13 activity. The duration of TPE and the number of procedures required to achieve remission, defined by the recovery of the platelet count, is highly variable. Immunosuppressive agents are routinely added to TPE for the treatment of acquired TTP; however, there are limited data from high-quality clinical trials to direct the most appropriate use of these treatments [17, 77]. Glucocorticoids are thought to speed up the recovery because they reduce the production of both ADAMTS-13 inhibitor (auto-antibody) and cytokines production. The administered dose of glucocorticoids varies according to the severity of TTP presentation; for severe cases, high dose of glucocorticoids is given, starting with pulses of intravenous methylprednisolone and tapering the dose to oral prednisone afterwards. Typically, the regimen is prednisone 1 mg/kg/day orally followed by a rapid taper over 3–4 weeks once a normal platelet count has been achieved. In combination with the above measures, rituximab (anti-CD20 antibody) is also indicated in patients with presumptive and/or confirmed diagnosis of acquired TTP, since available data suggest that it has a beneficial effect in preventing disease relapse, and possibly in hastening the response to therapy. However, along with the sparse data, the need for parenteral administration and drug cost are conditioning factors that have to be taken into consideration when rituximab is prescribed [17, 77].

Recently, caplacizumab, a humanized monoclonal anti-VWF antibody with subcutaneous route of administration, has been approved by the Food and Drug Administration (FDA) (February 2019) for acquired TTP treatment. Caplacizumab targets the A1 domain of VWF and blocks its interaction with platelet glycoprotein 1b, thereby preventing the formation of microvascular thrombosis in small arterioles and capillaries. In clinical practice, caplacizumab is reserved for patients who present with severe features of TTP. Although the benefit of caplacizumab is greatest when given earlier in the course of disease, it should be given under the guidance of an experienced clinician since it is associated with side effects (mainly, risk of bleeding) and significant cost. However, because it does not affect the underlying cause of acquired TTP, the above-explained co-treatments to remove the antibodies are required along with caplacizumab [78]. In this regard, it has to be noted that the sequencing of adjunctive therapies are yet to be characterized, since there are limited data from prospective, randomized trials to direct the most appropriate use of these treatments.

**STEC-HUS.** Supportive therapy based on hydration, fluid and electrolyte management, antihypertensive drugs and renal replacement therapy (if needed), is the treatment of choice for STEC-HUS [79].

**aHUS.** Treatment with complement blockade (Anti-C5) has significantly improved clinical outcomes in this ultra-rare disease, in both paediatric [80, 81] and adult patients [82–84]. In this regard, treatment with eculizumab was approved by the FDA in 2011, and actually remains the first-line treatment for aHUS patients. It has to be emphasized that early eculizumab use is associated not only with high haematological response, but also with organ dysfunction recovery (especially kidney function) [85, 86]. Ravulizumab, a long-acting complement inhibitor, was subsequently developed, thereby requiring less frequent infusions than eculizumab, and demonstrating also rapid haematological and renal improvement. It received regulatory approval for aHUS in 2019 [79]. All patients treated with C5 inhibitors must be immunized with meningococcal vaccines (both ACYW135 and serogroup B) at least 2 weeks prior to administering the first dose of eculizumab. For patients who must receive the treatment emergently, prophylactic antibiotics to prevent meningitis may be administered until the vaccinations take effect.

When complement blockers are not available, TPE must be early started after aHUS diagnosis, until anti-C5 treatment could be administered. Also, if aHUS is mediated by auto-antibodies against CFH, immunosuppressants and TPE should be considered, in conjunction with the above-explained therapies.

### Secondary TMA forms

In secondary TMA forms, the treatment of choice should aim to correct the underlying disease together with supportive care.

It has been suggested there is a possible benefit of TPE for some secondary TMA forms, including those related with auto-immune conditions, HCT, pregnancy and drug-induced TMAs, all of them having a potential immune-mediated endothelial damage as a common pathologic mechanism. However, limited published information exists, and in most cases, American Society for Apheresis guidelines categorizes the use of TPE as a Category III indication; that is, the role of TPE is uncertain, and decision-making should be individualized [87].

Importantly, there is increasing evidence that secondary TMA forms could present complement system dysregulation, leading to an endothelial damage. Although experience is scarce, cases of secondary TMA of distinct aetiology (including TMAs secondary to pregnancy, drugs, transplant, humoral rejection and systemic diseases) refractory to the conventional treatment with good response to eculizumab have been reported [10, 47, 61, 62, 88–90]. In these settings, demonstration of terminal complement overactivation (C5b-9 monitoring) could be a powerful tool in the decision-making process regarding the potential use of complement inhibitors (Figure 2).

## CONCLUSIONS

Major advances in the pathophysiological knowledge of entities such as TTP and aHUS have allowed a clear improvement in patient prognosis. However, in many other causes of TMA, the underlying pathogenic process is still unknown. Furthermore, despite progress achieved in aHUS, its diagnosis continues to be by exclusion, sometimes delaying the start of high-impact treatment. To improve the management of patients with TMA, we recommend a clinical algorithm, with special emphasis on

terminal complement pathway monitoring at the beginning of the diagnostic process. This review—as a practical guide in the diagnostic process of TMA—will evolve with the development of new biomarkers and treatments, but its application will allow a better understanding of the role of complement in the pathogenesis of these serious systemic processes with potential therapeutic interventions.

## ACKNOWLEDGEMENTS

Fundació Miarnau (Spain); Shook Studio for figures design; Jazz Pharmaceuticals Plc (IST-16-10355, to M.D.R. and E.C.); and the German José Carreras Leukaemia Foundation (03R/2019 to M.D.R. and E.C.), grant PI19/00888 (to M.D.-R.)

## FUNDING

This study has been partially funded by Fundació Miarnau (Spain), Jazz Pharmaceuticals Plc (IST-16-10355, E.C. and M.D.R.); and the German José Carreras Leukaemia Foundation (03R/2019 to E.C. and M.D.R.), Instituto de Salud Carlos III through the Project PIE15/00027 and Generalitat de Catalunya (2017-SGR675, CERCA).

## CONFLICT OF INTEREST STATEMENT

M.B. reports advisory boards and symposium speaker honoraria from Alexion Pharmaceuticals; E.C., and M.D.R. received research grant and symposium speaker fees from Jazz Pharmaceutical and M.P. received symposium speaker fees from Jazz Pharmaceutical.

## REFERENCES

- Brocklebank V, Wood KM, Kavanagh D. Thrombotic microangiopathy and the kidney. *Clin J Am Soc Nephrol* 2018; 13: 300–317
- Campistol JM, Arias M, Ariceta G et al. An update for atypical haemolytic uraemic syndrome: diagnosis and treatment. A consensus document. *Nefrologia* 2015; 35: 421–447
- George JN, Nester CM. Syndromes of thrombotic microangiopathy. *N Engl J Med* 2014; 371: 654–666
- Shatzel JJ, Taylor JA. Syndromes of thrombotic microangiopathy. *Med Clin North Am* 2017; 101: 395–415
- Noris M, Mescia F, Remuzzi G. STEC-HUS, atypical HUS and TTP are all diseases of complement activation. *Nat Rev Nephrol* 2012; 8: 622–633
- Buelli S, Zoja C, Remuzzi G, Morigi M. Complement activation contributes to the pathophysiology of Shiga Toxin-associated hemolytic uremic syndrome. *Microorganisms* 2019; 7: 15
- Dhakal P, Bhatt VR. Is complement blockade an acceptable therapeutic strategy for hematopoietic cell transplant-associated thrombotic microangiopathy? *Bone Marrow Transplant* 2017; 52: 352–356
- Fakhouri F. Pregnancy-related thrombotic microangiopathies: clues from complement biology. *Transfus Apher Sci* 2016; 54: 199–202
- Zheng L, Zhang D, Cao W et al. Synergistic effects of ADAMTS13 deficiency and complement activation in pathogenesis of thrombotic microangiopathy. *Blood* 2019; 134: 1095–1105
- Kello N, Khoury L, El Marder G et al. Secondary thrombotic microangiopathy in systemic lupus erythematosus and antiphospholipid syndrome, the role of complement and use of eculizumab: case series and review of literature. *Semin Arthritis Rheum* 2019; 49: 74–83
- Frazer-Abel A. The effect on the immunology laboratory of the expansion in complement therapeutics. *J Immunol Methods* 2018; 461: 30–36
- Mastellos DC, Ricklin D, Lambris JD. Clinical promise of next-generation complement therapeutics. *Nat Rev Drug Discov* 2019; 18: 707–729
- Arnold DM, Patriquin CJ, Nazy I. Thrombotic microangiopathies: a general approach to diagnosis and management. *CMAJ* 2017; 189: E153–E159
- Moake JL. Thrombotic microangiopathies. *N Engl J Med* 2002; 347: 589–600
- Scully M, Cataland S, Coppo P et al.; the International Working Group for Thrombotic Thrombocytopenic Purpura. Consensus on the standardization of terminology in thrombotic thrombocytopenic purpura and related thrombotic microangiopathies. *J Thromb Haemost* 2017; 15: 312–322
- Bendapudi PK, Hurwitz S, Fry A et al. Derivation and external validation of the PLASMIC score for rapid assessment of adults with thrombotic microangiopathies: a cohort study. *Lancet Haematol* 2017; 157–164
- Scully M, Hunt BJ, Benjamin S et al.; on behalf of British Committee for Standards in Haematology. Guidelines on the diagnosis and management of thrombotic thrombocytopenic purpura and other thrombotic microangiopathies. *Br J Haematol* 2012; 158: 323–335
- Jokiranta TH. Atypical HUS. *Blood* 2017; 129: 2847–2856
- Teixeira CM, Silva HT, De Moura LAR et al. Clinical and pathological features of thrombotic microangiopathy influencing longterm kidney transplant outcomes. *PLoS One* 2020; 15: e0227445
- Magro CM, Momtahn S, Mulvey JJ et al. Role of the skin biopsy in the diagnosis of atypical hemolytic uremic syndrome. *Am J Dermatopathol* 2015; 37: 349–359
- El-Bietar J, Warren M, Dandoy C et al. Histologic features of intestinal thrombotic microangiopathy in pediatric and young adult patients after hematopoietic stem cell transplantation. *Biol Blood Marrow Transplant* 2015; 21: 1994–2001
- Nishioka GJ, Chilcoat CC, Aufdemorte TB et al. The gingival biopsy in the diagnosis of thrombotic thrombocytopenic purpura. *Oral Surg Oral Med Oral Pathol Oral Radiol* 1988; 65: 580–585
- Goodship THJ, Cook HT, Fakhouri F et al. Atypical hemolytic uremic syndrome and C3 glomerulopathy: conclusions from a “Kidney Disease: Improving Global Outcomes” (KDIGO) Controversies Conference. *Kidney Int* 2017; 91: 539–551
- Lusco MA, Fogo AB, Najafian B et al. AJKD atlas of renal pathology: thrombotic microangiopathy. *Am J Kidney Dis* 2016; 68: 33–34
- Chang A. Thrombotic microangiopathy and the kidney. *Diagnostic Histopathol* 2017; 23: 101–108
- Ernandes Neto M, Soler L, de M, Gallindo Vasconcelos HV et al. Histopathological features of thrombotic microangiopathies in renal biopsies. *J Nephropathol* 2019; 8: 27
- Sánchez-Luceros A, Farías C, Amaral M et al. von Willebrand factor-cleaving protease (ADAMTS13) activity in normal non-pregnant women, pregnant and post-delivery women. *Thromb Haemost* 2004; 92: 1320–1326

28. Ono T, Mimuro J, Madoiwa S et al. Severe secondary deficiency of von Willebrand factor–cleaving protease (ADAMTS13) in patients with sepsis-induced disseminated intravascular coagulation: its correlation with development of renal failure. *Blood* 2006; 107: 528–534
29. Mannucci PM, Canciani MT, Forza I et al. Changes in health and disease of the metalloprotease that cleaves von Willebrand factor. *Blood* 2001; 98: 2730–2735
30. Martin-Rodriguez S, Reverter JC, Tàssies D et al. Reduced ADAMTS13 activity is associated with thrombotic risk in systemic lupus erythematosus. *Lupus* 2015; 24: 1143–1149
31. Feng S, Eyler SJ, Zhang Y et al. Partial ADAMTS13 deficiency in atypical hemolytic uremic syndrome. *Blood* 2013; 122: 1487–1493
32. Kokame K, Nobe Y, Kokubo Y et al. FRETS-VWF73, a first fluorogenic substrate for ADAMTS13 assay. *Br J Haematol* 2005; 129: 93–100
33. Saha M, McDaniel JK, Zheng XL. Thrombotic thrombocytopenic purpura: pathogenesis, diagnosis and potential novel therapeutics. *J Thromb Haemost* 2017; 15: 1889–1900
34. Terrell DR, Williams LA, Vesely SK et al. The incidence of thrombotic thrombocytopenic purpura-hemolytic uremic syndrome: all patients, idiopathic patients, and patients with severe ADAMTS-13 deficiency. *J Thromb Haemost* 2005; 3: 1432–1436
35. Righini M, Le Gal GD, Lucia S et al. Relation between ADAMTS13 activity and ADAMTS13 antigen levels in healthy donors and patients with thrombotic microangiopathies (TMA). *Thromb Haemost* 2006; 95: 715–719
36. Camilleri RS, Scully M, Thomas M et al. A phenotype-genotype correlation of ADAMTS13 mutations in congenital thrombotic thrombocytopenic purpura patients treated in the United Kingdom. *J Thromb Haemost* 2012; 10: 1792–1801
37. Mayer CL, Leibowitz CS, Kurosawa S et al. Shiga toxins and the pathophysiology of hemolytic uremic syndrome in humans and animals. *Toxins* 2012; 4: 1261–1287
38. Parsons BD, Zelyas N, Berenger BM et al. Detection, characterization, and typing of Shiga toxin-producing *Escherichia coli*. *Front Microbiol* 2016; 7: 478
39. Song D, Wu L, Wang F et al. The spectrum of renal thrombotic microangiopathy in lupus nephritis. *Arthritis Res Ther* 2013; 15: R12
40. Nester CM, Barbour T, de Cordoba SR et al. Atypical aHUS: state of the art. *Mol Immunol* 2015; 67: 31–42
41. Infections S, Thrombotic M, Purpura T. Systemic infections mimicking thrombotic. *Am J Hematol* 2012; 86: 743–751
42. Tranquilli AL, Dekker G, Magee L et al. The classification, diagnosis and management of the hypertensive disorders of pregnancy: a revised statement from the ISSHP. *Pregnancy Hypertens* 2014; 4: 97–104
43. Dashe J. The long-term consequences of thrombotic microangiopathy (thrombotic thrombocytopenic purpura and hemolytic uremic syndrome) in pregnancy. *Obstet Gynecol* 1998; 91: 662–668
44. Noris M, Remuzzi G. Atypical hemolytic–uremic syndrome. *N Engl J Med* 2009; 361: 1676–1687
45. Fakhouri F, Roumenina L, Provot F et al. Pregnancy-associated hemolytic uremic syndrome revisited in the era of complement gene mutations. *J Am Soc Nephrol* 2010; 21: 859–867
46. Huerta A, Arjona E, Portoles J et al. A retrospective study of pregnancy-associated atypical hemolytic uremic syndrome. *Kidney Int* 2018; 93: 450–459
47. Gloude NJ, Khandelwal P, Luebbering N et al. Circulating dsDNA, endothelial injury, and complement activation in thrombotic microangiopathy and GVHD. *Blood* 2017; 130: 1259–1266
48. Ravindran M, Khan MA, Palaniyar N. Neutrophil extracellular trap formation: physiology, pathology, and pharmacology. *Biomolecules* 2019; 9: 365
49. Yuen J, Pluthero FG, Doua DN et al. NETosing neutrophils activate complement both on their own NETs and bacteria via alternative and non-alternative pathways. *Front Immunol* 2016; 7: 137
50. Baumgartner MR, Hörster F, Dionisi-Vici C et al. Proposed guidelines for the diagnosis and management of methylmalonic and propionic acidemia. *Orphanet J Rare Dis* 2014; 9: 1–36
51. George JN. Systemic malignancies as a cause of unexpected microangiopathic hemolytic anemia and thrombocytopenia. *Oncology* 2011; 25: 908–914
52. Al-Nouri ZL, Reese JA, Terrell DR et al. Drug-induced thrombotic microangiopathy: a systematic review of published reports. *Blood* 2015; 125: 616–618
53. Yoshida Y, Kato H, Ikeda Y et al. Pathogenesis of atypical hemolytic uremic syndrome. *J Atheroscler Thromb* 2019; 26: 99–110
54. Noris M, Galbusera M, Gastoldi S et al. Dynamics of complement activation in aHUS and how to monitor eculizumab therapy. *Blood* 2014; 124: 1715–1726
55. Timmermans SAMEG, Abdul-Hamid MA, Potjewijd J et al.; on behalf of the Limburg Renal Registry. C5b9 Formation on endothelial cells reflects complement defects among patients with renal thrombotic microangiopathy and severe hypertension. *J Am Soc Nephrol* 2018; 29: 2234–2243
56. Galbusera M, Noris M, Gastoldi S et al. An ex vivo test of complement activation on endothelium for individualized eculizumab therapy in hemolytic uremic syndrome. *Am J Kidney Dis* 2019; 74: 56–72
57. Palomo M, Blasco M, Molina P et al. Complement activation and thrombotic microangiopathies. *Clin J Am Soc Nephrol* 2019; 14: 1719–1732
58. Bu F, Meyer NC, Zhang Y et al. Soluble c5b-9 as a biomarker for complement activation in atypical hemolytic uremic syndrome. *Am J Kidney Dis* 2015; 65: 968–969
59. Volokhina EB, Westra D, van der Velden TJAM et al. Complement activation patterns in atypical haemolytic uraemic syndrome during acute phase and in remission. *Clin Exp Immunol* 2015; 181: 306–313
60. Cataland SR, Holers VM, Geyer S et al. Biomarkers of terminal complement activation confirm the diagnosis of aHUS and differentiate aHUS from TTP. *Blood* 2014; 123: 3733–3738
61. Caverio T, Rabasco C, López A et al. Eculizumab in secondary atypical haemolytic uraemic syndrome. *Nephrol Dial Transplant* 2017; 32: 466–474
62. Román E, Mendizábal S, Jarque I et al. Secondary thrombotic microangiopathy and eculizumab: a reasonable therapeutic option. *Nefrologia* 2017; 37: 478–491
63. Weitz IC. Thrombotic microangiopathy in cancer. *Semin Thromb Hemost* 2019; 45: 348–335
64. Ades EW, Candal FJ, Swerlick RA et al. HMEC-1: establishment of an immortalized human microvascular endothelial cell line. *J Invest Dermatol* 1992; 99: 683–690
65. Amara U, Flierl MA, Rittirsch D et al. Molecular intercommunication between the complement and coagulation systems. *J Immunol* 2010; 185: 5628–5636
66. Costabile M. Measuring the 50% haemolytic complement (CH50) activity of serum. *J Vis Exp* 2010; 37: 1923



67. Angioi A, Fervenza FC, Sethi S et al. Diagnosis of complement alternative pathway disorders. *Kidney Int* 2016; 89: 278–288
68. Servais G, Walmagh J, Duchateau J. Simple quantitative haemolytic microassay for determination of complement alternative pathway activation (AP50). *J Immunol Methods* 1991; 140: 93–100
69. Gavrilaki E, Yuan X, Ye Z et al. Modified Ham test for atypical hemolytic uremic syndrome. *Blood* 2015; 125: 3637–3646
70. Mollnes TE, Jokiranta TS, Truedsson L et al. Complement analysis in the 21st century. *Mol Immunol* 2007; 44: 3838–3884
71. Shih AR, Murali MR. Laboratory tests for disorders of complement and complement regulatory proteins. *Am J Hematol* 2015; 90: 1180–1186
72. Rodríguez de Córdoba S, Hidalgo M, Pinto S et al. Genetics of atypical hemolytic uremic syndrome (aHUS). *Semin Thromb Hemost* 2014; 40: 422–430
73. Westra D, Volokhina EB, van der Molen RG et al. Serological and genetic complement alterations in infection-induced and complement-mediated hemolytic uremic syndrome. *Pediatr Nephrol* 2017; 32: 297–309
74. Jodele S, Licht C, Goebel J et al. Abnormalities in the alternative pathway of complement in children with hematopoietic stem cell transplant-associated thrombotic microangiopathy. *Blood* 2013; 122: 2003–2007
75. Salmon JE, Heuser C, Triebwasser M et al. Mutations in complement regulatory proteins predispose to preeclampsia: a genetic analysis of the PROMISSE cohort. *PLoS Med* 2011; 8: e100103
76. Vaught AJ, Braunstein EM, Jasem J et al. Germline mutations in the alternative pathway of complement predispose to HELLP syndrome. *JCI Insight* 2018; 3: e99128
77. Zheng XL, Vesely SK, Cataland SR et al. ISTH guidelines for treatment of thrombotic thrombocytopenic purpura. *J Thromb Haemost* 2020; 00: 1–7
78. Chung C. New therapeutic targets and treatment options for thrombotic microangiopathy: caplacizumab and ravulizumab. *Ann Pharmacother* 2020; 00:1–14
79. Loirat C, Fakhouri F, Ariceta G et al.; for HUS International. An international consensus approach to the management of atypical hemolytic uremic syndrome in children. *Pediatr Nephrol* 2016; 31: 15–39
80. Giordano M, Castellano G, Messina G et al. Preservation of renal function in atypical hemolytic uremic syndrome by eculizumab: a case report. *Pediatrics* 2012; 130: e1385–e1388
81. Greenbaum LA, Fila M, Ardissino G et al. Eculizumab is a safe and effective treatment in pediatric patients with atypical hemolytic uremic syndrome. *Kidney Int* 2016; 89: 701–711
82. Fakhouri F, Hourmant M, Campistol JM et al. Terminal complement inhibitor eculizumab in adult patients with atypical hemolytic uremic syndrome: a single-arm, open-label trial. *Am J Kidney Dis* 2016; 68: 84–93
83. Legendre CM, Licht C, Muus P et al. Terminal complement inhibitor eculizumab in atypical hemolytic-uremic syndrome. *N Engl J Med* 2013; 368: 2169–2181
84. Licht C, Greenbaum LA, Muus P et al. Efficacy and safety of eculizumab in atypical hemolytic uremic syndrome from 2-year extensions of phase 2 studies. *Kidney Int* 2015; 87: 1061–1073
85. Walle J, Vande Delmas Y, Ardissino G et al. Improved renal recovery in patients with atypical hemolytic uremic syndrome following rapid initiation of eculizumab treatment. *J Nephrol* 2017; 30: 127–134
86. Menne J, Delmas Y, Fakhouri F et al. Outcomes in patients with atypical hemolytic uremic syndrome treated with eculizumab in a long-term observational study. *BMC Nephrol* 2019; 20: 125
87. Winters JL. Plasma exchange in thrombotic microangiopathies (TMAs) other than thrombotic thrombocytopenic purpura (TTP). *Hematology* 2017; 2017: 632–638
88. Ardissino GW, Ossola M, Baffero GM et al. M. Eculizumab for atypical hemolytic uremic syndrome in pregnancy. *Obstet Gynecol* 2013; 122: 487–489
89. Faguer S, Huart A, Frémeaux-Bacchi V et al. Eculizumab and drug-induced haemolytic-uraemic syndrome. *Clin Kidney J* 2013; 6: 484–485
90. Rosenthal J. Hematopoietic cell transplantation-associated thrombotic microangiopathy: a review of pathophysiology, diagnosis, and treatment. *J Blood Med* 2016; 7: 181–186