



# MRI Gadolinium-Based Contrast Media: Meeting Radiological, Clinical, and Environmental Needs

Martin Bendszus, MD,<sup>1</sup> Andrea Laghi, MD,<sup>2</sup>  Josep Munuera, MD, PhD,<sup>3,4</sup> Lawrence N. Tanenbaum, MD,<sup>5</sup> Bachir Taouli, MD,<sup>6</sup>  and Harriet C. Thoeny, MD<sup>7,8\*</sup>

Gadolinium-based contrast agents (GBCAs) are routinely used in magnetic resonance imaging (MRI). They are essential for choosing the most appropriate medical or surgical strategy for patients with serious pathologies, particularly in oncologic, inflammatory, and cardiovascular diseases. However, GBCAs have been associated with an increased risk of nephrogenic systemic fibrosis in patients with renal failure, as well as the possibility of deposition in the brain, bones, and other organs, even in patients with normal renal function. Research is underway to reduce the quantity of gadolinium injected, without compromising image quality and diagnosis. The next generation of GBCAs will enable a reduction in the gadolinium dose administered. Gadopiclenol is the first of this new generation of GBCAs, with high relaxivity, thus having the potential to reduce the gadolinium dose while maintaining good in vivo stability due to its macrocyclic structure. High-stability and high-relaxivity GBCAs will be one of the solutions for reducing the dose of gadolinium to be administered in clinical practice, while the development of new technologies, including optimization of MRI acquisitions, new contrast mechanisms, and artificial intelligence may help reduce the need for GBCAs. Future solutions may involve a combination of next-generation GBCAs and image-processing techniques to optimize diagnosis and treatment planning while minimizing exposure to gadolinium.

**Level of Evidence:** 5

**Technical Efficacy:** Stage 3

J. MAGN. RESON. IMAGING 2024;60:1774–1785.

The main contrast media for enhancing magnetic resonance imaging (MRI) are the gadolinium-based contrast agents (GBCAs). They have become essential since their introduction in the late 1980s, due to their added value in clinical practice and overall good safety profile.<sup>1–4</sup> Following the introduction of gadobutrol in 2003, no other non-specific GBCAs were introduced to the market until the recent arrival of a new generation of high relaxivity GBCA in 2022.<sup>5</sup> This paper comprehensively addresses the current challenges associated with the use of GBCAs, encompassing safety concerns, guidelines updates, and the impact related to environmental contamination with GBCAs. Furthermore, it delves into the

latest developments in next-generation GBCAs and their clinical potential. Additionally, the paper explores cutting-edge MRI techniques and the application of artificial intelligence to optimize contrast enhancement, ultimately contributing to enhanced patient care and safety.

## Challenges With Current Gadolinium Use *Gadolinium-Based Contrast Agents in Clinical Practice*

Since their initial approval, more than 700 million doses of GBCAs have been administered worldwide.<sup>6</sup> In a recent survey of GBCA use in Europe, clinicians reported that image

View this article online at [wileyonlinelibrary.com](http://wileyonlinelibrary.com). DOI: 10.1002/jmri.29181

Received Aug 22, 2023, Accepted for publication Nov 29, 2023.

\*Address reprint requests to: H.C.T., Chem. des Pensionnats 2/6, 1752 Villars-sur-Glâne, Fribourg, Switzerland. E-mail: [harriet.thoeny@h-fr.ch](mailto:harriet.thoeny@h-fr.ch)

From the <sup>1</sup>Department of Neuroradiology, University Hospital Heidelberg, Heidelberg, Germany; <sup>2</sup>Department of Medical Surgical Sciences and Translational Medicine, Faculty of Medicine and Psychology, Sapienza University of Rome, Sant'Andrea University Hospital, Rome, Italy; <sup>3</sup>Advanced Medical Imaging, Artificial Intelligence, and Imaging-Guided Therapy Research Group, Institut de Recerca Sant Pau - Centre CERCA, Barcelona, Spain; <sup>4</sup>Diagnostic Imaging Department, Hospital de la Santa Creu i Sant Pau, Barcelona, Spain; <sup>5</sup>RadNet, Inc., New York, New York, USA; <sup>6</sup>Department of Diagnostic, Molecular and Interventional Radiology, Icahn School of Medicine at Mount Sinai, New York, New York, USA; <sup>7</sup>Department of Diagnostic and Interventional Radiology, Fribourg Cantonal Hospital, Fribourg, Switzerland; and <sup>8</sup>Faculty of Medicine, University of Fribourg, Fribourg, Switzerland

This is an open access article under the terms of the [Creative Commons Attribution](https://creativecommons.org/licenses/by/4.0/) License, which permits use, distribution and reproduction in any medium, provided the original work is properly cited.

quality with GBCAs was “good” or “excellent” for 96% of patients, increasing diagnostic confidence in 96% and resulting in a change in radiological diagnosis in 74% of cases.<sup>7</sup> MRI use is generally on the rise in high income countries due to worldwide population aging with an accompanying growing need for imaging.<sup>8,9</sup> An increase from 56 MRI scans per 1000 people in the year 2000, to 128 per 1000 people in 2019 was reported in the USA, and from 73 per 1000 in 2005 to 145 per 1000 in 2018 in Germany.<sup>8</sup> Therefore, the use of GBCAs is also expected to increase in the future.

### **Mechanisms and Parameters Influencing the Action of GBCAs**

The lanthanide, gadolinium (Gd) has a highly paramagnetic effect, even bound in a stable complex as a result of its seven unpaired electrons in the 4f subshell.<sup>1</sup> When a GBCA is intravenously injected into a patient, it is distributed into the extracellular compartment. The GBCA creates a local magnetic field disturbance, shortening the  $T_1$  relaxation time of water protons in surrounding tissue. As a result, the tissue appears brighter in the MRI images, enhancing the contrast between different structures. This mechanism allows to detect and visualize abnormalities, lesions, or blood vessels more clearly.<sup>1</sup>

Free gadolinium is highly toxic. It has a similar ionic radius as  $Ca^{2+}$  and thus inhibits calcium-dependent processes and may have other deleterious mechanisms. To minimize its toxicity, the  $Gd^{3+}$  ion is chelated with a polyaminopolycarboxylate ligand, which is either linear in structure, or macrocyclic.<sup>1,4</sup> These ligands affect the physicochemical properties of the molecule, notably its relaxivity, stability, water solubility, and toxicity.<sup>10</sup> The relative stabilities of the different complexes are characterized by their thermodynamic stability, which represents the strength necessary to maintain  $Gd^{3+}$  within the complex, and their kinetic inertness, which defines the rate of  $Gd^{3+}$  release under certain conditions.<sup>4</sup> In vitro, linear GBCAs have a much lower kinetic inertness than macrocyclic GBCAs.<sup>11</sup> The chemical structure of the chelate in the GBCA complex also affects the number of sites accessible for water molecules to bind to the  $Gd^{3+}$  ion, influencing the agent's relaxivity.<sup>1</sup> Generally, the rotational dynamics of a GBCA can be improved by altering the molecule weight and protein binding capability. The hydration number,  $q$ , is the number of coordinated inner sphere water molecules and is a key contributor to the relaxivity of the complex.<sup>12</sup> Increasing the hydration number is accompanied by a proportional increase in the relaxivity.<sup>12–14</sup>

### **Safety Concerns With GBCAs and Changes in Market Approval Status**

The incidence of acute adverse reactions is very low for commonly used GBCAs.<sup>7,15,16</sup> In a cohort of 150,000 European patients undergoing cardiac MRI, with 94% receiving a GBCA (over 99% were macrocyclic by 2018), adverse

events were of the order of 0.12% for mild, 0.21% for moderate, and 0.03% for severe adverse events.<sup>16</sup> Albeit mostly out of use by 2018 in Europe, linear GBCAs were associated with a significantly higher risk of acute adverse events than macrocyclic GBCAs on multivariate analysis (macrocyclic vs. linear GBCA: multivariable odds ratio, 0.634; 95% confidence interval: 0.452, 0.888;  $P = 0.008$ ).<sup>16</sup> The incidence of adverse events was of similar order in other studies.<sup>7,15</sup>

Although GBCAs are considered generally safe, in 2006 reports of nephrogenic systemic fibrosis (NSF) occurring in patients with severe renal failure who had undergone contrast-enhanced MRI prompted the health authorities to reconsider the risks.<sup>17</sup> The risk of NSF also appeared to be increased with higher than recommended or repeated doses of GBCAs, particularly those with a linear ligand.<sup>4</sup> The immense majority of NSF cases have been reported after use of linear GBCAs. The US Food and Drug Administration (FDA) thus revised the GBCA labeling to mention the risk of NSF for patients with severe renal insufficiency who receive GBCAs,<sup>18</sup> followed by a requirement to screen patients for the presence of acute kidney injury or chronic severe renal disease before administration.<sup>4</sup> In 2009, the European Medicines Agency (EMA) classified GBCAs by associated risk of NSF, and contra-indicated high-risk GBCAs (gadodiamide, gadopentetic acid/gadopentetate dimeglumine, and gadoversetamide) for patients with severe renal impairment, and advised caution for at-risk patients receiving medium-risk (gadoxetic acid/gadoxetate disodium, gadobenic acid/gadobenate dimeglumine), and low-risk agents (gadoteric acid/gadoterate meglumine, gadoteridol, and gadobutrol).<sup>19</sup>

The exact mechanism of NSF causation from GBCA use is still unknown. It is thought that the  $Gd^{3+}$  ions dissociate from the GBCA complex in patients with significantly impaired renal function due to the prolonged clearance times of the GBCAs and because of the low stability of linear GBCAs.<sup>20,21</sup> The unbound gadolinium then binds with an anion, phosphate for example, and the resulting insoluble precipitate is deposited in various tissues.<sup>20,21</sup> If the propensity for gadolinium dissociation is definitively linked to the occurrence of NSF, this may at least partially explain why the different GBCAs, which have different in vitro and in vivo stabilities, have different degrees of risk of developing NSF in at-risk patients.<sup>20,21</sup>

In 2013, the safety of GBCAs was again called into question with the publication of a study showing that some patients who have previously undergone contrast-enhanced MRI with GBCA continued to show hyperintensity of distinct brain structures (the dentate nucleus and thalamus) on subsequent non-enhanced MRI, consistent with gadolinium deposition.<sup>22</sup> There was a higher likelihood for gadolinium deposition with linear compounds compared with macrocyclic GBCAs.<sup>22,23</sup> The FDA thus issued an updated notice in 2017, that although there may be some gadolinium retention in the brain and other body tissues, they found no evidence that it was clinically harmful and thus there were no further restrictions in GBCA use that was

warranted in the US. However, they recommended minimizing repeated GBCA imaging wherever possible, particularly for frequently repeated MRI studies, but specified that necessary GBCA-enhanced MRI scans should not be avoided or deferred.<sup>24</sup> In contrast to the US, the European Commission opted to suspend the marketing authorizations of the linear non-specific GBCAs gadodiamide and gadoversetamide, and to restrict the authorization of gadobenic acid to liver imaging only and gadopentetate dimeglumine for intra-articular administration in diluted form only. Authorizations of the liver-specific GBCA gadoxetic acid as well as those of the macrocyclic GBCAs gadoteric acid, gadobutrol, and gadoteridol were maintained.<sup>4,25</sup> The EMA stated that macrocyclic GBCAs can continue to be used in their current indications, but at the lowest indicated doses for sufficient image enhancement and only when unenhanced scans are not appropriate.<sup>18,26</sup>

More recently, gadolinium deposition has also been demonstrated in the skeletal bones of healthy patients following a single GBCA injection.<sup>27</sup> Although there is currently no evidence to show that gadolinium deposition in healthy subjects is associated with adverse clinical outcomes,<sup>28</sup> gadolinium deposition may pose a risk as later release of gadolinium from the bone is possible and could result from increased bone mineral loss in cases of osteoporosis, which in turn could lead to delayed toxic effects.<sup>29,30</sup> Overall, based on the available evidence, macrocyclic GBCAs are considered to have a very good safety profile, where the benefits exceed the risks.<sup>14</sup>

### **GBCAs in Current Practice/Guidelines**

Both the American College of Radiology (ACR) and the European Society of Urogenital Radiology (ESUR) guidelines highlight the indispensable role of GBCAs in providing vital, potentially life-saving medical information. The guidelines emphasize the critical need to carefully balance the potential risks of GBCA usage against the substantial dangers of undergoing a contrast-enhanced imaging procedure in such cases. Furthermore, for all patients, irrespective of their risk profile, the principles set forth in the guidelines mandate the usage of the smallest feasible quantity of contrast medium that can yield a diagnostically meaningful result.<sup>20,21,31</sup>

The use of GBCAs must take into consideration a risk of dose-dependent gadolinium deposition in the brain, even in patients with no evidence of kidney or liver disease.<sup>20,21</sup> There is no evidence to suggest that these deposits are associated with neurotoxicity, even when administering GBCAs that have shown the highest rates of gadolinium deposition.<sup>20,21</sup> The ACR thus recommends weighing the clinical benefit of the diagnostic information or treatment result that MRI or magnetic resonance angiography (MRA) may provide against the unknown potential risk of gadolinium deposition in the brain and elsewhere for each individual patient. Particular attention should be paid to pediatric and other patients

who may receive many GBCA-enhanced MRI studies over the course of their lifetime.<sup>20,21</sup>

When a decision is taken to administer a GBCA to an individual patient, multiple factors, such as diagnostic added value, relaxivity, rate of adverse reactions, dosing/concentration, and propensity to deposit gadolinium should be considered when selecting the GBCA.<sup>20,21</sup> Limiting the use of GBCAs in at-risk patients to macrocyclics has been shown to markedly reduce the number of new cases of NSF.<sup>32</sup> In cases where multiple doses of a GBCA are required over a short time frame, in patients not at risk of NSF, there is no contraindication if the examinations are deemed necessary. In patients at risk of NSF, the ACR recommends using the group II agents, namely gadobenate dimeglumine, gadobutrol, gadoterate meglumine, gadoteridol, or gadopidrenol.<sup>20</sup> For pediatric patients, the ACR recommends following the same guidelines as for adults for identification of at-risk patients and the administration of GBCAs in those with impaired renal function.<sup>33</sup> In both children and adults the ACR recommends avoiding GBCAs in patients with acute kidney injury or chronic kidney disease with an eGFR <30 mL/min/1.73 m<sup>2</sup>.<sup>20,21</sup> Given the scarcity of evidence, caution should be applied when using GBCAs in pre-term neonates and infants due to renal immaturity. Ultimately, as with adults, the benefits of GBCAs should be weighed against the potential risks.<sup>20</sup>

The ESUR guidelines follow the EMA decision that GBCAs associated with a high and medium risk of NSF (all linear GBCAs) should be reserved to specific indications for which the benefit/risk balance is still considered favorable (gadopentetate dimeglumine for arthrography and gadobenate dimeglumine and gadoxetate disodium for hepatobiliary imaging exclusively). The ESUR guidelines recommend that agents associated with a low risk of NSF (gadobutrol, gadoterate meglumine, gadoteridol) should be used with caution in patients with GFR < 30 mL/min, with at least 7 days between injections.<sup>31</sup>

These recommendations have been considered in new guidelines for specific diseases that necessitate repeat use of contrast-enhanced MRI.<sup>34</sup> For instance, in multiple sclerosis, in order to minimize the amount of gadolinium injected, the French Multiple Sclerosis Network guidelines stipulate that patients should undergo a macrocyclic GBCA-enhanced scan at the following time points: time of diagnosis; when a new disease-modifying treatment is introduced; 6 months after the baseline exam; and when previous scans are unavailable for comparison.<sup>35</sup> GBCA-enhanced MRI can be performed as an option in case of relapse or suspicion of intercurrent disease, but other follow-up MRIs do not require contrast enhancement.<sup>35</sup> The additional diagnostic value of GBCA in routine follow-up by MRI in patients with MS is considered low.<sup>36</sup>

### **Environmental Accumulation of Gadolinium**

Another major reason for healthcare systems in general to seek to reduce the amounts of GBCAs administered is

because of concerns about accumulating gadolinium being released into water systems after urinary excretion by patients.<sup>37</sup> The increasing use of GBCAs for MRI has led to widespread contamination of freshwater and drinking water systems.<sup>38</sup> Moreover, the treatment of wastewater with UV may contribute to the degradation of GBCAs, increasing the risks of adverse health consequences.<sup>38</sup> The total amounts of gadolinium in wastewater systems may be considerable, with some estimates from a French study suggesting that approximately 3.24 kg of gadolinium may be injected per MRI scanner per year.<sup>37</sup> The annual emission of gadolinium has been estimated of 19 tons in the EU and 21 tons in the US.<sup>38</sup> Gadolinium is found in excessive amounts closer to larger cities and hospitals performing MRI.<sup>38</sup> These amounts are likely to continue to increase in the near future as gadolinium consumption is linearly correlated with the number of MRI scans.<sup>34,37,39</sup> Almost half of anthropogenic gadolinium in the environment is generated from brain scans.<sup>34</sup>

The ecological consequences of gadolinium contamination of water are not well understood, but some studies have suggested that elemental gadolinium can affect the growth, reproduction and survival of aquatic organisms, such as

crustaceans, algae, and fish.<sup>40–42</sup> Furthermore, several studies have shown that anthropogenic gadolinium can be found in aquatic plants and organisms, and that gadolinium could potentially reach the human food chain via terrestrial plants growing in areas irrigated with polluted water or plants and animals growing in contaminated aquatic ecosystems.<sup>43,44</sup>

Several initiatives have been developed to mitigate the release of gadolinium into wastewater systems (Fig. 1). These efforts involve enhancing the efficiency of water treatment processes through methods like advanced oxidation, membrane filtration, and adsorption techniques to eliminate gadolinium from wastewater.<sup>45</sup> The adoption of best practices for managing and disposing of contrast agents includes minimizing their usage, segregating waste streams, and utilizing specialized containers to collect any unused contrast agents. Notably, a French study estimated that approximately 15% of prescribed GBCAs went unused and were wasted.<sup>46</sup> The Medical Gadolinium Recycling (MEGADORE) project was established with the goal of creating chemical recycling processes for unused and discarded medical gadolinium.<sup>47</sup> Furthermore, the collection of patients' urine for either 1 or 24 hours after contrast-agent administration has been

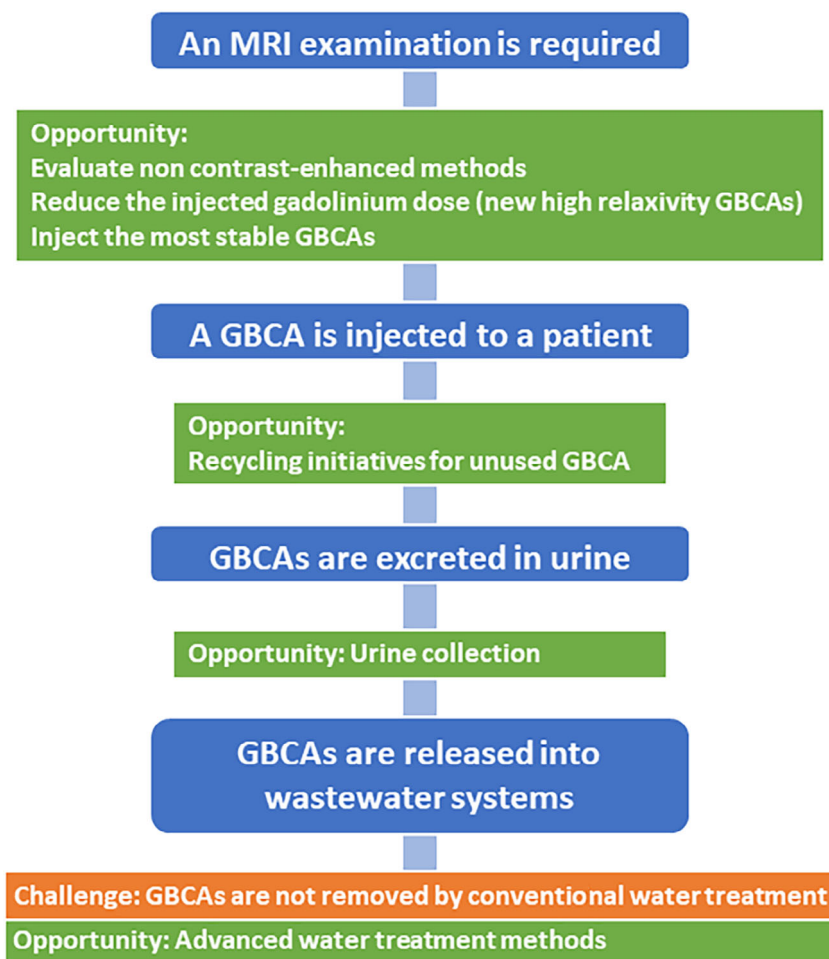


FIGURE 1: Potential opportunities to reduce gadolinium footprint.

proposed, and this approach has shown a high level of patient compliance.<sup>38,48,49</sup>

### Strategies for Reducing or Replacing Gadolinium in Contrast Agents

In a number of pathologies that are currently diagnosed and monitored using contrast-enhanced MRI, the image modality of choice, a number of unenhanced alternatives are emerging to reduce or avoid GBCA use (Table 1).<sup>50</sup> These include arterial spin labeling, time of flight, phase contrast imaging, diffusion-weighted imaging, magnetic resonance spectroscopy, susceptibility weighted imaging, and amide proton transfer imaging.<sup>50</sup> In general, these unenhanced techniques have shown promising diagnostic performance when compared to contrast-enhanced MRI, yet they reflect a different pathophysiological phenomenon and it is unclear if they can be used as valid surrogates for contrast enhancement in clinical practice.<sup>50</sup> Furthermore, these new unenhanced techniques come with some drawbacks including prolonged scan time, motion sensitivity, or lack of availability. Contrast enhancement using GBCAs, remains critical and is used in clinical

practice to increase the sensitivity for small brain metastases, depict an impaired blood–brain barrier, accentuate vessel structures, and estimate tissue perfusion using perfusion-related techniques.

### Alternatives to GBCAs

An alternative to GBCA is to replace it altogether with a gadolinium-free contrast agent. Manganese (Mn) or iron-based agents have been explored in the past. Manganese dipyridoxil diphosphate was first used in humans as an intravenous hepatobiliary MR contrast agent for the detection and characterization of liver lesions in 1997. This molecule is selectively absorbed by hepatocytes. However, it was associated with neurotoxicity concerns with free Mn in patients with liver failure, and was discontinued after failing to achieve commercial success.<sup>51</sup> Some new Mn-based agents are at the research or early clinical development stages.<sup>52–55</sup> Iron has long been known to be a potential alternative to gadolinium in contrast media because iron oxide is a paramagnetic molecule that shortens T<sub>2</sub> time, strongly decreasing the MR signal and thus producing a negative contrast.<sup>4,56</sup> There is currently

**TABLE 1. Strategies to Reduce the Use of Gadolinium**

Strategy	Description	Limitations
Reduce the dose using high relaxivity gadolinium-based contrast agents (GBCAs)	The new generation of GBCAs with high relaxivity can be used at half the dose of gadolinium compared to current GBCAs while maintaining comparable diagnostic efficacy.	<ul style="list-style-type: none"> <li>• Long-term safety data are limited.</li> </ul>
Use of contrast agents that do not contain gadolinium	Superparamagnetic iron-oxide nanoparticles	<ul style="list-style-type: none"> <li>• Adverse reactions are more common than with GBCAs.</li> <li>• Limited use in some indications due to their specific pharmacokinetic properties and susceptibility/relaxivity characteristics.</li> <li>• Not approved as an MRI contrast agent (off-label use).</li> </ul>
	Manganese-based contrast agents	<ul style="list-style-type: none"> <li>• Potential neurotoxicity after exposure to manganese.</li> <li>• None commercially available.</li> </ul>
Use of unenhanced MRI protocols	Non-contrast-enhanced MR techniques include (but not limited to) diffusion-weighted imaging, arterial spin labeling, time of flight, susceptibility weighted imaging, MR spectroscopy, quiescent-interval single-shot MR angiography.	<ul style="list-style-type: none"> <li>• Long acquisition time.</li> <li>• Sensitivity to artifacts and vessel orientation.</li> <li>• Lack of standardization in terms of data acquisition.</li> </ul>
Use of artificial intelligence	Use of deep learning-based models to synthesize full-dose MRI scans from reduced-dose contrast-enhanced or unenhanced MRI scans.	<ul style="list-style-type: none"> <li>• Mostly tested on a limited number of patients, and in single-center studies.</li> <li>• Small enhancing lesions can be overlooked.</li> </ul>

only one commercially available Fe-based agent, an iron oxide nanoparticle which is only approved in the Netherlands.<sup>4</sup>

The obvious alternative to the current generation of GBCAs is a new generation of GBCAs with improved physicochemical properties, offering a higher relaxivity, and thus having the potential to reduce the gadolinium dose, coupled with good in vivo kinetic inertness, thus minimizing the risk of NSF.<sup>4,57</sup> It is likely that these next generation GBCAs will be used in combination with new image acquisition and processing techniques for additional diagnostic optimization, while simultaneously reducing the requirement for GBCAs and lowering the costs.<sup>57</sup>

### New Generation of GBCAs

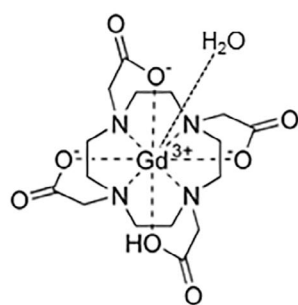
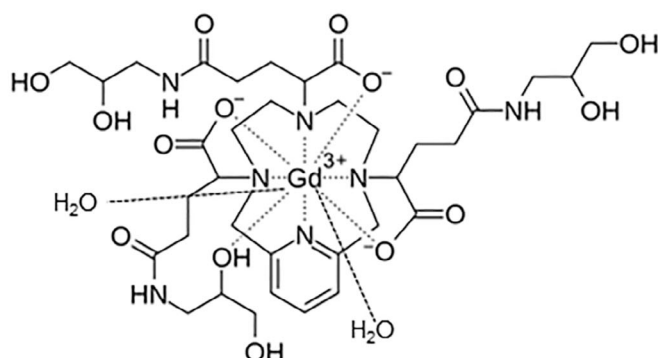
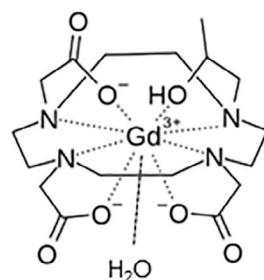
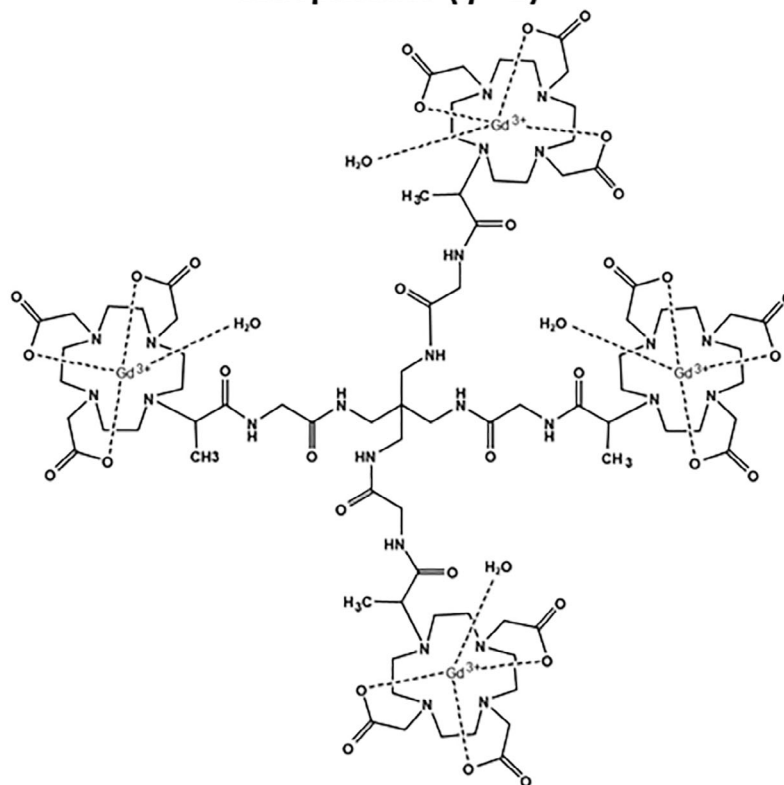
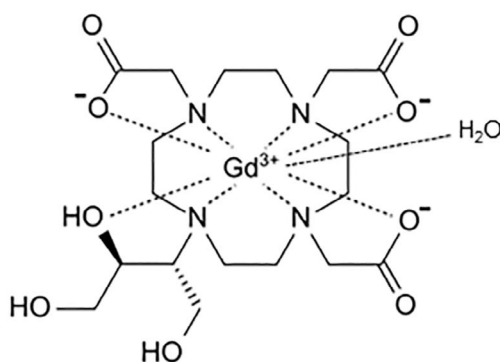
**NEW GBCA ON THE MARKET.** It is now well established that the lowest dose possible of GBCAs should be administered to provide a correct diagnosis, thus the development of high-relaxivity GBCAs is expected to meet a real medical need.<sup>57,58</sup> This new generation of GBCAs should allow the injection of a comparable dose of gadolinium to the standard dose of the current generation of GBCAs while offering a significant improvement in contrast enhancement, leading to additional diagnostic benefits and/or improvements in patient management, or alternatively, a comparable contrast enhancement using a lower dose of gadolinium.<sup>57,59</sup> In addition to high relaxivity, the next generation of GBCAs should also offer high in vivo stability with an optimal safety profile.<sup>4</sup> A number of agents have met these criteria in the past but were limited for other reasons. For example, the blood pool agent gadofosveset trisodium (Ablavar<sup>®</sup>) was indicated for MRA, but production was discontinued in 2017 for commercial reasons.<sup>4,60</sup> Gadobenic acid is another high relaxivity GBCA, now limited to liver imaging in a number of countries. However, its use as a hepatobiliary contrast agent is not always practical in the clinical setting due to a prolonged hepatobiliary phase.<sup>61</sup> A number of research teams around the world are currently developing new GBCAs,<sup>59,62–64</sup> of these, the molecule furthest along in the marketing approval process is the high-relaxivity macrocyclic agent, gadopixelenol (Elucirem<sup>™</sup>, Guerbet).<sup>65,66</sup> It has been approved by the FDA in September 2022 for use in adult and pediatric patients aged 2 years and older to detect and visualize lesions with abnormal vascularity in the CNS, and other body organs (head and neck, thorax, abdomen, pelvis, and musculoskeletal system) at the dose of 0.05 mmol/kg,<sup>5</sup> and more recently (in December 2023) approved in Europe by the EMA.<sup>67</sup>

The relaxation rate  $R_1$  reflects the effectiveness of the contrast agent, and is determined firstly by the contribution of water molecules directly linked to the  $Gd^{3+}$  ion, or the inner sphere contribution; and secondly, by the outer sphere contribution from water molecules that diffuse near the  $Gd^{3+}$  atom but without direct linkage.<sup>65</sup> The relaxivity of a GBCA

molecule can be improved by increasing its molecular size, which affects the rotational time  $\tau_R$ ; and by increasing the hydration number  $q$ , or the number of sites on the chelated  $Gd^{3+}$  accessible for inner sphere proton exchange.<sup>12,65</sup> In most GBCAs, the hydration number is 1 ( $q = 1$ ), with the GBCA complex allowing a single water molecule proton access to the  $Gd^{3+}$  ion at a time.<sup>68,69</sup> The current generation of GBCAs all have a  $q = 1$ .<sup>4</sup> Gadopixelenol has a  $q = 2$ , with two sites for proton exchange with the  $Gd^{3+}$  ion (Fig. 2).<sup>65</sup> In vitro and in vivo data for gadopixelenol and the current generation of non-specific GBCAs show that gadopixelenol exhibits the highest  $r_1$  relaxivity in both water and human serum at 37 °C (i.e., 12.8 and 11.6 mM/s at 1.5 T and 3.0 T, respectively), a 2- to 3-fold higher relaxivity compared with the current generation of GBCAs, with no suggestion of protein binding.<sup>65</sup> The thermodynamic stability and kinetic inertness from in vitro and in vivo data allow a certain degree of prediction and explanation for the in vivo behavior of GBCAs.<sup>13</sup> At very low pH, gadopixelenol demonstrates the highest kinetic inertness, with a dissociation half-life of  $20 \pm 3$  days at pH 1.2,<sup>65</sup> approximately four times the kinetic inertness of the current generation of GBCAs.<sup>65</sup> Gadopixelenol has a relatively low osmolality and a high solubility, which allows for the possibility of injecting a low gadolinium dose and a small administration volume without compromising on clinical efficacy.<sup>65</sup>

In preclinical and clinical studies, gadopixelenol was found to achieve comparable efficacy at 0.05 mmol/kg, i.e., half the standard dose used with currently approved GBCA.<sup>70–73</sup> Two phase III studies confirmed that in CNS and body MRI settings, gadopixelenol at a dose of 0.05 mmol/kg was non-inferior to the standard dose of 0.1 mmol/kg of gadobutrol in terms of lesion visualization (Fig. 3).<sup>74,75</sup> Although the long-term safety profile of this agent will have to be confirmed in a post-marketing setting and in future clinical studies, the phase III studies demonstrated that gadopixelenol at 0.05 mmol/kg has a comparable safety profile to 0.1 mmol/kg gadobutrol.<sup>74,75</sup>

By showing that gadopixelenol can achieve comparable lesion conspicuity at half gadolinium dose compared with the standard dose of gadobutrol for both CNS and body MRI, these phase III studies may herald a new generation of GBCAs, effectively enabling a reduction in gadolinium used without compromising on contrast enhancement.<sup>4</sup> Given the number of people expected to undergo routine GBCA-enhanced MRI screening for conditions like breast or prostate cancer, and patients with diseases requiring regular follow-up contrast-enhanced MRI, these new agents represent an important potential reduction in the total volumes of gadolinium injected. GBCAs that combine high relaxivity, with a  $q = 2$  or greater, with a high in vivo stability, and good extracellular biodistribution will therefore contribute to public safety and environmental benefits.<sup>4</sup> It is most likely that this

**Gadoterate meglumine ( $q = 1$ )****Gadopiclenol ( $q = 2$ )****Gadoteridol ( $q = 1$ )****Gadoquatane ( $q = 1$ )****Gadobutrol ( $q = 1$ )****FIGURE 2:** Chemical structure of macrocyclic GBCAs currently marketed or in development.  $q$ : hydration number.

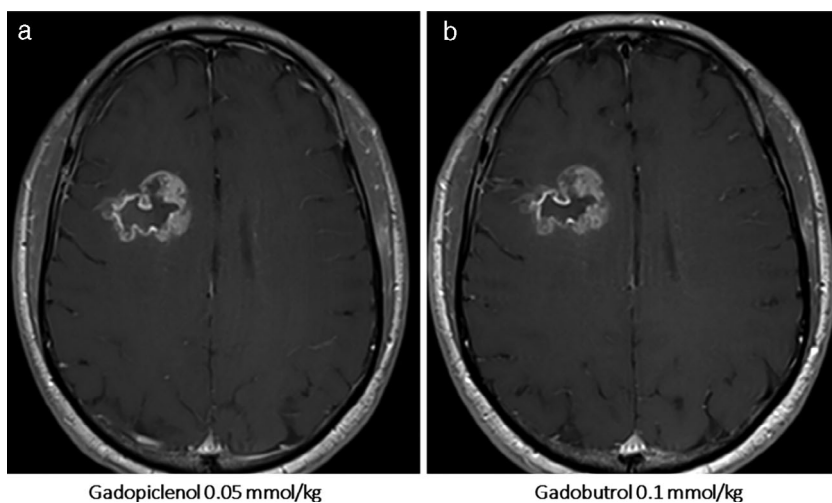
new generation of GBCAs will be coupled with refined image processing techniques to further optimize diagnosis, and reduce gadolinium use.<sup>56</sup>

**GBCA IN DEVELOPMENT.** Another strategy to improve the relaxivity of GBCAs is by increasing their molecular size to slow down the rotational motion by linking single complexes in multimeric systems. This strategy was adopted to develop gadoquatane. Gadoquatane (BAY 1747846) is a tetrameric, macrocyclic, extracellular GBCA, i.e., currently on late-stage clinical development (Fig. 2).

The tetrameric complex carries four macrocyclic Gd-GlyMe-DOTA cages per molecule building a neutral complex with a molecular weight of 2579 g/mol. Compared to other

marketed macrocyclic GBCAs, gadoquatane has a lower osmolality.<sup>64</sup>

The  $r_1$ -relaxivity of gadoquatane in human plasma (at 37°C, pH 7.4) was 11.8 and 10.5 mM/s at 1.5 and 3.0 T, respectively. MRI data of a rat glioblastoma showed that gadoquatane (at 0.1 mmol/kg) had clearly higher contrast-to-noise ratio (CNR) than that with gadobutrol (at 0.1 mmol/kg).<sup>64</sup> A first-in-human study was conducted to assess the PK and safety of gadoquatane at dose levels ranging from 0.025 to 0.2 mmol/kg in healthy participants.<sup>76</sup> Gadoquatane showed similar PK parameters to other currently marketed macrocyclic GBCAs. Regarding the safety profile, only mild to moderate adverse events were reported (none serious) with gadoquatane and no risk of QT/QTc prolongation was identified at clinical dose levels.<sup>76</sup>



**FIGURE 3:** Example of brain MR images from a patient with glioma. Axial 3D T1-weighted GRE MRI scans of a 46-year-old male patient with high-grade glioma (III/IV) who has received gadopipiclenol at the dose of 0.05 mmol/kg (a) and gadobutrol at 0.1 mmol/kg (b).

Three phase III clinical trials are currently being conducted with gadoquatrane at a dose of 0.04 mmol/kg.<sup>77</sup>

**CHALLENGES IN DEVELOPING NEW AGENTS.** Aside from the initial research costs, one particular challenge in developing new contrast agents is the considerable cost associated with the non-clinical, clinical and industrial developments. Clinical development requires controlled studies with large population sizes. In the era of generics, these high development costs reduce the likelihood of manufacturers recouping their investment before patent expiration, and thus the emergence of new contrast agents is likely to be rare.<sup>78</sup>

The other challenges that discourage investment into new contrast media include concerns that health authorities might refuse to authorize the agent; and even if approved, funders might refuse to reimburse it; and finally, radiologists might be reluctant to use it. Manufacturing may also be more challenging than anticipated, and pricing pressures may make it impossible for manufacturers to recoup the development costs. That said, a disruptive imaging method associated with an innovative contrast agent could be expected to have a substantial impact on healthcare systems.<sup>59</sup>

### Improvements in Imaging Analysis and Practice

**NEW MRI TECHNIQUES TO IMPROVE IMAGE QUALITY AND SPEED.** Technological advances, including new signal processing technologies will allow rapid acquisition of data, enabling images to be reconstructed from relatively few measurements.<sup>3</sup> These new techniques allow acquisition of three-dimensional data sets with preserved spatial resolution in a fraction of the standard examination time. These advances are likely to have profound effects on MRI practice, potentially improving patient care and minimizing costs and risk through shorter and less invasive diagnostic examinations.<sup>3</sup> The

increasing accessibility of MRI scanners with extended field of view coils and a high field strength (3 T) has improved the sensitivity of imaging and provides more rapidity.<sup>79</sup> As a single dose of contrast agent is distributed throughout the body, scanners with large coil arrays can facilitate rapid and extensive screening of different areas of the body, increasing the diagnostic power for the same dose of contrast agent compared with previous-generation scanners with a more limited field view.<sup>3</sup> Theoretically, with the increase in the use of 3 T in clinical practice, thanks to its better signal-to-noise ratio, this approach affords greater sensitivity.<sup>80</sup> These techniques are expected to improve diagnostic precision, especially in very small lesions. The optimization of post-contrast sequences (order, duration, and type) combined with 3D acquisitions are especially useful in the study of metastatic diseases in the central nervous system.<sup>81</sup> Techniques such as DIXON, which allow a highly homogeneous subtraction of the fat signal, combined with the administration of a contrast agent, facilitate the study of complex areas such as the neck or particular regions of the musculoskeletal system.<sup>82</sup> The emergence of new sequences which are compatible with GBCAs in terms of improving rapidity and confidence is a promising area, but as yet there is no strong evidence that these techniques have enabled reductions in recourse to standard GBCAs.

In an effort to enhance accessibility, minimize MRI expenses, and streamline workflows for both patients and radiologists during breast cancer screening, staging, and therapy response assessment, abbreviated breast MRI (AB-MRI) has been adopted by multiple organizations. While there is variability in the specific AB-MRI protocols used, all emphasize a “keep it short and simple” approach, and include at least a contrast-enhanced T1-weighted sequence. Additionally, endeavors are being made to incorporate ultrafast sequences to overcome the limited temporal information in many AB-MRI scans or to develop unenhanced AB-MRI protocols.<sup>83</sup> AB-MRI has been

also tested in other organs such as the liver, pancreas, and prostate.

Non-enhanced techniques such as quiescent-interval single-shot (QISS) MRA have been developed to reduce the exposure to ionizing radiation and intravenous contrast media, and their use in clinical practice has increased in the past two decades. Nevertheless, QISS MRA has some drawbacks such as inadequate washout of saturated spin in areas of vessel tortuosity and in-plane flow, and precise cardiac gating may not be possible with some patients.<sup>84</sup> Furthermore, compared to contrast-enhanced MRA, QISS MRA presents with a lower image quality in abdomino-pelvic vessels.<sup>85</sup>

Innovative techniques using a subtractionless single-pass whole-body contrast-enhanced MRA with the compressed-sensing-accelerated mDixon MRA sequence were also shown to be feasible, with relatively faster workflow and around 50% dose reduction of GBCA.<sup>86</sup>

**ARTIFICIAL INTELLIGENCE TO IMPROVE THE EFFECTIVENESS OF CONTRAST ENHANCEMENT.** Since 2018 with a pioneering study from Stanford researchers,<sup>87</sup> the field of virtual contrast enhancement has rapidly gained momentum. An ensuing bulk of studies confirmed the feasibility of synthesizing surrogate images for contrast-enhanced MRI from pre-contrast and/or low-contrast sequences using artificial intelligence.<sup>88–92</sup> Additionally, appropriately trained deep learning methods with imaging protocols relying on GBCA injections at 25%,<sup>92</sup> or 10%,<sup>87–89</sup> of the standard dose (0.1 mmol/kg), or even no contrast agent,<sup>90,91</sup> proved sufficient to reconstruct promising virtual contrast-enhanced T<sub>1</sub> images. For instance, Gong et al developed a deep learning algorithm to investigate the potential reduction of gadolinium dosage in contrast-enhanced brain MRI. They demonstrated that synthesized images from a 10-fold lower gadolinium dose images (0.01 mmol/kg) were comparable to true full-dose images (0.1 mmol/kg) in terms of image quality, contrast enhancement, and artifact suppression.<sup>87</sup> Another study by Ammari et al used a deep learning algorithm to predict surrogate MRI images using only 25% of the standard dose (i.e., 0.025 mmol/kg). This study showed that virtual images were qualitatively superior to standard-dose MRI images. Regarding lesion detection performance, the brain lesion sensitivity of the virtual images was 83% for lesions larger than 10 mm. However, the average sensitivity dropped to 67% for lesions larger than 5 mm, and 56% with all lesions included regardless of their size.<sup>92</sup>

Most recent research has focused on quantifying their diagnostic value in brain neoplasm detection,<sup>88,92</sup> and glioma tumor response assessment.<sup>91</sup> To date, accurately restoring the contrast of smaller lesions is one of the more prominent technical challenges for the field. This limitation could be circumvented by amplifying the contrast of standard rather than low-dose enhanced MRI, yielding a greater than usual

sensitivity for lesion detection.<sup>93</sup> Indeed, a deep learning method designed to increase the CNR in contrast-enhanced brain MRI images acquired at a standard dose (0.1 mmol/kg) was shown to provide superior images compared to reference ones in terms of CNR, lesion-to-brain ratio and contrast enhancement percentage, as well as overall image quality. For lesion detection performance, the sensitivity increased from 88% to 96% for lesions larger than 10 mm, from 70% to 85% for lesions larger than 5 mm, and from 59% to 75% when considering all lesions regardless of their size.<sup>93</sup>

Published studies share a retrospective design and a common focus on T<sub>1</sub>-weighted sequences in neuro-oncology, with large proportions of patients suffering either from glioma or brain metastases. Further potential applications remain unexplored, either within neuroradiology,<sup>94,95</sup> or beyond, for instance in abdominal or musculoskeletal imaging. In future years, new investigations in a broad range of clinical indications and large prospective studies should be expected, with the potential to lower GBCA doses and increase MRI sensitivity in routine care.

## Conclusion

Since the emergence of serious adverse events (NSF) associated with the administration of some GBCAs and the reports on the gadolinium retention in the brain and other body tissues, research initiatives have focused on ways of reducing or avoiding the use of gadolinium altogether without compromising on contrast enhancement. These research avenues have included improvements in scanner hardware, image analysis software, and the exploration of new contrast agents based on alternative lanthanide ions, or using GBCAs with improved relaxivity.<sup>4</sup> Gadopipiclenol is the first example of this new class of true half-dose GBCA, achieving a comparable diagnostic efficacy to existing GBCAs at half the dose of gadolinium.<sup>65,70</sup> High stability, and high-relaxivity GBCAs will be one of the solutions to lowering gadolinium levels in patients and in the environment.<sup>56</sup> Future solutions may involve a combination of next-generation GBCA enhancement and image-processing techniques to optimize diagnosis and treatment planning while minimizing exposure to gadolinium.<sup>56</sup>

## Acknowledgments

M.B. has received honoraria for invited talks from Novartis, TEVA, Bayer, Grifols, Seagen, advisory boards for Guerbet, Seagen, Neuroscios, Vascular Dynamics, Boehringer Ingelheim, research support from Deutsche Forschungsgemeinschaft, European Union, Hopp Foundation, Novartis, Siemens, and is on the editorial board of Springer. A.L. received speaker fees from Bracco Imaging, Bayer, Guerbet, GE Healthcare, and honoraria advisory boards for Guerbet and Lument. J.M. received

honoraria advisory boards from Guerbet and Philips. L.N.T. has received honoraria from GE Healthcare, Philips, Siemens, Fujifilm Healthcare, Subtle Medical, AIDOC, Darmiyan, Agamon, Icometrix, Guerbet, Smartsoft, Voxel.ai, and MR Instruments. B.T. has received research support from Bayer, Takeda Pharmaceuticals U.S.A., Regeneron, Helio Health, Siemens, Echoscens, and is a consultant for Bayer and Guerbet. H.C.T. received honoraria as a consultant for Guerbet.

## References

- Bellin MF, Van Der Molen AJ. Extracellular gadolinium-based contrast media: An overview. *Eur J Radiol* 2008;66(2):160-167.
- Runge VM, Ai T, Hao D, Hu X. The developmental history of the gadolinium chelates as intravenous contrast media for magnetic resonance. *Invest Radiol* 2011;46(12):807-816.
- Lohrke J, Frenzel T, Endrikat J, et al. 25 years of contrast-enhanced MRI: Developments, current challenges and future perspectives. *Adv Ther* 2016;33(1):1-28.
- Lancelot E, Raynaud JS, Desché P. Current and future MR contrast agents: Seeking a better chemical stability and relaxivity for optimal safety and efficacy. *Invest Radiol* 2020;55(9):578-588.
- GlobeNewswire. Guerbet announces U.S. Food and Drug Administration (FDA) approval of Elucirem™ (Gadopipiclenol). *GlobeNewswire*; 2022.
- Radiological Society of The Netherlands. Guideline safe use of contrast media part 3. 2022.
- Jakobsen J, Quattrocchi CC, Müller FHH, et al. Patterns of use, effectiveness and safety of gadolinium contrast agents: A European prospective cross-sectional multicentre observational study. *BMC Med Imaging* 2021;21(1):74.
- Magnetic resonance imaging (MRI) exams (indicator). OECD; 2022.
- Smith-Bindman R, Kwan ML, Marlow EC, et al. Trends in use of medical imaging in US health care systems and in Ontario, Canada, 2000-2016. *JAMA* 2019;322(9):843-856.
- Fatima A, Ahmad MW, Al Saidi AKA, Choudhury A, Chang Y, Lee GH. Recent advances in gadolinium based contrast agents for bioimaging applications. *Nanomaterials (Basel)* 2021;11(9):2449.
- Port M, Idée JM, Medina C, Robic C, Sabatou M, Corot C. Efficiency, thermodynamic and kinetic stability of marketed gadolinium chelates and their possible clinical consequences: A critical review. *Biometals* 2008;21(4):469-490.
- Clough TJ, Jiang L, Wong KL, Long NJ. Ligand design strategies to increase stability of gadolinium-based magnetic resonance imaging contrast agents. *Nat Commun* 2019;10(1):1420.
- Do QN, Lenkinski RE, Tircso G, Kovacs Z. How the chemical properties of GBCAs influence their safety profiles in vivo. *Molecules* 2021; 27(1):58.
- Wahsner J, Gale EM, Rodríguez-Rodríguez A, Caravan P. Chemistry of MRI contrast agents: Current challenges and new frontiers. *Chem Rev* 2019;119(2):957-1057.
- Bruder O, Schneider S, Nothnagel D, et al. Acute adverse reactions to gadolinium-based contrast agents in CMR: Multicenter experience with 17,767 patients from the EuroCMR registry. *JACC Cardiovasc Imaging* 2011;4(11):1171-1176.
- Uhlig J, Al-Bourini O, Salgado R, et al. Gadolinium-based contrast agents for cardiac MRI: Use of linear and macrocyclic agents with associated safety profile from 154 779 European patients. *Radiol Cardiothorac Imaging* 2020;2(5):e200102.
- Grobner T. Gadolinium—A specific trigger for the development of nephrogenic fibrosing dermopathy and nephrogenic systemic fibrosis? *Nephrol Dial Transplant* 2006;21(4):1104-1108.

## Bendszus et al.: MRI Contrast Media: Entering a New Era?

- FDA requests boxed warning for contrast agents used to improve MRI images. U.S. Food & Drug Administration; 2007.
- European Medicines Agency makes recommendations to minimise risk of nephrogenic systemic fibrosis with gadolinium-containing contrast agents. London: European Medicines Agency; 2009.
- ACR Committee on Drugs and Contrast Media. *ACR manual on contrast media*. Reston, VA: American College of Radiology; 2023.
- ACR manual on contrast media. Reston, VA: American College of Radiology; 2022.
- Kanda T, Ishii K, Kawaguchi H, Kitajima K, Takenaka D. High signal intensity in the dentate nucleus and globus pallidus on unenhanced T1-weighted MR images: Relationship with increasing cumulative dose of a gadolinium-based contrast material. *Radiology* 2014;270(3): 834-841.
- Radbruch A. Are some agents less likely to deposit gadolinium in the brain? *Magn Reson Imaging* 2016;34(10):1351-1354.
- FDA identifies no harmful effects to date with brain retention of gadolinium-based contrast agents for MRIs; review to continue. Safety Announcement [5-22-2017]. Available at: <https://www.fda.gov/drugs/fda-drug-safety-podcasts/fda-drug-safety-podcast-fda-identifies-no-harmful-effects-date-brain-retention-gadolinium-based>
- The health risks of MRIs with gadolinium-based contrast agents. National Center for Health Research; 2019.
- PRAC confirms restrictions on the use of linear gadolinium agents. Benefit-risk balance of certain linear gadolinium agents no longer favourable. European Medicines Agency; 2017.
- Lord ML, Chettle DR, Gräfe JL, Noseworthy MD, McNeill FE. Observed deposition of gadolinium in bone using a new noninvasive in vivo biomedical device: Results of a small pilot feasibility study. *Radiology* 2018;287(1):96-103.
- Layne KA, Wood DM, Dargan PI. Gadolinium-based contrast agents – What is the evidence for ‘gadolinium deposition disease’ and the use of chelation therapy? *Clin Toxicol (Phila)* 2020;58(3):151-160.
- Darrah TH, Prutsman-Pfeiffer JJ, Poreda RJ, Ellen Campbell M, Hauschka PV, Hannigan RE. Incorporation of excess gadolinium into human bone from medical contrast agents. *Metallomics* 2009;1(6): 479-488.
- Murata N, Murata K, Gonzalez-Cuyar LF, Maravilla KR. Gadolinium tissue deposition in brain and bone. *Magn Reson Imaging* 2016;34(10): 1359-1365.
- ESUR guidelines on contrast agents. 10.0. Vienna, Austria: European Society of Urogenital Radiology; 2018.
- Altun E, Martin DR, Wertman R, Lugo-Somolinos A, Fuller ER 3rd, Semelka RC. Nephrogenic systemic fibrosis: Change in incidence following a switch in gadolinium agents and adoption of a gadolinium policy—Report from two U.S. universities. *Radiology* 2009;253(3): 689-696.
- Thomsen HS. How to avoid nephrogenic systemic fibrosis: Current guidelines in Europe and the United States. *Radiol Clin North Am* 2009;47(5):871-875. vii.
- Ognard J, Barrat JA, Chazot A, Alavi Z, Ben Salem D. Gadolinium footprint: Cradle to cradle? *J Neuroradiol* 2020;47(4):247-249.
- Brisset JC, Kremer S, Hannoun S, et al. New OFSEP recommendations for MRI assessment of multiple sclerosis patients: Special consideration for gadolinium deposition and frequent acquisitions. *J Neuroradiol* 2020;47(4):250-258.
- Karimian-Jazi K, Wildemann B, Diem R, et al. Gd contrast administration is dispensable in patients with MS without new T2 lesions on follow-up MRI. *Neurol Neuroimmunol Neuroinflamm* 2018;5(5):e480.
- Chazot A, Barrat JA, Gaha M, Jomaah R, Ognard J, Ben SD. Brain MRIs make up the bulk of the gadolinium footprint in medical imaging. *J Neuroradiol* 2020;47(4):259-265.
- Brunjes R, Hofmann T. Anthropogenic gadolinium in freshwater and drinking water systems. *Water Res* 2020;182:115966.

39. Lerat-Hardy A, Coynel A, Dutruch L, et al. Rare earth element fluxes over 15 years into a major European estuary (Garonne-Gironde, SW France): Hospital effluents as a source of increasing gadolinium anomalies. *Sci Total Environ* 2019;656:409-420.
40. Martino C, Costa C, Roccheri MC, Koop D, Scudiero R, Byrne M. Gadolinium perturbs expression of skeletogenic genes, calcium uptake and larval development in phylogenetically distant sea urchin species. *Aquat Toxicol* 2018;194:57-66.
41. Hanana H, Turcotte P, Andre C, Gagnon C, Gagne F. Comparative study of the effects of gadolinium chloride and gadolinium-based magnetic resonance imaging contrast agent on freshwater mussel, *Dreissena polymorpha*. *Chemosphere* 2017;181:197-207.
42. Chen Y, Cao XD, Lu Y, Wang XR. Effects of rare earth metal ions and their EDTA complexes on antioxidant enzymes of fish liver. *Bull Environ Contam Toxicol* 2000;65(3):357-365.
43. Rogowska J, Olkowska E, Ratajczyk W, Wolska L. Gadolinium as a new emerging contaminant of aquatic environments. *Environ Toxicol Chem* 2018;37(6):1523-1534.
44. Lingott J, Lindner U, Telgmann L, Esteban-Fernandez D, Jakubowski N, Panne U. Gadolinium-uptake by aquatic and terrestrial organisms—distribution determined by laser ablation inductively coupled plasma mass spectrometry. *Environ Sci Process Impacts* 2016;18(2):200-207.
45. Ebrahimi P, Barbieri M. Gadolinium as an emerging microcontaminant in water resources: Threats and opportunities. *Geosciences* 2019;9(2):93.
46. Ognard J, Barrat J-A, Cotton F, et al. A roadmap towards pollution prevention and sustainable development of gadolinium. *J Neuroradiol* 2021;48(6):409-411.
47. D BS. The MEDical GADolinium Recycling (MAGADORE) project.
48. Niederste-Hollenberg J, Eckartz K, Peters A, et al. Reducing the emission of X-ray contrast agents to the environment: Decentralized collection of urine bags and its acceptance. *GAIA Ecol Perspect Sci Soc* 2018;27(1):147-155.
49. Zanardo M, Cozzi A, Cardani R, et al. Reducing contrast agent residuals in hospital wastewater: The GREENWATER study protocol. *Eur Radiol Exp* 2023;7(1):27.
50. Falk Delgado A, Van Westen D, Nilsson M, et al. Diagnostic value of alternative techniques to gadolinium-based contrast agents in MR neuroimaging—A comprehensive overview. *Insights Imaging* 2019;10(1):84.
51. Czeyda-Pommersheim F, Martin DR, Costello JR, Kalb B. Contrast agents for MR imaging. *Magn Reson Imaging Clin N Am* 2017;25(4):705-711.
52. Gale EM, Wey HY, Ramsay I, Yen YF, Sosnovik DE, Caravan P. A manganese-based alternative to gadolinium: Contrast-enhanced MR angiography, excretion, pharmacokinetics, and metabolism. *Radiology* 2018;286(3):865-872.
53. Pan D, Schmieder AH, Wickline SA, Lanza GM. Manganese-based MRI contrast agents: Past, present and future. *Tetrahedron* 2011;67(44):8431-8444.
54. Gale EM, Atanasova IP, Blasi F, Ay I, Caravan P. A manganese alternative to gadolinium for MRI contrast. *J Am Chem Soc* 2015;137(49):15548-15557.
55. Troughton JS, Greenfield MT, Greenwood JM, et al. Synthesis and evaluation of a high relaxivity manganese(II)-based MRI contrast agent. *Inorg Chem* 2004;43(20):6313-6323.
56. Minton LE, Pandit R, Willoughby WR, Porter KK. The future of magnetic resonance imaging contrast agents. *Appl Radiol* 2022;51(1):7-11.
57. Minton LE, Pandit R, Porter KK. Contrast-enhanced MRI: History and current recommendations. *Appl Radiol* 2021;50(6):15-19.
58. Lancelot E, Desche P. Gadolinium retention as a safety signal: Experience of a manufacturer. *Invest Radiol* 2020;55(1):20-24.
59. Runge VM, Heverhagen JT. Advocating the development of next-generation high-Relaxivity gadolinium chelates for clinical magnetic resonance. *Invest Radiol* 2018;53(7):381-389.
60. Rapp JH, Wolff SD, Quinn SF, et al. Aortoiliac occlusive disease in patients with known or suspected peripheral vascular disease: Safety and efficacy of gadofosveset-enhanced MR angiography—Multicenter comparative phase III study. *Radiology* 2005;236(1):71-78.
61. Welle CL, Guglielmo FF, Venkatesh SK. MRI of the liver: Choosing the right contrast agent. *Abdom Radiol (NY)* 2020;45(2):384-392.
62. Tweedle MF. Next-generation MRI contrast agents: Still including gadolinium. *Radiology* 2020;294(1):127-128.
63. Fringuello Mingo A, Colombo Serra S, Baroni S, et al. Macrocyclic paramagnetic agents for MRI: Determinants of relaxivity and strategies for their improvement. *Magn Reson Med* 2017;78(4):1523-1532.
64. Lohrke J, Berger M, Frenzel T, et al. Preclinical profile of gadoquatrane: A novel tetrameric, macrocyclic high relaxivity gadolinium-based contrast agent. *Invest Radiol* 2022;57(10):629-638.
65. Robic C, Port M, Rousseaux O, et al. Physicochemical and pharmacokinetic profiles of gadopixelon: A new macrocyclic gadolinium chelate with high T1 relaxivity. *Invest Radiol* 2019;54(8):475-484.
66. Port M. *Short aminoalcohol compounds and metal complexes for medical imaging*. Villepinte: Guerbet; 2005.
67. European Commission. Union Register of medicinal products for human use: Elucirem. 2023. <https://ec.europa.eu/health/documents/community-register/html/h1772.htm>
68. Kotek J, Kubicek V, Hermann P, Lukes I. Synthesis and characterisation of ligands and their gadolinium(III) complexes. In: Merbach A, Helm L, Toth E, editors. *The chemistry of contrast agents in medical magnetic resonance imaging*. 2nd ed. Chichester, Great Britain: John Wiley & Sons, Ltd; 2013. p 83-155.
69. Toth E, Helm L, Merbach A. Relaxivity of gadolinium(III) complexes: Theory and mechanism. In: Merbach A, Helm L, Toth E, editors. *The chemistry of contrast agents in medical magnetic resonance imaging*. 2nd ed. Chichester: John Wiley & Sons, Ltd.; 2013. p 25-81.
70. Robert P, Vives V, Grindel AL, et al. Contrast-to-dose relationship of gadopixelon, an MRI macrocyclic gadolinium-based contrast agent, compared with gadoterate, gadobenate, and gadobutrol in a rat brain tumor model. *Radiology* 2020;294(1):117-126.
71. Hao J, Bourrinet P, Desche P. Assessment of pharmacokinetic, pharmacodynamic profile, and tolerance of gadopixelon, a new high relaxivity GBCA, in healthy subjects and patients with brain lesions (phase I/IIa study). *Invest Radiol* 2019;54(7):396-402.
72. Bendszus M, Roberts D, Kolumban B, et al. Dose finding study of Gadopixelon, a new macrocyclic contrast agent, in MRI of central nervous system. *Invest Radiol* 2020;55(3):129-137.
73. Fries P, Massmann A, Robert P, et al. Evaluation of gadopixelon and P846, 2 high-relaxivity macrocyclic magnetic resonance contrast agents without protein binding, in a rodent model of hepatic metastases: Potential solutions for improved enhancement at ultrahigh field strength. *Invest Radiol* 2019;54(9):549-558.
74. Loevner LA, Kolumban B, Hutoczki G, et al. Efficacy and safety of gadopixelon for contrast-enhanced MRI of the central nervous system: The PICTURE randomized clinical trial. *Invest Radiol* 2023;58(5):307-313.
75. Kuhl C, Csoszi T, Piskorski W, Miszalski T, Lee JM, Otto PM. Efficacy and safety of half-dose gadopixelon versus full-dose gadobutrol for contrast-enhanced body MRI. *Radiology* 2023;308(1):e222612.
76. Hofmann BM, Riecke K, Klein S, et al. Pharmacokinetics, safety, and tolerability of the novel tetrameric, high-Relaxivity, macrocyclic gadolinium-based contrast agent gadoquatrane in healthy adults. *Invest Radiol* 2023, doi:10.1097/RLI.0000000000001043
77. ClinicalTrials.gov [Internet]. National Library of Medicine (US).
78. Thomsen HS. Generic gadolinium-based contrast agents: The future? *Acta Radiol* 2017;58(11):1285-1287.
79. Hartung MP, Grist TM, François CJ. Magnetic resonance angiography: Current status and future directions. *J Cardiovasc Magn Reson* 2011;13(1):19.

80. Rahbar H, Partridge SC, DeMartini WB, Thursten B, Lehman CD. Clinical and technical considerations for high quality breast MRI at 3 Tesla. *J Magn Reson Imaging* 2013;37(4):778-790.
81. Touska P, Connor SEJ. Recent advances in MRI of the head and neck, skull base and cranial nerves: New and evolving sequences, analyses and clinical applications. *Br J Radiol* 2019;92(1104):20190513.
82. Huijgen WHF, van Rijswijk CSP, Bloem JL. Is fat suppression in T1 and T2 FSE with mDixon superior to the frequency selection-based SPAIR technique in musculoskeletal tumor imaging? *Skeletal Radiol* 2019;48(12):1905-1914.
83. Grimm LJ, Mango VL, Harvey JA, Plecha DM, Conant EF. Implementation of abbreviated breast MRI for screening: AJR expert panel narrative review. *AJR Am J Roentgenol* 2022;218(2):202-212.
84. Kuo AH, Nagpal P, Ghoshhajra BB, Hedgire SS. Vascular magnetic resonance angiography techniques. *Cardiovasc Diagn Ther* 2019;9(Suppl 1):S28-S36.
85. Saini A, Wallace A, Albadawi H, et al. Quiescent-interval single-shot magnetic resonance angiography. *Diagnostics (Basel)* 2018;8(4):84.
86. Fu Q, Lei ZQ, Li JY, et al. Subtractionless compressed-sensing-accelerated whole-body MR angiography using two-point Dixon fat suppression with single-pass half-reduced contrast dose: Feasibility study and initial experience. *J Cardiovasc Magn Reson* 2023;25(1):41.
87. Gong E, Pauly JM, Wintermark M, Zaharchuk G. Deep learning enables reduced gadolinium dose for contrast-enhanced brain MRI. *J Magn Reson Imaging* 2018;48(2):330-340.
- Bendszus et al.: MRI Contrast Media: Entering a New Era?**
88. Luo H, Zhang T, Gong NJ, et al. Deep learning-based methods may minimize GBCA dosage in brain MRI. *Eur Radiol* 2021;31(9):6419-6428.
89. Pasumarthi S, Tamir JI, Christensen S, Zaharchuk G, Zhang T, Gong E. A generic deep learning model for reduced gadolinium dose in contrast-enhanced brain MRI. *Magn Reson Med* 2021;86(3):1687-1700.
90. Kleesiek J, Morshuis JN, Isensee F, et al. Can virtual contrast enhancement in brain MRI replace gadolinium?: A feasibility study. *Invest Radiol* 2019;54(10):653-660.
91. Jayachandran Preetha C, Meredig H, Brugnara G, et al. Deep-learning-based synthesis of post-contrast T1-weighted MRI for tumour response assessment in neuro-oncology: A multicentre, retrospective cohort study. *Lancet Digit Health* 2021;3(12):e784-e794.
92. Ammari S, Bône A, Balleyguier C, et al. Can deep learning replace gadolinium in neuro-oncology?: A reader study. *Invest Radiol* 2022;57(2):99-107.
93. Bône A, Ammari S, Menu Y, et al. From dose reduction to contrast maximization: Can deep learning amplify the impact of contrast media on brain magnetic resonance image quality? A reader study. *Invest Radiol* 2022;57(8):527-535.
94. Narayana PA, Coronado I, Sujit SJ, Wolinsky JS, Lublin FD, Gabr RE. Deep learning for predicting enhancing lesions in multiple sclerosis from noncontrast MRI. *Radiology* 2020;294(2):398-404.
95. Rudie JD, Mattay RR, Schindler M, et al. An initiative to reduce unnecessary gadolinium-based contrast in multiple sclerosis patients. *J Am Coll Radiol* 2019;16(9 Pt A):1158-1164.