UAB
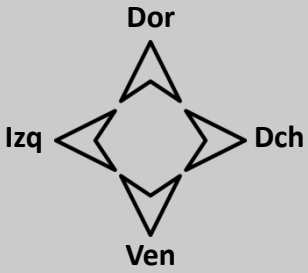
Sección transversal 19
Tórax, visión caudal