



**Universitat Autònoma
de Barcelona**

**Estudio de la inflamación endometrial post-
inseminación con semen congelado en la burra
catalana y posibilidades de control**

**Study of endometritis after insemination with frozen
semen in the Catalan donkey and ways to control it**

Karina Vilés López

Director de tesis: Jordi Miró Roig

Tesis doctoral / Doctoral thesis

Facultad de Veterinaria

Departamento de Medicina y Cirugía Animales

Universidad Autónoma de Barcelona

Bellaterra, 2013



**Universitat Autònoma
de Barcelona**

JORDI MIRO i ROIG, professor titular del Departament de Medicina i Cirurgia Animals de la Facultat de Veterinària de la Universitat Autònoma de Barcelona,

CERTIFICA,

Que la Tesi Doctoral titulada “ESTUDIO DE LA INFLAMACIÓN ENDOMETRIAL POST-INSEMINACIÓN CON SEMEN CONGELADO EN LA BURRA CATALANA Y POSIBILIDADES DE CONTROL” i presentada per KARINA VILÉS LÓPEZ per optar al grau de Doctor en Veterinària, s’ha realitzat sota la meva direcció i, considerant-la acabada, autoritzo la seva presentació perquè sigui jutjada per la comissió corresponent.

I per què així consti als efectes que correspongui, signo el present a Bellaterra a dos de desembre de dos-mil tretze.

Aquesta Tesi Doctoral s’ha realitzat en el marc de projecte RZP2012-00004-00-00 (Instituto Nacional de Investigación y Tecnología Agraria y Alimentaria) titulat: “*Actualización de los bancos de semen congelado de Burro Catalán y Mallorquín atendiendo a la priorización genética de sus reproductores y optimización de los resultados obtenidos mediante IA con semen congelado en asnos*”.

“Estem fotuts si les burre no fan rucs”

“Scientific theories are excellent
as long as they are used as transient working hypothesis,
not when they lead to religious dogmas”

Chaouat (2007)

Tesis doctoral como compendio de publicaciones

- I. Vilés, K., Rabanal, R., Rodríguez-Prado, M., Miró, J., 2013. Effect of ketoprofen treatment on the uterine inflammatory response after AI of jennies with frozen semen. *Theriogenology* 79: 1019-1026.

- II. Miró, J., Vilés, K., García, W., Jordana, J., Yeste, M., 2013. Effect of donkey seminal plasma over sperm movement and sperm-polymorphonuclear neutrophils attachment *in vitro*. *Anim. Reprod. Sci.* 140: 164-172.

- III. Vilés, K., Rabanal, R., Rodríguez-Prado, M., Miró, J., Influence of seminal plasma on leukocyte migration and amount of COX-2 protein in the jenny endometrium after insemination with frozen-thawed semen. *Anim. Reprod. Sci.* Available online 16 November 2013, ISSN 0378-4320, <http://dx.doi.org/10.1016/j.anireprosci.2013.11.002>.

Alguien me dijo una vez que *cada persona que pasa en nuestra vida es única y siempre deja un poco de sí y se lleva un poco de nosotros. Habrán los que se llevan mucho, pero no habrá de los que no nos dejan nada.* Porque somos el resultado de ese poquito que dejan las otras personas en uno, agradezco a todos aquellos que se consideren colaboradores de este trabajo, especialmente a:

Mis padres Nancy y Miguel,

Mi hermano Christian y su esposa,

Jordi Miró,

Los coautores,



Contenidos / Contents

Resumen	9
Abstract	11
1. Introducción/Introduction	13
1.1. El asno catalán	15
1.2. Tecnologías reproductivas para la conservación de los recursos zoogenéticos.....	17
1.2.1. La inseminación artificial (IA) en equinos.....	19
1.3. Endometritis inducida por el semen.....	22
1.3.1. Diagnostico de endometritis.....	24
1.3.2. Tratamientos anti-inflamatorios.....	24
1.3.3. El plasma seminal como modulador de la inflamación.....	25
2. Objetivos/Aims	27
3. Capítulos/Chapters	31
Capítulo I: Effect of ketoprofen treatment on the uterine inflammatory response after AI of jennies with frozen semen.....	33
Capítulo II: Effect of donkey seminal plasma over sperm movement and sperm-polymorphonuclear neutrophils attachment <i>in vitro</i>	43
Capítulo III: Influence of seminal plasma on leukocyte migration and amount of COX-2 protein in the jenny endometrium after insemination with	

frozen-thawed semen.....	55
4. Discusión/Discusión.....	65
5. Conclusiones finales/Final Conclusions.....	73
6. Bibliografía/Bibliography.....	77



Resumen

El burro catalán es una raza en peligro de extinción. Las razas autóctonas como el burro catalán, representan poblaciones de interés biológico para el mantenimiento de la biodiversidad y forman parte del patrimonio de un país y de la historia de una población humana. Las biotecnologías reproductivas constituyen una herramienta estratégica para la conservación y recuperación de los recursos genéticos de especies amenazadas. Sin embargo, el éxito de su aplicación ha sido limitado por la falta de estudios básicos sobre los aspectos reproductivos y la ausencia de protocolos estandarizados para estas especies. Los resultados de fertilidad tras la inseminación artificial (IA) con semen congelado en burros son muy escasos, aún cuando las características de calidad del semen de burro a la descongelación han demostrado ser adecuadas. No obstante, teniendo en cuenta que la fertilidad no solo depende del macho sino también de la fisiología reproductiva de la hembra, ésta tesis doctoral tuvo como objetivo principal evaluar la respuesta inflamatoria del endometrio de la burra tras la IA con semen congelado/descongelado, con el propósito de mejorar a futuro los resultados de fertilidad con semen congelado en burros.

En el primer trabajo se determinaron las características del endometrio de la burra en estro, post-IA con semen congelado/descongelado y se evaluó el efecto del ketoprofen como tratamiento anti-inflamatorio durante el protocolo de inseminación. Se encontraron diferencias histológicas del endometrio de la burra con respecto a la yegua, como la presencia de eosinófilos en todos los grupos experimentales sin relación con otros cambios inflamatorios o degenerativos; concluyendo que estas células parecen constituir una característica normal del endometrio de la burra sana. El ketoprofen presentó una eliminación rápida y una escasa distribución aparente. Su mecanismo de acción sobre endometrio inflamado de la burra fue la inhibición de

la expresión del mediador inflamatorio ciclooxigenasa-2 (COX-2) principalmente en el estrato compacto, sin influir sobre la cantidad de neutrófilos polimorfonucleares (PMN) presentes a las 6 h post-IA.

En el segundo estudio se evaluó el efecto *in Vitro* del plasma seminal (PS) sobre los espermatozoides y los PMN endometriales. Se incubaron secreciones uterinas obtenidas a las 6 h post-IA con semen congelado; con muestras de semen fresco puro, fresco diluido y congelado/descongelado durante 4 h. Se observó una menor formación de agregados PMN-espermatozoides y una mayor motilidad progresiva en las muestras de semen fresco y diluido comparadas con el semen congelado. Por tanto, la presencia de PS en el semen fresco y diluido produjo una modulación de la respuesta inflamatoria endometrial *in Vitro*.

Finalmente, se determinó el efecto *in Vivo* del PS sobre el endometrio de la burra tras la IA con semen congelado/descongelado. La administración intrauterina de PS autólogo inmediatamente después de la IA, inhibió significativamente la expresión de COX-2 tanto en el estrato luminal como en el estrato compacto hasta el punto en que no se encontraron diferencias con las muestras del endometrio no inflamado en estro (control). El PS no influyó sobre el número de PMN a las 6 h post-IA. Sin embargo, la expresión de COX-2 se correlacionó con el número de PMN de citologías y biopsias, por tanto, la quimiotaxis de PMN pudo haber sido reducida por esta vía.

En conclusión, la burra sana parece ser más susceptible que la yegua a desarrollar endometritis post-inseminación con semen congelado, posiblemente debido a las diferencias histológicas observadas, así como a características anatómicas y fisiológicas de su tracto reproductivo documentadas como propias de la burra. También existen diferencias en la disposición farmacológica del ketoprofen en el burro. Estos aspectos, así como el papel modulador *in Vitro* e *in Vivo* del PS observado en las interacciones PMN-espermatozoides en el burro catalán, implican un importante objetivo de investigación para optimizar el protocolo de IA con semen congelado y mejorar los resultados de fertilidad de esta tecnología reproductiva en burros.



Abstract

The Catalan donkey is an endangered breed. Native populations such as this one are of great importance for the maintenance of biodiversity and for the heritage and history of a country. Reproductive technologies constitute a strategic tool for the conservation and maintenance of the genetic resources of endangered populations. However, their successful application has been limited by scarcity of basic studies in reproduction and absence of standardized protocols. Fertility rates achieved by artificial insemination (AI) with frozen semen in donkeys are disappointingly low, despite the apparently adequate quality of the thawed semen. Nevertheless, fertility is not only dependent on the male but also on the female reproductive physiology. Hence, the aim of this doctoral thesis was to evaluate the endometrial inflammatory response after insemination with frozen/thawed semen in the Jenny, with a view to help enhance fertility rates with frozen semen in donkeys.

In the first study, the characteristics of the jenny's endometrium were evaluated in estrous (control), both after-AI with frozen/thawed semen and after-AI with ketoprofen administered as anti-inflammatory treatment. In contrast to mare, the presence of eosinophils in all experimental groups without any relation to other inflammatory or degenerative changes indicated that they could be a normal feature of a healthy Jenny endometrium. On the other hand, ketoprofen was rapidly eliminated of blood and had a poor apparent tissular distribution. Its mechanism of action on the inflamed endometrium was cyclooxygenase-2 (COX-2) inhibition, which was mainly observed in the stratum compactum, and had no effect on the number of polymorphonuclear neutrophils (PMN) present at 6 h after-AI.

In the second study, the *in Vitro* effect of seminal plasma (SP) over sperm and endometrial PMN was determined. Uterine secretions obtained at 6 h after-AI were incubated with samples of fresh pure, fresh diluted and frozen/thawed donkey semen

during 4 h. Fresh pure and fresh diluted semen (where SP was present) showed less PMN-sperm binding and a higher progressive motility than frozen semen. Thus, a modulating effect of SP on endometrial inflammation was observed *in Vitro*.

Finally, the *in Vivo* effect of SP in the Jenny endometrium after-AI with frozen/thawed semen was determined. Intrauterine administration of pre-warmed autologous SP immediately after-AI, inhibited COX-2 expression both in the luminal epithelium and stratum compactum at 6 h of insemination, to the point that there were no differences with the non-inflamed endometrium in estrous (control). The number of PMN produced 6 h after-AI was not affected by SP. However, since COX-2 expression was correlated with PMN number observed both in cytology and biopsies, PMN chemotaxis might actually have been reduced by this via.

In conclusion, it seems that healthy Jenny is more susceptible than healthy mare to develop endometritis after AI with frozen semen, ostensibly, due to histological differences observed, and physiological and anatomical features described in the reproductive tract. There are also pharmacologic differences on drug disposition (ketoprofen) in donkeys. These aspects, as well as the *in Vitro* and *in Vivo* modulator effects of SP over the PMN-sperm interactions observed in the Catalan donkey, involve an important research aim to optimize the insemination protocol with frozen semen and improve fertility outcomes of this reproductive technology donkeys.



Introducción / Introduction

1. Introducción / Introduction

1.1. El asno catalán

El burro y sus híbridos mulares han jugado un papel importante como animales de trabajo en España. En la primera mitad del siglo XX, los asnos y mulos componían la mayor parte de los efectivos equinos del país y a pesar de que en la segunda mitad del siglo ocurrió una drástica caída del censo asnal por la mecanización agraria, la riqueza en cuanto al número de razas autóctonas asnales en España es notable. Estas razas provienen del tronco ancestral *Equus asinus somaliensis* y contribuyen con un 43% de la genética asinina europea (Rodero et al., 1998).

El burro catalán es una de las 6 razas asnales autóctonas formalizadas y catalogadas como “Raza autóctona de Protección Especial” por el Ministerio de Agricultura, Pesca y Alimentación (BOE núm. 59, ORDEN APA/661/2006). Se caracteriza por un formato hipermétrico, con alzadas entre 140-160 cm en el macho, 135-150 cm en las hembras y pesos entre 350-450 kg; cabeza elevada, orejas erectas y perfil craneal subcónico con tendencia rectilínea, que es más marcado en hembras y pollinos. De conformación harmónica y silueta esbelta, extremidades robustas y bien conformadas para realizar trabajos duros en tiempo y esfuerzo. Su carácter es dócil, expresivo, noble y de gran vivacidad. La capa es oscura, el pelo corto y brillante con degradaciones a blanco alrededor del morro, zonas orbitales de los ojos, base de las orejas, pene, vientre y cara interna de las extremidades (Folch, 1998; Jordana et al., 2010) (Fig. 1).

El burro catalán ha contribuido en la formación y mejora de otras razas asininas europeas como la raza francesa Baudet de Poitou, las italianas Pantasca, Martina-Franca y Siciliana o Ragusana (Romagosa, 1959; Torres et al., 1983; Parés y Vilaró, 1994). Tuvo una influencia directa en la formación del burro de Kentucky o Mammoth en Estados Unidos, de cuyo primer ejemplar se conoce que llegó a Charleston

(Carolina del Sur) procedente de Cataluña en 1819, siendo apreciado principalmente por sus características fenotípicas y su temperamento enérgico pero plácido a la vez (Jordana y Folch, 1996; Kugler et al., 2008).

Con la guerra civil (1936-1939), la raza catalana casi desaparece, pero en la post-guerra (1940-1950) esta población aumenta debido al retorno de los sistemas tradicionales de producción agraria (Jordana et al., 2010). Posteriormente, ocurre una nueva caída del censo asnal en los años 70 y como consecuencia, en 1978 se funda la Asociación de Fomento de la Raza Asinina Catalana (AFRAC) y en 1994 se da inicio al programa de conservación y mantenimiento de recursos genéticos de la raza por medio del departamento de Agricultura, Ganadería y pesca (DARP) de la Generalitat de Catalunya, que en colaboración con la Unidad de Genética y Mejora, así como del Servicio de Reproducción Equina de la Facultad de Veterinaria de la Universidad Autónoma de Barcelona (UAB), promueven la investigación con el fin de proteger, fomentar y seleccionar esta raza (Jordana y Folch., 1998).



Figura 1. Ejemplar del asno catalán

Gracias a la reapertura y reglamentación en 2002 por parte del AFRAC, del Libro Genealógico de la Raza Asinina Catalana (Diario Oficial de la Generalitat de Catalunya num. 3608, de 4 de Abril) que databa del año 1929 con tan solo 8 hembras y 2 sementales registrados, es posible constatar que actualmente el censo alcanza aproximadamente 736 ejemplares registrados, distribuidos principalmente en las comarcas de Girona y Barcelona, y en la Cataluña norte en las comarcas del Conflent y el Vallespir (Jordana et al., 2010). No obstante, esta población aun sigue siendo catalogada como raza en inminente peligro de extinción por la FAO (DAD-IS, 2011).

Las nuevas motivaciones para la crianza y tenencia del burro con base en la instauración de sistemas productivos sostenibles, han reorientado su explotación hacia otras actividades socio-económicas que fortalecen la recuperación de la raza, destacándose la limpieza no invasiva de bosques para evitar el desarrollo de incendios, labranza mínima, programas de educación ambiental y ecoturismo, producción de leche de burra para consumo o elaboración de productos cosméticos, así como terapias para personas con discapacidades mentales o neuro-musculares (Heinemann, 2009; Cosentino et al., 2012; 2013; www.apassodasino.org; www.antasonlus.org). Estas actividades han contribuido a la recuperación y conservación de diferentes razas de burro, pero en el caso de la catalana, el elevado mestizaje debido a la escasez de animales puros y la consanguinidad por el limitado número de animales siguen siendo los inconvenientes principales que comportan el deterioro y desaparición de la raza y por tanto, se consideran pilares objetivos básicos en los programas de conservación (Aranguren et al., 2002).

1.2. Tecnologías reproductivas para la conservación de los recursos zoogenéticos

Los recursos genéticos animales son el resultado de una interacción dinámica entre las condiciones medioambientales y la selección humana respecto a sus preferencias culturales y económicas, que durante millones de años de evolución conducen al desarrollo y mejoramiento de diferentes especies y razas animales adaptadas a una región. El espectro de diferencias genéticas o combinaciones

únicas de alelos generados para cada raza proveen la variación o la diversidad genética de una especie, la cual, mantiene la estabilidad de los diferentes ecosistemas (FAO, 2007).

Las razas autóctonas o locales se consideran parte importante de la biodiversidad mundial, ya que al pertenecer generalmente a troncos genéticos muy lejanos de las razas “industriales”, disponen de una amplia diversidad genética que se traduce en más material genético para sobrevivir a los procesos de selección natural y adaptación, condiciones de manejo, producción y epidemiología local en ecosistemas que cambian constantemente. Además, pueden contener genes y combinaciones genéticas que aunque actualmente sean difíciles de aislar y estudiar, podrían contribuir en programas de producción futuros así como para entender algunos aspectos evolutivos. Los recursos genéticos animales también representan el patrimonio de una región, ya que abordando una dimensión social, económica y cultural, con su explotación es posible establecer sistemas de producción sostenibles adaptados a las condiciones locales, evitando la despoblación de familias y manteniendo el equilibrio demográfico y ecológico de una zona (Hall y Bradley, 1995; Folch, 1998; Lauvie et al., 2011).

En los últimos 100 años se ha producido una pérdida importante de diversidad genética, es decir, una extinción de especies y variedades locales, que en el caso de los animales destinados a granja, se ha debido principalmente a la tecnificación del campo y a la rápida intensificación de la producción ganadera, con el fin de suplir las necesidades alimentarias actuales de una sociedad creciente y globalizada (Drucker et al., 2001; Andrabi y Maxwell, 2007). De acuerdo con los datos del estado de los recursos genéticos animales de la FAO, un 30% de las razas de granja documentadas están en riesgo de extinción; 1500 de 7600 razas en todo el mundo podrían ser extintas para siempre en un futuro no muy lejano (FAO, 2007). La pérdida de una raza puede afectar al funcionamiento de un ecosistema entero. Es por ello, que la preocupación a distintos niveles sobre la importancia de la conservación y mantenimiento de estas razas, ha incentivado la investigación en los

últimos 20 años con el fin de lograr el éxito de sistemas de conservación y producción sostenible propuestos e introducidos para cada región.

La conservación de una raza no solo se enfoca en el mantenimiento y aumento del tamaño de su población y preservación de su hábitat, sino también en el mantenimiento e incremento de la variabilidad genética de la misma, sobretodo cuando se trata de poblaciones con un número reducido de individuos (Lauvie et al., 2011). Es aquí donde las tecnologías reproductivas asistidas (ART), entre las que se destacan la congelación de semen o embriones y posterior inseminación artificial (IA) y transferencia embrionaria, han cobrado importancia como herramientas de conservación ex situ – *in Vitro*, porque permiten el mantenimiento artificial de genes en bancos de germoplasma que pueden ser utilizados en programas de conservación *in Vivo* en un futuro (Lauvie et al., 2011; FAO, 2012). Aunque el éxito de su aplicación en especies amenazadas y razas autóctonas aún es limitado debido principalmente a los escasos estudios sobre los aspectos reproductivos básicos y a la falta de protocolos establecidos para cada especie (Pukazhenthí y Wildt, 2004), las ART representan un potencial de conservación, ya que aceleran el progreso genético, reducen el intervalo entre generaciones, facilitan la distribución mundial y aprovechamiento de genes de ejemplares valiosos de los que se puede obtener una mayor cantidad de descendientes sin los riesgos de transmisión de enfermedades, así como de aquellos ya fallecidos, extinguidos o que no pueden reproducirse de forma natural (Comizzoli et al., 2000; Andrabi y Maxwell, 2007; FAO, 2012).

1.2.1. La inseminación artificial (IA) en los equinos

La IA ha sido la biotecnología más ampliamente usada en el mundo para el mejoramiento genético en animales de producción. Por décadas, la IA ha sido utilizada en la mejora del ganado bovino, principalmente en la raza Holstein, en la cual, la producción de leche se ha logrado duplicar en los últimos 40 años gracias a la rápida selección para conseguir los propósitos productivos deseados (Adams et al., 2009). Sin embargo, parece ser que el primer animal obtenido mediante IA fue el caballo.

Según la historia, alrededor de el año 1300 se colectó semen de una yegua árabe que acababa de ser cubierta, se diluyó en leche de camella y se mantuvo atemperado en un recipiente hecho de piel de cabra hasta ser utilizado para inseminar otra yegua de una tribu árabe rival, obteniéndose al cabo de un año un potro sano (Allen, 2005). No obstante, entre los primeros estudios científicos se destacan los trabajos del Inglés Walter Heape (1855-1929) en Estados Unidos y Australia antes de la primera guerra mundial, donde realiza inseminaciones con semen aspirado de la vagina de yeguas cubiertas, así como la colección de semen equino en condones hechos de vejigas de cerdo por G. Sand (1903) en Copenhagen y obtención de gestaciones en yeguas. Sin embargo, los estudios que tuvieron un impacto importante para el desarrollo de tecnologías de la reproducción en equinos fueron los realizados en Rusia, gracias a la demanda militar y agrícola después de la primera guerra mundial. El ruso Elia Iwanoff (1870-1932), fue el primer científico en realizar experimentos controlados, coleccionar semen de esponjas introducidas en la vagina de yeguas para evitar el contacto del macho, proponer el transporte de semen entre lugares cercanos y obtener híbridos inter-especies como el zebroide. Durante los años 30 tras la segunda guerra mundial, los equinos perdieron importancia, pero las investigaciones sobre la conservación del semen avanzaron junto con la industria bovina y la IA fue una importante herramienta para combatir la transmisión de la durina, enfermedad causada por el *Trypanosoma equiperdum* (Aurich, 2012).

En los últimos 25 años, esta biotecnología nuevamente ha ganado campo en la industria equina, destacándose su utilización en países como Alemania, Francia, Bélgica, Suiza, Holanda y España. No obstante, en contraste a la industria bovina, el uso de semen congelado equino no ha reemplazado totalmente el semen refrigerado, debido principalmente a la variabilidad de respuesta a la congelación entre sementales y a las diferencias en la fisiología reproductiva de la yegua, como un estro más largo, que disminuyen el éxito de IA con semen congelado (Katila, 2001; Aurich, 2012).

En los asnos, los espermatozoides han demostrado ser resistentes a los procesos de refrigeración y criopreservación manteniendo unas características aparentemente adecuadas de calidad seminal. La congelación de semen de burro ha constituido un objetivo primordial en los programas de conservación de especies amenazadas de burro con un escaso número de individuos, ya que permite establecer bancos de germoplasma que podrían ser utilizados en un futuro para reducir la depresión genética observada en estas poblaciones. Los estudios *in Vitro* con semen criopreservado de burro han demostrado que aunque existe variabilidad entre ejemplares, la viabilidad a la descongelación (24-62%) es similar al semen de caballo y diferentes crioprotectores han mostrado proteger los espermatozoides (Serres, 2003; Oliveira et al., 2006; Rota et al., 2008; Flores et al., 2008; Canisso et al., 2008; Miró et al., 2009). Así mismo, la capacidad de penetración de los espermatozoides de burro tras la descongelación en ovocitos desnudos de bovino, ha mostrado buenos resultados (Taberner et al., 2010). Sin embargo, tal y como afirman Martin y Morceau (2006), “A pesar de las analogías entre las dos especies de equidos, las técnicas utilizadas en el caballo y aplicadas al asno, no permiten la obtención de descendientes”. La inadecuada extrapolación de los protocolos de inseminación utilizados en yeguas, ha resultado en nulos o escasos índices de preñez en diferentes razas de burro. Se ha obtenido un 40-50% de fertilidad con semen congelado de burro para la obtención de mulas y de 0 a 11% cuando se inseminan burras utilizando diferentes crioprotectores (Álvarez, 2005; Oliveira, 2005; Oliveira et al., 2006; Vidament et al., 2009; Canisso et al., 2011). Trimeche et al (1998) afirman que obtienen un aumento de la fertilidad de hasta un 50%, eliminando el glicerol antes de la IA o usando yema de huevo de codorniz, no obstante, cuando se intenta repetir la misma experiencia los resultados son prácticamente nulos (Vidament et al., 2009). Por otro lado, Jepsen et al. (2010) afirman también obtener buenos resultados usando una concentración de yema de huevo al 5% en semen congelado con 2% de etilenglicol o utilizando yema de huevo al 20% con la adición de hidroxipropil β -ciclodextrina, aunque con idénticos tratamientos Álvarez (2005) obtiene pésimos resultados.

En el servicio de reproducción equina de la UAB, se han congelado 1968 pajuelas de 0,5 ml de 15 sementales catalanes distintos de fertilidad comprobada, con una media de espermatozoides vivos a la descongelación de 49,14%. En el año 2003 se obtuvo el primer pollino de burro catalán con semen congelado a nivel mundial (Jordana et al., 2010) y posteriormente se lograron 4 gestaciones en 6 burras realizando inseminación profunda con una sola pajuela de 0,5 ml depositada en la unión útero-tubárica (datos no publicados). Un estudio similar ha reportado recientemente el nacimiento de un burro con semen congelado utilizando inseminación profunda en Brasil (Oliveira et al., 2011) y los mismos autores lograron incrementar la tasa de preñez del semen congelado aumentando el número de inseminaciones y la concentración de espermatozoides depositados por inseminación profunda (Oliveira et al., 2012). Estos resultados parecen ofrecer alternativas para mejorar la fertilidad *in Vivo* del semen congelado en burros, sin embargo, aún no es posible determinar un protocolo de IA en el que se aseguren unos resultados de fertilidad en esta especie, ya que el éxito de la reproducción también obedece al factor hembra, un aspecto escasamente investigado.

1.3. Endometritis inducida por el semen

La endometritis post-inseminación o apareamiento es una respuesta fisiológica del endometrio en casi todas las hembras de mamífero, que facilita la fagocitosis y eliminación de contaminantes como bacterias, plasma seminal, diluyentes y espermatozoides no viables con el fin de restablecer el ambiente endometrial para maximizar las posibilidades de fecundación y viabilidad de la gestación (Troedsson et al., 2001). Las yeguas en estro, presentan una marginación de neutrófilos polimorfonucleares (PMN) en los vasos sanguíneos que solo tras la inseminación o monta, migran al tejido endometrial causando edema y liberación de mediadores inflamatorios principalmente vía ciclooxygenasa-2 (COX-2) desde los primeros 30 minutos de exposición al semen, con un pico a las 4-8 h que disminuye a las 12-24 h y posteriormente desaparece en un máximo de 48 h, con una completa limpieza del endometrio (Kotilainen et al., 1994; Katila, 1996). Independientemente de la calidad del eyaculado, los espermatozoides, reconocidos como antígenos dentro del

endometrio, son los principales responsables inductores de la respuesta inflamatoria mediante la activación del complemento (Rozeboom et al., 2001; Schuberth et al., 2008). La viabilidad, volumen, número de espermatozoides, presencia de bacterias u otros contaminantes y sitio de deposición del semen, son factores adicionales que modulan la intensidad de la respuesta (Kazim et al., 2005; Hunter et al., 2006; Fiala et al., 2007). Esta respuesta inmune innata supone un problema de fertilidad cuando tras continuas montas o inseminaciones, se desarrolla una respuesta inmune adquirida hacia los espermatozoides, se incrementa el tiempo de limpieza y por tanto, no es posible lograr la fecundación por la inviabilidad del ambiente uterino, desarrollándose entonces una endometritis persistente (Katila, 2012). Las alteraciones anatómicas, disfunción miometrial, contaminación bacteriana, cambios inflamatorios y degenerativos en el útero en yeguas de avanzada edad o que han sido sometidas a diversas montas o inseminaciones, son factores que predisponen el desarrollo de endometritis, ya que alteran los mecanismos de limpieza uterina intensificando la respuesta leucocitaria en el útero (Watson, 2000; Maloufi et al., 2002; Hurtgen, 2006).

Existen algunos trabajos que muestran diferencias en la fisiología reproductiva y anatomía del tracto genital de la burra en comparación con la yegua, por ejemplo, la conformación de un cérvix más largo y tortuoso que protruye hacia vagina y predispone a la presentación de distocias (Vendramini et al., 1998; Renner-Martin et al., 2009); además, la burra acumula menos líquido en endometrio durante el estro (Climent et al., 2012). Estas características pueden favorecer el desarrollo de endometritis post-inseminación, ya que comportan mecanismos de limpieza uterina diferentes a la yegua. Se han realizado pocas investigaciones sobre endometritis en la burra. Un único estudio determinó la apariencia histológica de endometrios de burra obtenidos en matadero (Sokkar et al., 2001), pero no se tenía conocimiento de la historia reproductiva y momento del ciclo estral. Otros estudios en burras han evaluado la respuesta inflamatoria post-inseminación con semen congelado mediante citología endometrial (Oliveira, 2005; Rota et al., 2012). No obstante, la fisiología de la inflamación compete a una serie de complejos mecanismos especie-

específicos que necesitan ser investigados con más profundidad para mejorar los resultados de IA con semen criopreservado en burros.

1.3.1. Diagnóstico de endometritis

El diagnóstico de la endometritis se suele realizar por la detección de fluido uterino mediante ecografía, presencia de vaginitis, descarga vaginal, periodos inter-estro acortados, citología o cultivo uterino. Sin embargo, algunas metritis subclínicas pueden pasar desapercibidas con las técnicas diagnósticas anteriores. Estos casos precisan de una mayor monitorización ecográfica post-inseminación para la detección de un edema uterino excesivo y la presencia de una línea blanca (hiperecogénica) entre los pliegues uterinos. La endoscopia uterina puede revelar lesiones focales invisibles a la ecografía, pero es una herramienta de accesibilidad limitada en campo (Card et al., 2004; Card, 2005; Overbeck et al., 2011).

La biopsia endometrial se considera la herramienta clave para el diagnóstico definitivo de la endometritis, ya que permite detectar inflamaciones profundas y cambios degenerativos a nivel microscópico que influyen directamente en el pronóstico (Shlafer, 2007; Snider et al., 2011). Palm et al. (2008) describen que la biopsia endometrial permite evaluación de la migración de PMN, mediadores inflamatorios y cambios degenerativos adicionales que no pueden ser vistos mediante un simple lavado uterino que, por si solo, no refleja adecuadamente la respuesta inflamatoria endometrial. No existen estudios para determinar los mejores métodos diagnósticos para la endometritis en burras, ya que hasta el momento se utilizan los protocolos establecidos en yeguas.

1.3.2. Tratamientos anti-inflamatorios

El control de la endometritis post-IA debe permitir la restauración del ambiente endometrial lo más rápido posible, para que el nuevo embrión que migra al útero al 5^o-6^o día, se establezca y comience su desarrollo (Katila, 2012). Aunque no existe una indicación terapéutica ampliamente aceptada en yeguas, se han obtenido

buenos resultados con la administración de diferentes anti-inflamatorios sistémicos durante este intervalo de tiempo (LeBlanc, 2010; Woodward et al., 2012). El tratamiento con corticoides ha demostrado favorecer las tasas de preñez en yeguas con PMIE tras la inyección de una dosis única en el momento de la inseminación (Bucca et al., 2008), aunque un trabajo reciente de Stout (2012), pone en duda la eficacia de los corticoides. El uso de anti-inflamatorios no esteroideos (AINEs) también ha mostrado resultados satisfactorios en yeguas con endometritis pos-IA (Risco et al., 2009; Aurich et al., 2010) y en yeguas receptoras para transferencia embrionaria (Koblischke et al., 2008). Teniendo en cuenta que no existe una dosificación determinada en burros, el tratamiento con AINEs puede considerarse más seguro, ya que estos medicamentos ofrecen un índice terapéutico mayor, sin el riesgo de presentación de los efectos adversos de los corticoides, como el desarrollo de laminitis y trastornos gastrointestinales observados en caballos y asnos (Mozaffari et al., 2010; Bailey, 2010).

1.3.3. El plasma seminal como modulador de la inflamación

Las continuas inseminaciones con semen criopreservado favorecen la inflamación persistente del endometrio. Este hecho se atribuye principalmente a dos características del semen congelado: (1) la adición de diluyentes o criopreservantes que pueden contener sustancias irritantes para el endometrio como la yema de huevo o el glicerol y (2) la ausencia del plasma seminal (PS) que debe ser eliminado durante el proceso de criopreservación (Jasko et al., 1992; Kotilainen et al., 1994; Troedsson et al., 2001; Watson et al., 2001; Serres, 2003; Barbacini et al., 2003; Katila, 2005; Miró et al., 2009). Sin embargo, el PS es una mezcla de iones, enzimas, monosacáridos, lípidos, poliaminas, aminoácidos, proteínas y hormonas específicas de cada especie que facilitan el transporte, protección, nutrición, capacitación y selección de espermatozoides (Portus et al., 2005; Robertson, 2005). Aunque no es absolutamente necesario para la fertilización, el PS también ha demostrado modificar la intensidad de la respuesta inflamatoria en diferentes especies (Troedsson et al., 2001; Troedsson et al., 2005), así como tener una influencia sobre la pre-implantación y la gestación temprana (O'Leary et al., 2004).

Actualmente, el conocimiento sobre efectos del PS y su relación con la fertilidad es causa de discusión (Kareskoski y Katila, 2008). Las investigaciones en PS han ganado particular interés en equinos y cerdos donde el eyaculado contiene grandes volúmenes de PS y el semen es depositado directamente en el útero a diferencia de otras especies como bovinos y humanos (Alghamdi et al., 2009; Katila, 2012). Troedsson et al. (2006) afirman que la adición del PS en las dosis de inseminación podría ser útil para mejorar los resultados de fertilidad en yeguas con un ambiente uterino inflamado. Las tasas de preñez en yeguas con endometritis inducida han incrementado tras la inseminación con espermatozoides suspendidos en PS comparado con un extender (77% vs. 5%) (Alghamdi et al., 2004) y un estudio en burros de raza Amiata también ha obtenido una tendencia al incremento en el índice de preñez cuando el semen congelado en glicerol fue resuspendido en PS tras la descongelación (Rota et al., 2012). No obstante, aún se desconocen los mecanismos concretos de acción del PS en burros y por tanto, la utilización del PS como modulador de la inflamación necesita ser estudiada con mayor detalle.



Objetivos / Aims

2. Objetivos / Aims

Esta tesis doctoral tuvo como objetivo general estudiar la endometritis inducida por la inseminación artificial (IA) con semen congelado/descongelado en el burro catalán y las posibilidades de control de dicha endometritis, para optimizar la aplicación de esta tecnología reproductiva como herramienta de conservación de la raza.

Objetivos específicos:

1. Caracterizar la celularidad predominante del endometrio en estro y post-IA con semen congelado/descongelado, así como evaluar la respuesta a un tratamiento anti-inflamatorio sistémico durante la IA con semen congelado/descongelado.
2. Determinar el efecto *in Vitro* del plasma seminal sobre la motilidad espermática y la interacción entre PMN-espermatozoides tras la IA con semen congelado/descongelado.
3. Determinar el efecto *in Vivo* del plasma seminal sobre la endometritis post-IA con semen congelado/descongelado.



Capítulos / Chapters

Capítulo I

Effect of ketoprofen treatment on the uterine inflammatory response after AI of jennies with frozen semen

K. Vilés^a, R. Rabanal^b, M. Rodríguez-Prado^c, J. Miró^a

^a Equine Reproduction Service, Department of Animal Medicine and Surgery, Faculty of Veterinary Medicine, Autonomous University of Barcelona, Spain

^b Center for Animal Biotechnology and Gene Therapy, Department of Animal Medicine and Surgery, Faculty of Veterinary Medicine, Autonomous University of Barcelona, Spain

^c Animal Nutrition, Management and Welfare Research Group, Department of Food and Animal Science, Faculty of Veterinary Medicine, Autonomous University of Barcelona, Spain

Received 9 October 2012; revised 7 January 2013; accepted 8 January 2013

Theriogenology 79 (2013): 1019-1026.



Contents lists available at SciVerse ScienceDirect

Theriogenology

journal homepage: www.theriojournal.com

Effect of ketoprofen treatment on the uterine inflammatory response after AI of jennies with frozen semen

K. Vilés^a, R. Rabanal^{a,b}, M. Rodríguez-Prado^c, J. Miró^{a,*}

^a Equine Reproduction Service, Department of Animal Medicine and Surgery, Faculty of Veterinary Medicine, Autonomous University of Barcelona, Barcelona, Spain

^b Center for Animal Biotechnology and Gene Therapy, Department of Animal Medicine and Surgery, Faculty of Veterinary Medicine, Autonomous University of Barcelona, Barcelona, Spain

^c Animal Nutrition, Management and Welfare Research Group, Department of Food and Animal Science, Faculty of Veterinary Medicine, Autonomous University of Barcelona, Barcelona, Spain

ARTICLE INFO

Article history:

Received 9 October 2012

Received in revised form 7 January 2013

Accepted 8 January 2013

Keywords:

Donkey

Jenny

Sperm-induced endometritis

Ketoprofen

Frozen-thawed semen

ABSTRACT

Artificial insemination (AI) involving the placing of frozen-thawed semen directly into the jenny uterine body is associated with very low pregnancy rates. This might be because of an exacerbation of the acute response of the endometrium to sperm, as seen in mares with persistent induced mating endometritis. Pregnancy rates can be increased in such mares, however, by including anti-inflammatory treatments in the insemination protocol (Bucca S, Carli A, Buckley T, Dolci G, Fogarty U. The use of dexamethasone administered to mares at breeding time in the modulation of persistent mating induced endometritis. *Theriogenology* 2008;70:1093–100; Rojer H, Aurich C. Treatment of persistent mating-induced endometritis in mares with the non-steroid anti-inflammatory drug vedaprofen. *Reprod Domest Anim* 2010;45:e458–60). To investigate the endometritis caused by the use of frozen-thawed semen in jennies, and to assess the response to ketoprofen treatment, endometrial cytological samples and biopsies from six healthy jennies were examined in a crossover design experiment. Samples were taken from jennies in estrus (E; control) and at 6 hours after AI with or without ketoprofen (+K and –K, respectively). Ketoprofen was administered iv 24 hours before and for 4 days after insemination (total = 2.2 mg/kg/24 hours for 5 days). All animals showed a severe inflammatory response to semen deposition. Polymorphonuclear neutrophil numbers in the cytological smears and biopsies differed significantly between the +K and E animals. No significant differences were recorded, however, between the +K and –K treatments. Eosinophils were observed in all sample types from all groups; these cells appear to be a feature of the normal jenny endometrium. Slight fibrosis was observed in some biopsies, but no significant relationship with inflammation was found. Intense cyclooxygenase-2 (COX-2) immunohistochemical labeling was detected in the –K biopsies. Less intense labeling was seen in those of the +K animals, and mainly localized in the stratum compactum. No differences in COX-2 labeling were observed between the +K and E animals. Plasma concentrations of ketoprofen remained detectable until 2 hours after administration, after which the compound was rapidly eliminated. In summary, jennies are susceptible to endometritis after insemination with frozen-thawed semen. Ketoprofen reduces this inflammation by inhibiting COX-2; no reduction in the number of polymorphonuclear neutrophils occurs. The physiological and pharmacological characteristics of jennies should be taken into account when designing treatments for acute endometritis aimed at enhancing pregnancy rates after insemination with frozen-thawed sperm.

© 2013 Elsevier Inc. All rights reserved.

* Corresponding author. Tel.: +34 935 814273; fax: +34 935 812 006.

E-mail address: jordi.miro@uab.cat (J. Miró).

1. Introduction

In mammals, endometritis is commonly seen after artificial insemination (AI). Indeed, it might also occur after natural mating [1–3]. In mares, the small population of polymorphonuclear neutrophils (PMN) that develops after ovulation is released into the endometrium approximately 30 minutes after mating, attracted by the deposited sperm. Normally, the number of infiltrating PMN peaks at 6 to 12 hours, and decreases to preovulation levels within 48 hours [4–7]. However, some mares develop persistent mating-induced endometritis (PMIE) in which PMN are always present in the endometrium. This is associated with reduced fertility and embryo survival [8]. A persistent inflammatory response is also commonly observed when frozen-thawed semen is used in AI [1,2,9–11]. Apart from the presence of the sperm itself, this has been attributed to the removal of immunomodulatory proteins in the seminal plasma during the process of cryopreservation [12–14], and to allergic-type hypersensitivity reactions to extenders (e.g., glycerol and egg yolk) [2,13,15,16]. Histological, anatomical, and physiological conditions that result in delayed uterine clearance also predispose mares to endometritis after mating [6,15,17,18].

In estrus, the presence of uterine fluid (reflected as a uterine lumen 2 mm across, as determined by ultrasonography) and its remaining for more than 24 hours after insemination, is a predictor of susceptibility to endometritis in mares [10,19]. Large numbers of PMN in the inseminated uterus also provide a major indicator of acute endometritis, and the examination of endometrial cytological smears is commonly used to provide a rapid diagnosis under field conditions [20–23]. However, endometrial inflammation and fibrosis are critical markers of endometritis and a full histological evaluation of an endometrial biopsy provides a more reliable diagnosis [17,24–27]. The signs of inflammation associated with endometritis show it to be a complex pathological process involving the cellular and humoral responses. Some immunohistochemical studies have detected the presence of inflammatory enzymes such as cyclooxygenase-2 (COX-2) in the endometrium, providing a better understanding of the inflammatory mechanisms involved in endometritis [28].

The oviductal phase of embryonic development does not end until approximately Day 5 or 6 after ovulation. Uterine inflammation must therefore be controlled for the first 96 hours to increase the chances of embryo survival [5,29,30]. Different treatments for endometritis that focus on this interval have been described for mares. The administration of anti-inflammatory corticoid agents can increase pregnancy rates in PMIE-susceptible mares [31] but it might also contribute to laminitis [32]. Nonsteroidal anti-inflammatory drugs (NSAIDs) seem to be safe and are effective inhibitors of endometrial inflammation in recipients carrying luteal phase embryos [33]. Their use is also associated with higher pregnancy rates in mares with a history of PMIE [34]. Ketoprofen is a potent NSAID inhibitor of COX-2 that belongs to the 2-arylpropionic acid group. It has been associated with maximum inhibition of inflammation at 4 to 8 hours in endometritis in mares [35]. However, because little information is available regarding

the pharmacokinetics of most drugs in jennies, the intravenous dose for mares (2.2 mg/kg/body weight daily for at least 5 days) is usually used [36]. Compared with other NSAIDs, ketoprofen has fewer adverse effects, and is reported to have a high therapeutic index in horses and donkeys [37,38].

The increasing use of frozen-thawed semen has stimulated research into the underlying etiology and treatment of postmating endometritis in subfertile mares [15]. However, though donkeys have been gaining in importance as companion, pack, and draught animals in some countries, the AI protocols followed with these animals are usually those designed for mares—and they return disappointing results [39–41].

Cryopreserved donkey jack semen has good post-thaw viability and motility [42–44]. However, the ability of jennies to conceive after insemination with such frozen-thawed semen is poorer than in mares [39,41,45,46]. In part this might be associated with the anatomical and physiological differences in their reproductive tracts [47–51]. In addition, large numbers of PMN have been observed 6 hours after the insemination of jennies with frozen-thawed semen [44,52]. The study of endometritis and its treatment in donkeys might improve the success of reproductive technologies in this species. The aim of the present work was to analyze the inflammatory response that occurs after the insemination of jennies with frozen-thawed semen, and to examine the anti-inflammatory effect of ketoprofen on the endometrium via the analysis of endometrial cytological smears, biopsies, and COX-2 labeling.

2. Materials and methods

2.1. Experimental design

The present work was approved by the institutional Ethics Committee on Animal and Human Experimentation.

The animals studied were six healthy, female, Catalan donkeys (*Equus asinus*) aged 5 to 10 years, of proven fertility, with no reproductive alterations and no endometrial infection (determined by swab culture during estrus). Animals were fed 2 kg of concentrate per day and had free access to hay, straw, and water.

Following a crossover experimental design, the six jennies were subjected to: (1) no treatment (all animals were in estrus [E; control]); (2) AI but with no administration of ketoprofen (–K); and (3) AI with the administration of ketoprofen (+K). The animals of this group were administered 2.2 mg/kg/day Ketofen 10% (Merial, Lyon, France) iv (jugular) 24 hours before insemination, and then every day for the next 4 days. Before crossover between treatments, all animals passed through an estrus cycle with no treatment. Blood samples were taken from all +K animals to determine the pharmacokinetics of ketoprofen.

Estrus was identified by its symptoms (chewing, mounting, laid back ears, constant urination), transrectal palpation, and ultrasound using a 5-MHz linear transducer (Esaote MyLab30; VET, Genoa, Italy) to check for uterine edema and follicle growth (detection of >38 mm diameter follicle in the absence of a corpus luteum). Ovulation was

induced by the administration of 2000 IU human chorionic gonadotrophin (HCG 2000 UI; Chorulon; Intervet, Vienna, Austria) iv; 30 hours later all animals in all groups were subjected to cytological smear collection and endometrial biopsy. Before insemination in the –K and +K groups, and for cytology and biopsy sampling, the vulva and perineal region were rinsed with water, cleaned with dry paper, and the tail covered with a disposable examination glove. Inseminations were performed 24 hours after administering hCG, depositing 8×0.5 mL French straws of frozen-thawed donkey semen (each containing approximately 200×10^6 sperm/mL) into the uterine body via an equine insemination catheter (Minitübe, Tiefenbach, Germany). All straws contained semen (total motility $\geq 70\%$, progressive motility $\geq 40\%$, viability ≥ 50) from the same male donor. Ovulation and the disappearance of uterine fluid was checked by ultrasound 24 hours after insemination.

2.2. Experimental procedures

2.2.1. Collection of cytological samples

A guarded uterine swab (Equi-vet) was used to obtain an endometrial cytological smear as previously described [24]. A second cytological sample was obtained by low-volume uterine lavage via the infusion of 50 mL of Ringer Lactate through the cervix into the uterus using an equine insemination catheter. The uterus was massaged via the rectum and fluid aspirated back through the catheter, to recover approximately 10% of fluid. This sample was placed in a 10-mL conical tube, centrifuged at $660 \times g$ for 15 minutes, and the pellet was recovered and homogenized. The uterine swabs and low uterine lavage samples were smeared onto microscope glass slides, which were then air-dried and stained with Diff-Quick (Bio-Optica, Milan, Italy). Differential counting of at least 200 cells (PMN, other inflammatory cells, and endometrial cells) was performed under an optical microscope (Carl Zeiss) at magnification $\times 1000$. Polymorphonuclear neutrophil percentages were scored as: $<5\%$, noninflammatory; 5% to 15%, mild acute inflammation; 15% to 30%, moderate inflammation; and $>30\%$, severe inflammation [20,22].

2.2.2. Collection of endometrial biopsies

After separation of the vulvar labia, a sterilized Hauptner biopsy punch covered with a sterile glove was introduced through the vagina and placed in the caudal part of the cervical canal. The tip of a biopsy punch was inserted through the glove into the uterus lumen. A biopsy was taken from the anterior part of the uterine body and stored in 10% neutral buffered formalin for transfer to our institution's diagnostic laboratory. After embedding in paraffin, tissue sections were processed routinely for hematoxylin and eosin staining. Five fields with no artifacts were selected per sample using an optical microscope (Carl Zeiss, Germany) at magnification $\times 400$, and the intact blood vessels and epithelia were examined. The inflammatory pattern, localization, and numbers of PMN and other leukocytes were recorded, and means calculated [26,53]. Fibrosis was scored in terms of the thickness of the fibroblast cell layers

surrounding the glands: 0, absent; 1 to 3, mild; 4 to 10, moderate; and ≥ 11 , severe [25]. Other degenerative changes were recorded using the Kenney and Doig [54] classification for mare endometritis.

2.2.3. Immunohistochemical labeling

The detection of COX-2 was performed using a standard streptavidin-avidin-biotin immunoperoxidase technique. Biopsy sections (5 μm thick) were deparaffinized and endogenous peroxidase activity was blocked by exposure to 3% H_2O_2 in distilled water for 5 minutes. Heat-induced epitope retrieval was performed at 90 °C to 100 °C in citrate buffer (pH 6.0) for 10 minutes followed by 30 minutes of cooling at room temperature. Nonspecific protein binding was blocked with 2% bovine serum albumin (Sigma-Aldrich, St. Louis, MO, USA). The sections were incubated overnight at 4 °C with a polyclonal rabbit anti-murine COX-2 antibody (Cayman Chemical, Ann Arbor, MI, USA) diluted 1:500, and then washed with PBS three times for 5 minutes each. The slides were then incubated with biotinylated polyclonal goat anti-rabbit secondary antibody (Dako, Glostrup, Denmark) for 1 hour, and then with an avidin-biotin-peroxidase complex (ImmunoPure; Thermo Fisher Scientific, Rockford, IL, USA) for 1 hour. Labeling was visualized with 3,3'-diaminobenzidine tetrahydrochloride (Sigma-Aldrich, Madrid, Spain); counterstaining was performed with Mayer's hematoxylin. Negative control sections for each endometrial sample were prepared with normal rabbit serum in place of the primary antiserum. Sections of canine squamous cell carcinoma were used as positive controls [55]. The anti-COX-2 reagent used in this study has been shown to detect COX-2 in equine epidermal cells in areas below superficial erosion or ulceration in cutaneous malignant melanoma and squamous cell carcinoma.

Five randomly selected fields were examined using a light microscope (Carl Zeiss) at magnification $\times 400$ and the number of COX-2-positive cells were counted. The scoring system proposed by Jiwakanon et al. [56] was used to record the COX-2-positive cell numbers, staining intensity, and localization in the different endometrial layers.

2.2.4. Ketoprofen pharmacokinetics

A 14-ga, 140-mm long intravenous catheter (Abbocath-T) was placed in the jugular vein (opposite to the one used for ketoprofen administration) of all +K animals. The catheter was flushed with heparinized physiological saline after each blood sampling. The first 10 mL of blood was always discarded. Blood samples (10 mL) were collected in Venject vacuum tubes (Kimble-Terumo) containing lithium heparin as an anticoagulant before drug administration (Time 0) and at 5, 10, 15, 20, 30, and 45 minutes, and at 1, 1.5, 2, 3, 4, 5, 6, 8, and 12 hours, and before the ketoprofen administrations at 24, 48, and 72 hours. Plasma was separated by centrifugation at $2000 \times g$ for 10 minutes at 4 °C and stored at –20 °C until analysis by high performance liquid chromatography (detection limit 0.05 $\mu\text{g}/\text{mL}$). Pharmacokinetic variables were calculated using standard noncompartmental analysis equations.

2.2.5. Statistics

Continuous variables are expressed as mean \pm SEM and discrete variables as median \pm SEM. Because not all datasets were normally distributed (as determined by the Shapiro-Wilk test), the nonparametric Kruskal-Wallis test was used to examine differences between groups. When significant differences were observed, data were rank-transformed for subsequent analysis. Means were compared using the Tukey-Kramer procedure. The Spearman correlation test was used to determine relationships between cytological, biopsy, and immunohistochemical variables. Significance was set at $P \leq 0.05$ for all tests. All calculations were performed using SAS version 9.2 software (SAS Institute Inc., Cary, NC, USA).

3. Results

3.1. Cytological assessment

No significant differences were observed in the proportion of PMN between the results acquired by the uterine swab and uterine lavage methods. No difference was seen between the $-K$ and $+K$ groups with respect to the number of PMN, although differences were seen between the $+K$ and E animals ($P < 0.0001$) (Table 1). Red blood cells were detected in six of the 15 samples (40%) obtained by uterine lavage.

3.2. Biopsy assessment

The inflammatory pattern was characterized mainly by the diffuse infiltration of PMN in the luminal epithelium and stratum compactum, along with eosinophils in the stratum compactum and spongiosum surrounding the endometrial glands. The E group returned a mean of 1.40 ± 0.62 for PMN and 23.56 ± 13.43 for eosinophils, the $-K$ group returned a mean of 85.20 ± 9.11 for PMN and 24.00 ± 14.13 for eosinophils, and the $+K$ group returned a mean of 117.28 ± 13.75 for PMN and 56.44 ± 31.43 for eosinophils. The differences between the PMN for the E and the $-K$ groups and E and $+K$ groups was significant ($P = 0.0002$ and $P = 0.005$ respectively), and the difference between the $-K$ and $+K$ groups was not (Fig. 1).

Fibrosis was evaluated in all samples ($N = 15$); 86.66% ($N = 13$) were classified as absent (60%) or as showing slight endometritis (with only 1 fibroblast layer involved [26.66%]). Two biopsy samples showed mild fibrosis (13.33%). No significant differences were detected between the treatment groups with respect to the presence of fibrosis.

Table 1

Percentages of PMN, LYM, MON, EOS, and END in endometrial cytology at estrus, and 6 hours after insemination with and without previous administration of ketoprofen.

Treatment	Cytology counting (%)				
	PMN	LYM	MON	EOS	END
E	1.53 ± 0.49^a	0.52 ± 0.52^a	1.4 ± 0.60^a	0.22 ± 0.17^a	96.54 ± 1.39^a
$-K$	87.74 ± 6.14^b	0.04 ± 0.04^b	0.28 ± 0.15^b	0.54 ± 0.19^b	11.09 ± 6.01^b
$+K$	94.15 ± 1.87^b	0.06 ± 0.06^b	0.49 ± 0.34^b	0.96 ± 0.54^b	4.46 ± 1.50^b

Mean \pm SEM. Different superscript letters in the same column indicate significant differences (a and b).

Abbreviations: +, with; -, without; E, estrus; END, endothelial cells; EOS, eosinophils; K, ketoprofen; LYM, lymphocytes; MON, monocytes; PMN, polymorphonuclear neutrophils.

3.3. Immunohistochemistry

Cyclooxygenase-2 labeling was localized to the luminal epithelium and glandular cells of the stratum compactum; none was seen in the stratum spongiosum. The mean number of COX-2-positive epithelial cells per five vision fields in the E group was 3.00 ± 0.77 ; in the $-K$ group it was 49.84 ± 14.88 , and it was 15.24 ± 8.45 in the $+K$ group. The difference between the number of COX-2-labeled cells in the E and $-K$ groups was significant ($P = 0.01$) and that between the E and $+K$ group was not ($P = 0.68$); neither was the difference between the $-K$ and $+K$ groups ($P = 0.06$) (Fig. 2). Similarly, the scores (number, intensity, localization) for COX-2 showed differences between the E and $-K$ groups for the luminal epithelium ($P = 0.003$) and stratum compactum ($P = 0.0002$). The scores for the $+K$ group were lower than those of the $-K$ group, significantly so with respect to the stratum compactum ($P = 0.003$) although not with respect to the luminal epithelia ($P = 0.07$). No differences between the E and $+K$ groups were observed in any endometrial layer, indicating a reduction in inflammation compared with the $+K$ group (Table 2).

A moderately strong correlation was observed between the number of PMN in the cytological smears and biopsies ($r = 0.73$; $P = 0.001$). Number of PMN also correlated with the number of COX-2-positive cells ($r = 0.57$; $P < 0.03$). No other correlations between inflammatory variables were observed. Figure 3 shows representative images of a biopsy and a COX-2-positive slide for each group.

3.4. Ketoprofen pharmacokinetics

Figure 4 shows the mean plasma ketoprofen concentration over time in the $+K$ animals. The plasma half-life was 0.61 ± 0.06 hours, the mean residence time was 0.4 ± 0.02 hours, the apparent volume of distribution was 0.39 ± 0.07 L/kg, and the body clearance was 27.63 ± 5.40 L/kg/h.

4. Discussion

Endometritis is an inflammation that occurs even after normal mating. If it persists, however, the resulting environment is incompatible with the establishment of pregnancy [4,7,15]. The deposited semen is primarily responsible for the uterine inflammatory response, triggering the strong chemotaxis of PMN as well as cytokine expression soon after insemination [2,57–60]. The characteristics of frozen-thawed semen, such as the absence of seminal plasma and

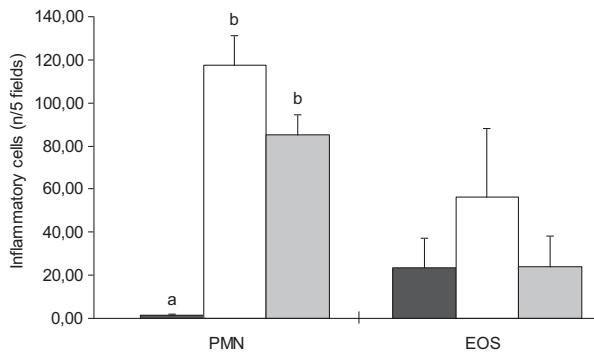


Fig. 1. Mean number of polymorphonuclear neutrophils (PMN) and eosinophils (EOS) in biopsies taken from five fields at estrus (black columns), 6 hours after artificial insemination with no ketoprofen treatment (white columns), and 6 hours after artificial insemination with ketoprofen treatment (gray column). Bars marked by different letters indicate significant differences ($P < 0.05$).

the addition of cryoprotectors that irritate the uterus, increase endometrial inflammation [9,59].

Uterine cytological smears can provide a rapid diagnosis of endometritis in mares, and this technique is commonly used as a field tool. The uterine swab and low volume uterine lavage techniques seem to be the best methods for obtaining representative cytological samples [20,22,61,62]. In the present study, these techniques returned similar results and were useful for evaluating the endometrial environment. Artifacts, such as red blood cells in uterine lavages were easily dismissed. In the E group of animals, the presence of endometrial cells, debris, and the finding of no or only occasional inflammatory cells were deemed signs of a healthy endometrium. In the -K and +K animal groups, the number of PMN increased dramatically after insemination, indicating acute endometritis. No infiltration of PMN was observed in E animal biopsies, but these inflammatory cells appeared after insemination in the -K and +K groups.

A slight increase in PMN in the endometrium is normal during estrus in mares; after insemination, however, these cells then become the most common type of cell observed

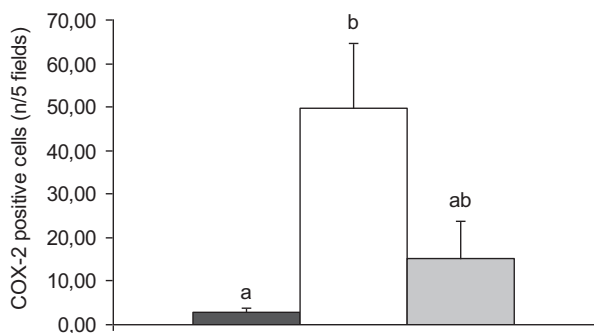


Fig. 2. Mean number of cyclooxygenase-2 (COX-2)-positive endometrial cells taken from five fields during estrus (black columns), 6 hours after artificial insemination with no ketoprofen treatment (white columns), and 6 hours after artificial insemination with ketoprofen treatment (gray columns). Bars marked by different letters indicate significant differences ($P < 0.05$).

Table 2

Cyclooxygenase-2 labeling scores in the different histological layers of the jenny endometrium in each experimental group: estrus, and 6 hours after insemination with and without previous administration of ketoprofen.

Treatment	Luminal epithelia	Stratum compactum	Stratum spongiosum
E	0 ± 0.40 ^a	0 ± 0.40 ^a	—
-K	6 ± 0.48 ^b	4 ± 0.48 ^b	—
+K	2 ± 0.16 ^{a,b}	0 ± 0.48 ^a	—

Mean ± SEM. Superscript letters in the same column (a and b) indicate significant differences between treatments.

Abbreviations: +, with; -, without; E, estrus; K, ketoprofen.

in cytological smears [63]. No differences in numbers of PMN are observed between healthy mares subjected to AI and those that undergo natural service. However, persistently high numbers of PMN are characteristic when AI is performed in mares with PMIE [17,64].

The present results highlight the difficulty of treating the endometritis caused by frozen-thawed semen in jennies, and underscore the need to find better treatments for its control. The jenny endometrium showed a susceptibility to endometritis similar to that seen in mares, with accumulations of PMN in the stratum compactum remaining high even in the +K animals [15,63,64]. In mares, however, combined vedaprofen and oxytocin (ecbolic) treatment administered as part of the AI protocol is reported to satisfactorily reduce PMN infiltration and COX-2 expression [65]. Bucca et al. [31] reported an increase in PMN after mating in 100% of mares with PMIE, and an insufficient reduction in the number of these cells after dexamethasone (a non-NSAID) treatment administered as part of the AI protocol, although endometrial edema and the volume of uterine fluid were significantly reduced. Similar results were recently reported after administering dexamethasone 1 hour before AI, with a reduction in edema at 24 hours but no improvement in intrauterine fluid accumulation or infiltration of PMN [11]. In mares with PMIE, treatment with flunixin meglumine reduces numbers of PMN at 8 hours postinsemination but not at 25 hours in susceptible mares [66].

Interestingly, a moderate, diffuse infiltration of eosinophils in the stratum compactum was observed in all animals of all groups. In mares, eosinophils are released into the endometrium only in response to fungal growth, pneumovagina, or during anaphylactic responses [25,67]. One study in jennies reported eosinophils in the endometrium after slaughter, along with chronic degenerative alterations such as fibrotic nests with more than five layers of fibroblasts, gland necrosis, lymphatic lacunae, vasculitis with perivascular fibrosis, myometritis, and perimetritis [47]. No degenerative or other inflammatory changes were associated with the presence of eosinophils in the present study, nor were any of the conditions reported for mares [1] observed. The presence of eosinophils was therefore considered normal for the healthy jenny endometrium during estrus as well as after insemination.

In the present work, no—or only very weak—COX-2 labeling was observed in estrus, and intense diffuse COX-2 labelling was seen after AI, indicative of an acute inflammatory process. The +K animals showed less intense COX-2

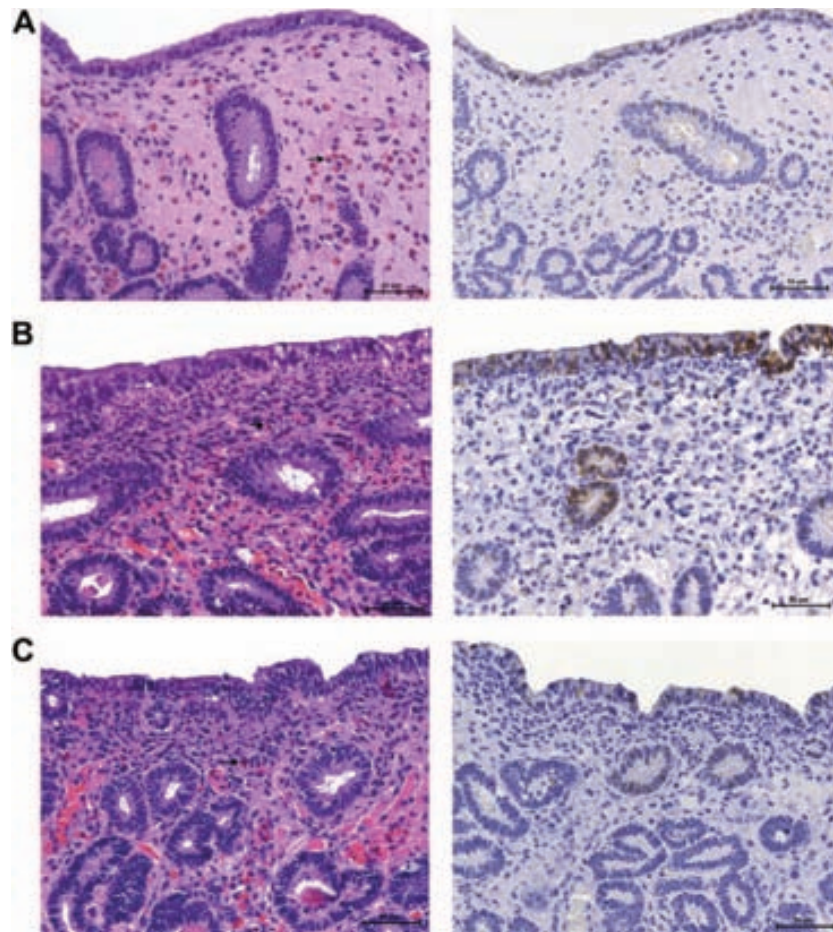


Fig. 3. Sections stained with hematoxylin and eosin, and cyclooxygenase-2 (COX-2) immunostaining, in jenny endometrial biopsies taken at oestrus (A), 6 hours after insemination with frozen semen but no ketoprofen treatment (B), and 6 hours after insemination with frozen semen plus ketoprofen treatment (C). Polymorphonuclear neutrophils (black arrows), eosinophils (white arrow). Different labeling of COX-2-positive cells (brown staining) can be appreciated in the luminal epithelia and glandular cells of the stratum compactum. Magnification $\times 400$. (Color version of Figure is available online).

labeling, although not significantly so compared with the $-K$ animals. Neither was any difference seen between the $K+$ and E animals; thus, the ketoprofen-induced reduction in COX-2 expression reached levels similar to control levels. Successful inhibition was confirmed in the stratum compactum in terms of COX-2 scoring; the effect was less intense, however, in the luminal epithelium. This localized inhibition of COX-2 might be caused by the glandular cells of the stratum compactum not being in direct contact with deposited sperm.

Cyclooxygenase-2 labeling and PMN influx were moderately correlated, as described in inseminated gilts [68]. After cell injury the arachidonic acid cascade is activated, and a series of eicosanoids are produced via the action of COX-2 [16]. These (and perhaps other) inflammatory mediators stimulate migration of PMN and their activity [4,58–60].

Cyclooxygenase inhibition is widely accepted as the main mechanism of NSAID therapeutic activity [69], but the inhibition of β -glucuronidase (which is produced by neutrophils and is a marker of their activation) in inflammatory exudates by ketoprofen has also been reported in horses [70]. The latter mechanism needs to be studied in more detail in jennies.

The present results show marked differences in the metabolism, elimination, and distribution of ketoprofen in donkeys compared with horses. Although some authors report the opposite [71], in the present work ketoprofen could only be detected in plasma for 2 hours after its administration, indicating it to undergo rapid metabolism and to have a shorter plasma half-life than in horses [35,36,71]. Such rapid elimination and clearance might be associated with a poor tissular distribution. In contrast, plasma concentrations of carprofen, another NSAID of the same molecular family as ketoprofen, remains detectable in donkeys for more than 48 hours after a single injection iv, with elimination and clearance poor compared with horses. Both species show poor tissular distribution, although poorer in the jenny [72]. Nonsteroidal anti-inflammatory drugs are known for their binding to plasma proteins after administration, but differences between species, and differences between drugs of the same class, have been documented [35]. Greater plasma protein binding might occur in jennies compared with horses, leading to poorer drug distribution in the tissues and more rapid elimination.

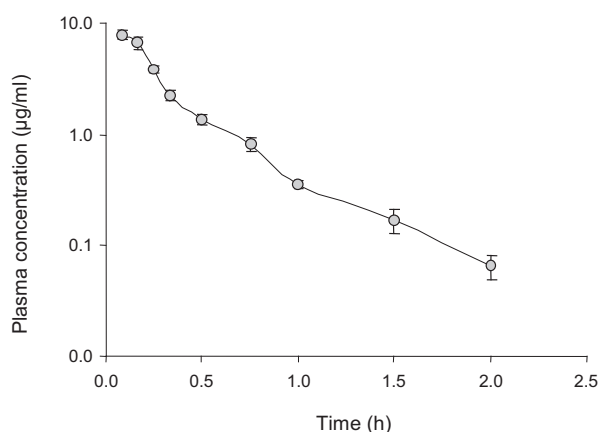


Fig. 4. Mean blood plasma concentrations of ketoprofen in six donkeys after ketoprofen administration (2.2 mg/kg iv).

Finally, differences in the anatomy and physiology of the mare and jenny reproductive tract might, in part, predispose the jenny to endometrial inflammation after insemination with frozen-thawed semen. Certainly, jennies have a relatively longer cervix with more tortuous folds [49,50,73], and ultrasonography shows less endometrial edema in jennies during estrus [51].

4.1. Conclusions

Although ketoprofen treatment did not significantly reduce PMN infiltration after insemination, a reduction in COX-2 expression—mainly in the stratum compactum—indicates that ketoprofen has some anti-inflammatory effect on the jenny endometrium. Thus, the provision of anti-inflammatory treatment to jennies as part of AI protocols might help reduce the endometritis induced by frozen-thawed semen, improving the pregnancy rate. The cellular features of the endometrium, its inflammatory responses, and drug availability in the jenny should all be taken into account when designing such treatment. In future work, the effect of combined anti-inflammatory treatments should be investigated.

References

- [1] Kotilainen T, Huhtinen M, Katila T. Sperm-induced leukocytosis in the equine uterus. *Theriogenology* 1994;41:629–36.
- [2] Troedsson MH, Loset K, Alghamdi AM, Dahms B, Crabo BG. Interaction between equine semen and the endometrium: the inflammatory response to semen. *Anim Reprod Sci* 2001;68:273–8.
- [3] Troedsson MH. Breeding-induced endometritis in mares. *Vet Clin North Am Equine Pract* 2006;22:705–12.
- [4] Katila T. Uterine defence mechanisms in the mare. *Anim Reprod Sci* 1996;42:197–204.
- [5] Katila T. Sperm-uterine interactions: a review. *Anim Reprod Sci* 2001;68:267–72.
- [6] Maischberger E, Irwin J, Carrington S, Duggan V. Equine post-breeding endometritis: a review. *Ir Vet J* 2008;61:163–8.
- [7] Katila T. Post-mating inflammatory responses of the uterus. *Reprod Domest Anim* 2012;47:31–41.
- [8] Maloufi F, Pierson R, Otto S, Ball C, Card C. Mares susceptible or resistant to endometritis have similar endometrial echographic and inflammatory cell reactions at 96 hours after infusion with frozen semen and extender. In: AAEP editor. Proceedings of the 48th Annual Convention of the American Association of Equine Practitioners. Orlando, Florida, USA: IVIS; 2002. p. 51–7.
- [9] Kazim G, Reilas T, Katila T. Effect of frozen semen on the uterus of mares with pathological uterine changes. *Reprod Nutr Dev* 2004;44:243–50.
- [10] Watson ED, Barbacini S, Berrocal B, Sheerin O, Marchi V, Zavaglia G, et al. Effect of insemination time of frozen semen on incidence of uterine fluid in mares. *Theriogenology* 2001;56:123–31.
- [11] Stout T, Ruitjer-Villani M. Effect of post-breeding dexamethasone treatment on the uterine inflammatory reaction in the mare. *Reprod Domest Anim* 2012;47:60.
- [12] Alghamdi AS, Foster DN, Troedsson MH. Equine seminal plasma reduces sperm binding to polymorphonuclear neutrophils (PMNs) and improves the fertility of fresh semen inseminated into inflamed uteri. *Reproduction* 2004;127:593–600.
- [13] Palm F, Walter I, Budik S, Aurich C. Influence of different semen extenders and seminal plasma on the inflammatory response of the endometrium in oestrous mares. *Anim Reprod Sci* 2006;94:286–9.
- [14] Schuberth HJ, Taylor U, Zerbe H, Waberski D, Hunter R, Rath D. Immunological responses to semen in the female genital tract. *Theriogenology* 2008;70:1174–81.
- [15] Watson ED. Post-breeding endometritis in the mare. *Anim Reprod Sci* 2000;60–61:221–32.
- [16] Jasko DJ, Little TV, Lein DH, Foote RH. Comparison of spermatozoal movement and semen characteristics with fertility in stallions: 64 cases (1987–1988). *J Am Vet Med Assoc* 1992;200:979–85.
- [17] Woodward EM, Christoffersen M, Campos J, Squires EL, Troedsson MH. Susceptibility to persistent breeding-induced endometritis in the mare: relationship to endometrial biopsy score and age, and variations between seasons. *Theriogenology* 2012;78:495–501.
- [18] Liu IKM, Troedsson MHT. The diagnosis and treatment of endometritis in the mare: yesterday and today. *Theriogenology* 2008;70:415–20.
- [19] Barbacini S, Necchi D, Zavaglia G, Squires EL. Retrospective study on the incidence of postinsemination uterine fluid in mares inseminated with frozen/thawed semen. *Journal of Equine Veterinary Science* 2003;23:493–6.
- [20] Card C. Post-breeding inflammation and endometrial cytology in mares. *Theriogenology* 2005;64:580–8.
- [21] Card C, Carley S, Green J, Chirino-Trejo M. Endometrial cytology in mares bred with frozen semen. In: AAEP editor. Proceedings of 50th Annual Convention of the American Association of Equine Practitioners. Denver, Colorado, USA: IVIS; 2004. p. 1491, 1204.
- [22] Cocchia N, Paciello O, Auletta L, Uccello V, Silvestro L, Mallardo K, et al. Comparison of the cytobrush, cottonswab, and low-volume uterine flush techniques to evaluate endometrial cytology for diagnosing endometritis in chronically infertile mares. *Theriogenology* 2012;77:89–98.
- [23] Nash DM, Sheldon IM, Herath S, Lane EA. Endometrial explant culture to study the response of equine endometrium to insemination. *Reprod Domest Anim* 2010;45:670–6.
- [24] Nielsen JM. Endometritis in the mare: a diagnostic study comparing cultures from swab and biopsy. *Theriogenology* 2005;64:510–8.
- [25] Snider TA, Sepoy C, Holyoak GR. Equine endometrial biopsy reviewed: observation, interpretation, and application of histopathologic data. *Theriogenology* 2011;75:1567–81.
- [26] Schlafer DH. Equine endometrial biopsy: enhancement of clinical value by more extensive histopathology and application of new diagnostic techniques? *Theriogenology* 2007;68:413–22.
- [27] Nielsen JM, Troedsson MH, Pedersen MR, Bojesen AM, Lehn-Jensen H, Zent WW. Diagnosis of endometritis in the mare based on bacteriological and cytological examinations of the endometrium: comparison of results obtained by swabs and biopsies. *Journal of Equine Veterinary Science* 2010;30:27–30.
- [28] Palm F, Walter I, Budik S, Kolodziejek J, Nowotny N, Aurich C. Influence of different semen extenders and seminal plasma on PMN migration and on expression of IL-1 β , IL-6, TNF- α and COX-2 mRNA in the equine endometrium. *Theriogenology* 2008;70:843–51.
- [29] LeBlanc MM, Causey RC. Clinical and subclinical endometritis in the mare: both threats to fertility. *Reprod Domest Anim* 2009;44(Suppl. 3):10–22.
- [30] Hurtgen J. Pathogenesis and treatment of endometritis in the mare: a review. *Theriogenology* 2006;66:560–6.
- [31] Bucca S, Carli A, Buckley T, Dolci G, Fogarty U. The use of dexamethasone administered to mares at breeding time in the modulation of persistent mating induced endometritis. *Theriogenology* 2008;70:1093–100.
- [32] Bailey SR. Corticosteroid associated laminitis. *Vet Clin North Am Equine Pract* 2010;26:277–85.

- [33] Koblischke P, Kindahl H, Budik S, Aurich J, Palm F, Walter I, et al. Embryo transfer induces a subclinical endometritis in recipient mares which can be prevented by treatment with non-steroid anti-inflammatory drugs. *Theriogenology* 2008;70:1147–58.
- [34] Rojer H, Aurich C. Treatment of persistent mating-induced endometritis in mares with the non-steroid anti-inflammatory drug vedaprofen. *Reprod Domest Anim* 2010;45:e458–60.
- [35] Landoni MF, Lees P. Pharmacokinetics and pharmacodynamics of ketoprofen enantiomers in the horse. *J Vet Pharmacol Ther* 1996;19:466–74.
- [36] Landoni MF, Lees P. Influence of formulation on the pharmacokinetics and bioavailability of racemic ketoprofen in horses. *J Vet Pharmacol Ther* 1995;18:446–50.
- [37] Mozaffari AA, Derakhshanfar A, Alinejad A, Morovati M. A comparative study on the adverse effects of flunixin, ketoprofen and phenylbutazone in miniature donkeys: haematological, biochemical and pathological findings. *N Z Vet J* 2010;58:224–8.
- [38] Moses VS, Bertone AL. Nonsteroidal anti-inflammatory drugs. *Vet Clin North Am Equine Pract* 2002;18:21–37. vii.
- [39] Vidament M, Vincent P, Martin F, Magistrini M, Blesbois E. Differences in ability of jennies and mares to conceive with cooled and frozen semen containing glycerol or not. *Anim Reprod Sci* 2009;112:22–35.
- [40] Oliveira J, Ozanam F, Monteiro J, Marini C, Alvarenga M. Nascimento do primeiro jumento a partir de espermatozoides congelados no Brasil. In: Alvarenga MA, Piotto SB, Silveira GE editors. Proceedings of the XII Conferência Anual da ABRAVEQ, Campinas, São Paulo, Brasil: Equina. Brazilian Journal of Equine Medicine; 2011. p. 203.
- [41] Oliveira JV, Papa FO, Melo Oña CM, Monteiro GA, Puoli-Filho JNP, Alvarenga MA. New procedures to freeze donkey semen and its influence on mares and jennies fertility. *Journal of Equine Veterinary Science* 2012;32:503–4.
- [42] Rota A, Magelli C, Panzani D, Camillo F. Effect of extender, centrifugation and removal of seminal plasma on cooled-preserved amiated donkey spermatozoa. *Theriogenology* 2008;69:176–85.
- [43] Flores E, Taberner E, Rivera MM, Peña A, Rigau T, Miró J, et al. Effects of freezing/thawing on motile sperm subpopulations of boar and donkey ejaculates. *Theriogenology* 2008;70:936–45.
- [44] Rota A, Panzani D, Sabatini C, Camilo F. Donkey jack (*Equus asinus*) semen cryopreservation: studies of seminal parameters, post-breeding inflammatory response, and fertility in donkey jennies. *Theriogenology* 2012;78:1846–54.
- [45] Glatzel P, Houssain KE, Tibary A. Pferde- und Eselhengste der marokkanischen Landespferde- und Maultierzucht. Erste Ergebnisse aus dem Einsatz von Flüssig- und Gefriersamen für die Maultierproduktion. *Berl Munch Tierarztl Wochenschr* 1982;94:445–8.
- [46] Canisso IF, Carvalho GR, Morel MD, Ker PG, Rodrigues AL, Silva EC, et al. Seminal parameters and field fertility of cryopreserved donkey jack semen after insemination of horse mares. *Equine Vet J* 2011;43:179–83.
- [47] Sokkar SM, Hamouda MA, El-Rahman SM. Endometritis in she donkeys in Egypt. *J Vet Med B Infect Dis Vet Public Health* 2001;48:529–36.
- [48] Taberner E, Medrano A, Peña A, Rigau T, Miró J. Oestrus cycle characteristics and prediction of ovulation in catalonian jennies. *Theriogenology* 2008;70:1489–97.
- [49] Renner-Martin TF, Forstenpointner G, Weissengruber GE, Eberhardt L. Gross anatomy of the female genital organs of the domestic donkey (*Equus asinus* Linné, 1758). *Anat Histol Embryol* 2009;38:133–8.
- [50] Vendramini O, Guintard C, Moreau J, Tainturier D. Cervix conformation: a first anatomical approach in baudet du poitou jenny asses. 1998;66:741–744.
- [51] Climent F, Vilés K, Miró J. Vaginoplastia in two young infertile Catalan jennies. A clinical case. *Reprod Dom Anim* 2012;47(Suppl. 3):113.
- [52] Miró J, Vilés K, Fernández M, Fábregas N, Soares J, García W. Induced acute endometritis by frozen semen insemination in donkey. *Anim Reprod Sci* 2011;46(Suppl. 3):130.
- [53] Fiala SM, Pimentel CA, Mattos AL, Gregory RM, Mattos RC. Effect of sperm numbers and concentration on sperm transport and uterine inflammatory response in the mare. *Theriogenology* 2007;67:556–62.
- [54] Kenney R, Doig P. Equine endometrial biopsy. *Theriogenology* 1986;2:723–9.
- [55] Bardagi M, Fondevila D, Ferrer L. Immunohistochemical detection of COX-2 in feline and canine actinic keratoses and cutaneous squamous cell carcinoma. *J Comp Pathol* 2012;146:11–7.
- [56] Jiwakanon J, Persson E, Berg M, Dalin A. Influence of seminal plasma, spermatozoa and semen extender on cytokine expression in the porcine endometrium after insemination. *Anim Reprod Sci* 2011;123:210–20.
- [57] Rozeboom KJ, Rocha-Chavez G, Troedsson MH. Inhibition of neutrophil chemotaxis by pig seminal plasma in vitro: a potential method for modulating post-breeding inflammation in sows. *Reproduction* 2001;121:567–72.
- [58] Matthijs A, Engel B, Woelders H. Neutrophil recruitment and phagocytosis of boar spermatozoa after artificial insemination of sows, and the effects of inseminate volume, sperm dose and specific additives in the extender. *Reproduction* 2003;125:357–67.
- [59] Gorgens A, Leibold W, Klug E, Schubert HJ, Martinsson G, Zerbe H. Inseminate components are modulating the chemotactic activity of uterine polymorphonuclear granulocytes (PMN) of mares. *Anim Reprod Sci* 2005;89:308–10.
- [60] Eisenbach M. Why are sperm cells phagocytosed by leukocytes in the female genital tract? *Med Hypotheses* 2003;60:590–2.
- [61] Overbeck W, Witte TS, Heuwieser W. Comparison of three diagnostic methods to identify subclinical endometritis in mares. *Theriogenology* 2011;75:1311–8.
- [62] LeBlanc MM, Magsig J, Stromberg AJ. Use of a low-volume uterine flush for diagnosing endometritis in chronically infertile mares. *Theriogenology* 2007;68:403–12.
- [63] Summerfield NJ, Watson ED. Endometrial macrophage populations in genitally normal mares at oestrus and dioestrus and in mares susceptible to endometritis. *Equine Vet J* 1998;30:79–81.
- [64] Nikolakopoulos E, Watson ED. Uterine contractility is necessary for the clearance of intrauterine fluid but not bacteria after bacterial infusion in the mare. *Theriogenology* 1999;52:413–23.
- [65] Aurich C, Rojer H, Walter I. Treatment of estrous mares with the non-steroidal anti-inflammatory drug vedaprofen reduces the inflammatory response of the endometrium to insemination. *Anim Reprod Sci* 2010;121:104.
- [66] Risco AM, Reilas T, Muilu L, Kareskoski M, Katila T. Effect of oxytocin and flunixin meglumine on uterine response to insemination in mares. *Theriogenology* 2009;72:1195–201.
- [67] Slusher SH, Freeman KP, Roszel JF. Eosinophils in equine uterine cytology and histology specimens. *J Am Vet Med Assoc* 1984;184:665–70.
- [68] Taylor U, Zerbe H, Seyfert HM, Rath D, Baulain U, Langner KF, et al. Porcine spermatozoa inhibit post-breeding cytokine induction in uterine epithelial cells *in vivo*. *Anim Reprod Sci* 2009;115:279–89.
- [69] Giuliano F, Warner TD. Origins of prostaglandin E2: involvements of cyclooxygenase (COX)-1 and COX-2 in human and rat systems. *J Pharmacol Exp Ther* 2002;303:1001–6.
- [70] Landoni MF, Lees P. Comparison of the anti-inflammatory actions of flunixin and ketoprofen in horses applying PK/PD modelling. *Equine Vet J* 1995;27:247–56.
- [71] Oukessou M, Bouljihad M, Van Gool F, Alvinerie M. Pharmacokinetics of ketoprofen in the donkey (*Equus asinus*). *Zentralbl Veterinarmed A* 1996;43:423–6.
- [72] Mealey KL, Matthews NS, Peck KE, Burchfield ML, Bennett BS, Taylor TS. Pharmacokinetics of R(-) and S(+) carprofen after administration of racemic carprofen in donkeys and horses. *Am J Vet Res* 2004;65:1479–82.
- [73] Veronesi MC, Villani M, Wilsher S, Contri A, Carluccio A. A comparative stereological study of the term placenta in the donkey, pony and thoroughbred. *Theriogenology* 2010;74:627–31.

Capítulo II

Effect of donkey seminal plasma over sperm movement and sperm-polymorphonuclear neutrophils attachment *in vitro*

J. Miró^a, K. Vilés^a, W. García^a, J. Jordana^b, M. Yeste R^a

^a Department of Animal Medicine and Surgery, Faculty of Veterinary Medicine, Autonomous University of Barcelona, E-08193 Bellaterra, Barcelona, Spain

^b Department of Food and Animal Science, Faculty of Veterinary Medicine, Autonomous University of Barcelona, E-08193 Bellaterra, Barcelona, Spain

Received 17 September 2012; revised 17 June 2013; accepted 21 June 2013

Anim. Reprod. Sci. 140 (2013): 164-172



Contents lists available at SciVerse ScienceDirect

Animal Reproduction Science

journal homepage: www.elsevier.com/locate/anireprosci

Effect of donkey seminal plasma on sperm movement and sperm–polymorphonuclear neutrophils attachment *in vitro*

Jordi Miró^{a,*}, Karina Vilés^a, Wilber García^a, Jordi Jordana^b, Marc Yeste^a^a Department of Animal Medicine and Surgery, Faculty of Veterinary Medicine, Autonomous University of Barcelona, E-08193 Bellaterra (Barcelona), Spain^b Department of Food and Animal Science, Faculty of Veterinary Medicine, Autonomous University of Barcelona, E-08193 Bellaterra (Barcelona), Spain

ARTICLE INFO

Article history:

Received 17 September 2012

Received in revised form 17 June 2013

Accepted 21 June 2013

Available online 28 June 2013

Keywords:

Seminal plasma

Donkey

Frozen-thawed sperm

Endometritis

Artificial insemination

ABSTRACT

To evaluate the effect of seminal plasma in endometrial inflammation in donkeys, samples from fresh pure, fresh diluted and frozen-thawed semen of three different jackasses were co-incubated in water bath at 37 °C with uterine Jennie's secretions collected 6 h after artificial insemination with frozen-thawed donkey semen. Individual sperm movement parameters using the computerised sperm analysis system (CASA) and sperm–polymorphonuclear neutrophils (sperm–PMN) attachment observed in Diff-Quick stained smears were evaluated at 0, 1, 2, 3 and 4 h of co-incubation. Controls consisted of incubating diluted or frozen-thawed sperm in the absence of uterine secretions. For data analyses, a repeated measures ANOVA was performed with incubation time as intra-subject factor and with treatment and donkey as inter-subject factor, followed by a post-hoc Bonferroni's test. Greater values ($P < 0.05$) of sperm–PMN percentages and a loss of progressive motility were observed in frozen-thawed semen compared with pure and diluted fresh semen samples throughout the incubation time. In addition, the presence of seminal plasma in fresh and diluted semen samples reduced the inflammatory response of polymorphonuclear neutrophils produced after insemination by suppressing the sperm–PMN attachment *in vitro*. Motility sperm parameters analysed by CASA were also less affected than those in frozen-thawed semen samples. In conclusion, seminal plasma in jennies appears to have a modulation on the endometrial response after artificial insemination with frozen-thawed donkey semen. As a result, spermatozoa with the greater motility characteristics are selected.

© 2013 Elsevier B.V. All rights reserved.

1. Introduction

Insemination is considered the start of communication between spermatozoa and the female organism, involving a number of species specific immune mechanisms to

achieve pregnancy (Schuberth et al., 2008). Post-breeding acute endometritis, characterised by a migration of PMN into the uterus as a necessary physiological response for successful outcome, has been observed in some mammals as gilts and mares (Palm et al., 2006; Rodríguez-Martínez et al., 2010; Rozeboom et al., 2001; Troedsson et al., 2001), but not in others such as cows (Schuberth et al., 2008). This inflammatory response triggered by sperm and other components of semen, normally starts within 1 h of breeding, peaks at 6–12 h and finally decreases after 24–36 h in mares (Katila, 1996; Kotilainen et al., 1994; Troedsson, 2006; Troedsson et al., 2001). An irritating persistent post-mating

* Corresponding author at: Unit of Animal Reproduction, Department of Animal Medicine and Surgery, Faculty of Veterinary Medicine (Building V, Campus UAB), Autonomous University of Barcelona, 08193 Bellaterra (Cerdanyola del Vallès, Barcelona), Spain. Tel.: +34 935 8142 73; fax: +34 935 812 006.

E-mail address: jordi.miro@uab.cat (J. Miró).

endometritis (PMIE) caused by repeated inseminations has been regarded as a cause of infertility in mares and sows (Palm et al., 2006; Troedsson, 2006; Troedsson et al., 2001; Rodríguez-Martínez et al., 2010; Rozeboom et al., 2001) with a higher inflammatory reaction when frozen-thawed semen is used in both reproductive healthy and ill mares (Barbacini et al., 2003; Nikolakopoulos and Watson, 1997; Sieme et al., 2004; Troedsson, 2006; Troedsson et al., 2001, 2005).

In some mammalian species, removing seminal plasma is a necessary process for sperm preservation in artificial conditions. Specifically in donkeys, an improvement of sperm quality after elimination of seminal plasma in refrigerated semen has previously been reported (Miró et al., 2009). In horses and pigs, however, seminal plasma is involved in the immunological response of endometrium through inhibiting complement activation, phagocytosis and PMN chemotaxis induced by spermatozoa (Alghamdi et al., 2004; O'Leary et al., 2006; Rodríguez-Martínez et al., 2008). *In vitro* incubation sperm from highly fertile bulls with seminal plasma from lowly fertile bulls decreases the oocyte penetration ability (Henault and Killian, 1996). Furthermore, differences in composition of seminal plasma between species and among males within the same species (Alghamdi et al., 2009; Robertson, 2005; Schuberth et al., 2008) result in variable fertility indexes (Maxwell et al., 2007; Moura et al., 2006; Robertson, 2005), as well as different uterine immune responses (Katila, 2001; Kotilainen et al., 1994; Matthijs et al., 2003; Pitnick et al., 2009) and freezability (Jobim et al., 2011; Zahn et al., 2005).

Preliminary studies show that, after artificial insemination (AI) using frozen-thawed Catalan donkey semen, there is an exacerbating inflammatory response in jennies that has been suggested to lead to very few pregnancy rates (Vidament et al., 2009). This fact has limited so far reproduction by artificial insemination of this endangered species (Miró et al., 2011).

Therefore, considering the relevance of seminal plasma in reproductive physiology and taking into account that each species has many different male and female physiologic mechanisms that are involved in the regulation of post-breeding endometritis, the aim of the present study was to evaluate the *in vitro* effects of seminal plasma in the uterine inflammation and sperm function in donkeys. With this purpose, the sperm-PMN binding and its influence over sperm movement patterns was evaluated by using different semen samples containing (fresh pure sperm) or not (diluted and frozen-thawed sperm) seminal plasma, co-incubated with uterine secretions collected after artificial insemination. Negative controls consisted of semen samples incubated in the absence of such uterine secretions.

2. Materials and methods

Six healthy Catalan jennies with ages from 5 to 14 years, and three jackasses of known fertility, aged 5–8 years old, were included in the study. Uterine cultures, endometrial cytology and a biopsy while in estrus were performed before starting the experiment to confirm the reproductive

health status and results from these findings were used to select the females used in the study.

2.1. Uterine secretions

To determine the most desirable time for AI in estrus, all females were exhaustively examined by clinical observation, transrectal palpation and ultrasonography (Esaote® MyLab™30 VET; Genova, Italy) using a linear transducer of 5 MHz. After detection of a follicle diameter of greater than 40 mm, softening of this follicle and absence of corpus luteum, jennies were inseminated using eight frozen-thawed semen French straws previously thawed with a water bath at 37 °C. Final sperm concentration was of 200×10^6 spermatozoa mL^{-1} and frozen-thawed semen was deposited in jennies' uterine body using an insemination equine catheter (Minitüb Ibérica SL; Tarragona, Spain).

Uterine secretions were collected 6 h after AI using small volume uterine lavage, introducing 50 mL of warmed (37 °C) lactate ringer in the uterus through an insemination equine catheter (Minitüb Ibérica SL), and massaging the uterus *via* the rectum and recovering at least 10% of sample in a syringe. The recovered volume was registered and PMN concentration was determined by flow cytometry and cytochemistry. Ovulation and drainage of uterine fluid was evaluated by ultrasonography after 24 h of insemination.

2.2. Fresh and diluted semen samples

At the time of uterine secretion sampling, semen was collected by artificial vagina Hannover model (Minitüb Ibérica SL) equipped with an in-line filter (Minitüb Ibérica SL) to get a gel-free semen sample. Semen volume was recorded and halved in two aliquots; one of this aliquot contained raw semen (fresh pure semen), while the other was diluted 1:3 with a skim-milk based semen extender (Kenney et al., 1975) for obtaining the diluted sperm sample.

2.3. Frozen-thawed semen samples

Semen of the same donkey was frozen by means IceCube 14S, Computer Controlled Rate Freezer (Minitüb Ibérica SL), using Gent extender (Minitüb Ibérica SL) and stored at -196°C in liquid nitrogen. At the time of experiment, frozen straws were quickly thawed in water bath at 37 °C, analysed and used immediately.

For all semen samples, a routine quality sperm analysis was performed before each experiment (concentration, sperm viability, morphology and motility) and then was standardised to get approximately the same proportion of sperm per millilitre. Only those sperm samples with >50% of viability, <25% of sperm abnormalities and >60% progressive motility were included in this study.

2.4. Treatments

Treatments (T1, T2 and T3) consisted of *in vitro* co-incubation, in water bath at 37 °C for a 4 h period, of uterine secretions with sperm samples that came from each male at a 1:1 ratio. These co-incubation experiments utilised pure

fresh (T1), diluted fresh (T2), or frozen-thawed (T3) semen samples, all of them coming from the three individuals involved in this study. In addition, two more treatments were performed as controls: diluted fresh semen, C1; and frozen-thawed semen, C2, both being incubated separately without any uterine secretion. Treatment variables (sperm–PMN attachment and sperm motility) were evaluated at 0, 1, 2, 3 and 4 h of incubation.

2.5. Sperm concentration

As stated, sperm concentration was evaluated before starting the experiment, to adjust concentration in all treatments (*i.e.* fresh pure, diluted, frozen-thawed semen) and thus ensure that it was seminal plasma rather than sperm number which affected sperm–PMN binding and sperm motility. The sperm concentration of each semen sample was determined using a haemocytometer (Newbauer chamber).

2.6. Sperm morphology and viability

Sperm viability and morphological abnormalities were assessed using eosin-nigrosin stained smears. Following this stain, 200 sperm cells were assessed per slide (Miró et al., 2005). For each sample two replicates were made.

2.7. Sperm–PMN binding

Sperm–PMN attachment in T1, T2 and T3 was determined as described (Palm et al., 2006; Alghamdi et al., 2004). A sample of 10 μ l was deposited in a slide and a Diff-Quick staining smear was performed. A minimum of 200 sperm cells were counted by light optic microscopy (Carl Zeiss, Germany) at 1000 \times magnification and expressed as the percentage of PMN bound to at least one spermatozoon.

2.8. Sperm motility

Sperm motion characteristics were evaluated after seminal extraction and in T1, T2, T3, C1 and C2 during a 4 h period through a computer assisted sperm analysis CASA (Integrated Semen Analysis System, ISAS[®] Ver. 1.0.15; Projects and Services R+D S.L., ProiSer, Valencia, Spain) equipped with a negative phase contrast microscope Olympus BH-2 (Microptic, Spain) with yellow light filter, warm-up plate and a digital video camera (Basler, Germany) connected to the software. A sample of 5 μ l was deposited in a 37 °C pre-warmed slide and a 24 mm² coverslip was carefully set. Digital images at 200 \times magnifications were recorded and strictly analysed to suppress erroneous routes or artefacts and acquire at least 200 cells per sample. Nine descriptive motion parameters were generated: total motility (TMOT, %); progressive motility (PMOT, %); curvilinear velocity (VCL, μ m s⁻¹); straight-line velocity (VSL, μ m s⁻¹); average path velocity (VAP, μ m s⁻¹); linearity (LIN, %) (Ratio between VSL and VCL); average lateral head displacement (ALH, μ m); wobble (WOB) and beat-cross frequency (BCF, Hz; Mortimer, 2000). The program settings were: frames acquired 25; connectivity, 12; particles size, 4–75 μ m²; straightness

Table 1

Ejaculate variables immediately after extraction (fresh semen) as mean \pm S.E.M.

Parameter	Mean \pm S.E.M.
Filtered volume (mL)	52.31 \pm 18.20
Sperm concentration ($\times 10^6$ mL ⁻¹)	273.26 \pm 11.54
pH	7.8 \pm 0.29
Sperm viability (%)	77.19 \pm 12.53
Sperm immature tail (%)	10.03 \pm 3.95
Sperm coiled-tail (%)	1.36 \pm 1.15
Sperm head abnormality (%)	2.36 \pm 2.07
Tailless spermatozoon (%)	2.26 \pm 1.96
Immature sperm with proximal cytoplasmic droplet (%)	1.41 \pm 1.32
Immature sperm with distal cytoplasmic droplet (%)	0.48 \pm 0.5
Total morphological abnormalities	17.89 \pm 8.54

threshold, 75%; low VAP cut off, 10 μ m s⁻¹; medium VAP cut off, 45 μ m s⁻¹; high VAP cut off, 90 μ m s⁻¹; minimum of images to calculate ALH, 10.

2.9. Statistical analysis

All data were analysed using IBM SPSS 19.0 for Windows (SPSS Inc., Chicago, IL). Sperm–PMN attachment is expressed in percentages and results of motility parameters are presented as mean \pm standard error of the mean (S.E.M.).

The data obtained from the analysis of all sperm parameters were first tested for normality and homoscedasticity using the Kolmogorov–Smirnov and Levene's tests. When necessary, data were transformed using arcsine square root ($\arcsin \sqrt{x}$) before repeated measures ANOVA was run. Post-hoc *t*-test with Bonferroni adjustment was also used for pair-wise comparisons. In these models, sperm motility parameters and sperm–PMN binding were the dependent variables, the intra-subject factor was the co-incubation time between sperm and PMN (*i.e.* 0, 1, 2, 3 or 4 h) and the inter-subject factors were the treatment (*i.e.* fresh pure, diluted or frozen-thawed semen incubated in the presence/absence of uterine secretions; T1, T2, T3, C1 and C2) and the donkey.

In all the statistical analyses, the level of significance was set at $P < 0.05$.

3. Results

Table 1 contains mean \pm S.E.M. data for several ejaculate variables obtained immediately after extraction, such as filtered volume and pH, sperm concentration, sperm viability and morphology categories (*i.e.* abnormalities in heads and tails, sperm with cytoplasmic droplets (Tables 2–4).

3.1. Sperm–PMN attachment

Multivariate contrasts when assessed using a repeated measures model showed there was an effect of time ($P < 0.001$) and treatment ($P < 0.001$), and an interaction between time and treatment ($P < 0.001$). In contrast, there was neither a male effect ($P > 0.05$) or interaction between time, treatment and male ($P > 0.05$).

Table 2

Total (TMOT) and progressive sperm motility (PMOT) (mean ± S.E.M.) obtained at the start (0h) and after 1, 2, 3 and 4 h after starting the experiment. Different letters (a–d) indicate differences ($P < 0.05$) between treatments within a given time point (columns), whereas different numbers (1–4) indicate differences ($P < 0.05$) between time points within the same treatment (rows). Treatments were: pure fresh (T1), diluted fresh (T2), and frozen-thawed sperm (T3) co-incubated with uterine secretions. Controls were diluted fresh and (C1) and frozen-thawed sperm (C2) incubated in the absence of uterine secretions.

Treatment	Co-incubation time					Treatment means
	0h	1 h	2 h	3 h	4 h	
TMOT (%)						
T1	75.9 ± 5.6 ^{a,1}	73.6 ± 5.9 ^{a,1}	59.7 ± 2.1 ^{a,2}	40.9 ± 2.7 ^{a,3}	30.4 ± 4.9 ^{a,4}	56.1 ± 1.9 ^a
T2	70.7 ± 1.4 ^{a,b,1}	68.1 ± 4.3 ^{b,1,2}	65.6 ± 2.2 ^{b,2}	60.2 ± 1.6 ^{c,3}	30.1 ± 3.5 ^{a,4}	58.9 ± 1.2 ^{a,b}
T3	66.9 ± 4.0 ^{b,1}	57.8 ± 7.5 ^{c,2}	53.0 ± 0.6 ^{c,2}	44.9 ± 1.3 ^{b,3}	28.9 ± 5.7 ^{a,4}	50.3 ± 1.7 ^c
C1	69.1 ± 2.9 ^{a,b,1}	67.1 ± 3.3 ^{b,1}	70.1 ± 3.4 ^{d,1}	65.9 ± 2.8 ^{d,1}	49.9 ± 4.2 ^{b,2}	64.4 ± 1.5 ^d
C2	65.2 ± 5.2 ^{b,1,2}	65.8 ± 5.8 ^{b,1,2}	68.1 ± 1.8 ^{b,d,1}	60.1 ± 2.1 ^{c,2}	43.4 ± 3.2 ^{b,3}	60.5 ± 1.6 ^b
Time means	69.6 ± 1.7 ¹	66.5 ± 2.4 ^{1,2}	63.3 ± 0.9 ²	54.4 ± 0.9 ³	36.5 ± 1.9 ⁴	
PMOT (%)						
T1	68.2 ± 4.2 ^{a,1}	63.6 ± 1.9 ^{a,1}	58.8 ± 2.2 ^{a,2}	55.1 ± 2.1 ^{a,2}	50.6 ± 2.7 ^{a,3}	59.3 ± 1.2 ^a
T2	74.9 ± 0.5 ^{b,1}	65.3 ± 3.5 ^{a,2}	62.9 ± 0.8 ^{b,2}	55.1 ± 3.4 ^{a,3}	49.8 ± 1.5 ^{a,b,4}	61.6 ± 0.9 ^a
T3	71.8 ± 3.7 ^{a,b,1}	58.9 ± 0.5 ^{b,2}	60.3 ± 1.3 ^{a,b,2}	40.4 ± 2.9 ^{b,3}	45.2 ± 3.7 ^{b,3}	55.3 ± 1.1 ^b
C1	74.4 ± 3.1 ^{b,1}	76.9 ± 4.8 ^{c,1}	86.7 ± 5.3 ^{c,2}	74.9 ± 5.2 ^{c,1}	60.2 ± 4.5 ^{c,3}	74.6 ± 2.0 ^c
C2	75.1 ± 2.8 ^{b,1,2}	73.8 ± 0.5 ^{c,1}	77.0 ± 1.8 ^{d,2}	69.9 ± 4.5 ^{d,3}	55.3 ± 3.0 ^{a,c,4}	70.2 ± 1.1 ^d
Time means	72.9 ± 1.3 ¹	67.7 ± 1.0 ²	69.1 ± 1.0 ²	59.1 ± 1.6 ³	52.2 ± 1.4 ⁴	

In Fig. 1, mean ± SEM data are depicted for binding percentages between sperm and PMN immediately after starting the experiment (0h) and after 1, 2, 3 and 4 of sperm–PMN co-incubation. No significant differences among treatments (i.e. fresh, diluted and frozen-thawed semen) were observed at the beginning of the experiment (i.e. 0h). After 1, 3 and 4 h of co-incubation, however, sperm–PMN binding was greater ($P < 0.05$) in

frozen-thawed than in diluted and pure fresh semen, and in the former greater than in the latter. At 2 h, frozen-thawed semen had a greater sperm–PMN binding than in diluted and fresh semen, but there were no significant differences between the diluted and fresh semen. The maximum peak of sperm–PMN binding was found after 3 h of co-incubation in frozen-thawed semen, where a tendency to form large cell aggregates was detected (Fig. 2). Thus, there was

Table 3

Sperm velocity variables (curvilinear (VCL), straight linear (VSL) and average pathway (VAP) velocities), as mean ± S.E.M., obtained at the start (0h) and after 1, 2, 3 and 4 h from initiation of the experiment. Different letters (a–d) indicate differences ($P < 0.05$) between treatments within a given time point (columns), whereas different numbers (1–4) indicate differences ($P < 0.05$) between time points within the same treatment (rows). Treatments were: pure fresh (T1), diluted fresh (T2), and frozen-thawed sperm (T3) co-incubated with uterine secretions. Controls were diluted fresh and (C1) and frozen-thawed sperm (C2) incubated in the absence of uterine secretions.

Treatment	Co-incubation time					Treatment means
	0h	1 h	2 h	3 h	4 h	
VCL ($\mu\text{m s}^{-1}$)						
T1	108.6 ± 3.2 ^{a,1}	99.8 ± 1.5 ^{a,2}	80.8 ± 3.9 ^{a,3}	101.1 ± 8.6 ^{a,d,2}	86.6 ± 10.2 ^{a,d,3}	95.3 ± 2.4 ^a
T2	102.0 ± 0.3 ^{b,1}	99.1 ± 1.6 ^{a,1}	109.1 ± 1.4 ^{b,2}	92.6 ± 7.6 ^{b,3}	80.0 ± 9.0 ^{a,4}	96.6 ± 1.8 ^a
T3	105.4 ± 2.2 ^{a,b,1}	105.8 ± 1.2 ^{b,1}	83.6 ± 0.6 ^{a,2}	84.6 ± 5.9 ^{c,2}	62.1 ± 7.6 ^{b,3}	88.3 ± 1.6 ^b
C1	103.0 ± 0.9 ^{b,1}	106.5 ± 3.5 ^{b,1}	118.6 ± 3.9 ^{c,2}	106.9 ± 8.0 ^{d,1}	107.2 ± 7.3 ^{c,1}	108.4 ± 2.1 ^c
C2	102.5 ± 1.7 ^{b,1}	100.8 ± 6.5 ^{a,1}	90.0 ± 4.5 ^{d,2}	98.5 ± 6.4 ^{a,b,1}	90.0 ± 5.3 ^{d,2}	96.4 ± 2.2 ^a
Time means	104.2 ± 0.7 ¹	102.4 ± 1.3 ¹	96.4 ± 1.3 ²	96.7 ± 3.3 ²	85.2 ± 3.5 ³	
VSL ($\mu\text{m s}^{-1}$)						
T1	44.5 ± 1.4 ^{a,1}	54.2 ± 2.6 ^{a,2}	40.1 ± 2.6 ^{a,3}	45.8 ± 3.4 ^{a,1}	40.0 ± 2.2 ^{a,3}	44.9 ± 1.1 ^a
T2	54.9 ± 4.5 ^{b,2}	53.4 ± 1.8 ^{a,1}	57.9 ± 3.1 ^{b,2}	43.7 ± 1.9 ^{a,3}	41.5 ± 5.7 ^{a,3}	50.3 ± 1.5 ^b
T3	47.3 ± 2.5 ^{a,c,1}	43.7 ± 4.4 ^{b,2}	42.8 ± 1.7 ^{a,2}	38.3 ± 5.6 ^{b,3}	32.3 ± 5.6 ^{b,4}	40.9 ± 1.8 ^c
C1	50.1 ± 5.3 ^{b,c,1}	69.0 ± 2.9 ^{c,2}	66.5 ± 4.0 ^{c,2}	55.6 ± 2.9 ^{c,3}	67.0 ± 5.3 ^{c,2}	61.6 ± 1.8 ^d
C2	45.2 ± 3.5 ^{a,1}	43.7 ± 5.1 ^{b,1}	49.4 ± 2.5 ^{d,2}	46.6 ± 3.5 ^{a,1,2}	43.0 ± 4.6 ^{a,1}	45.6 ± 1.7 ^a
Time means	48.4 ± 1.5 ¹	52.8 ± 1.5 ²	51.3 ± 1.2 ²	46.0 ± 1.5 ^{1,3}	44.8 ± 2.1 ³	
VAP ($\mu\text{m s}^{-1}$)						
T1	66.7 ± 8.7 ^{a,1}	73.4 ± 4.8 ^{a,2}	52.8 ± 1.2 ^{a,3}	66.3 ± 6.7 ^{a,d,1}	52.2 ± 7.8 ^{a,3}	62.3 ± 2.6 ^a
T2	71.5 ± 0.8 ^{b,1}	74.2 ± 3.6 ^{a,1}	80.1 ± 3.4 ^{b,2}	60.4 ± 4.9 ^{a,b,3}	60.4 ± 7.6 ^{b,3}	69.3 ± 1.8 ^b
T3	66.2 ± 5.8 ^{a,1}	64.9 ± 2.4 ^{b,1}	58.5 ± 2.1 ^{c,2}	55.2 ± 5.7 ^{b,2}	36.8 ± 5.9 ^{c,3}	56.3 ± 2.0 ^c
C1	73.7 ± 4.1 ^{b,1}	100.9 ± 3.6 ^{c,2}	95.7 ± 2.9 ^{d,2,3}	91.6 ± 3.7 ^{c,3}	96.3 ± 6.6 ^{d,2}	91.6 ± 1.9 ^d
C2	66.0 ± 2.1 ^{a,1,4}	75.3 ± 3.0 ^{a,2}	59.5 ± 3.3 ^{c,3}	68.8 ± 4.5 ^{d,1}	62.3 ± 4.9 ^{b,3,4}	66.4 ± 1.6 ^b
Time means	68.8 ± 1.9 ¹	77.7 ± 1.6 ²	69.3 ± 1.1 ¹	68.5 ± 2.3 ¹	61.6 ± 2.9 ³	

Table 4

Percentages of linearity (%LIN) and Wobbles (%WOB), and values of amplitude of head lateral displacement (ALH) and beat cross frequency, as mean \pm S.E.M., obtained at the start (0 h) and after 1, 2, 3 and 4 h from initiation the experiment. Different letters (a–d) indicate differences ($P < 0.05$) between treatments within a given time point (columns), whereas different numbers (1–4) indicate differences ($P < 0.05$) between time points within the same treatment (rows). Treatments were: pure fresh (T1), diluted fresh (T2), and frozen-thawed sperm (T3) co-incubated with uterine secretions. Controls were diluted fresh and (C1) and frozen-thawed sperm (C2) incubated in the absence of uterine secretions.

Treatment	Co-incubation time					Time means
	0 h	1 h	2 h	3 h	4 h	
LIN (%)						
T1	49.5 \pm 2.8 ^{a,1}	58.6 \pm 5.2 ^{a,c,2}	57.1 \pm 2.8 ^{a,b,2}	48.1 \pm 3.2 ^{a,b,1,3}	42.9 \pm 5.6 ^{a,3}	51.2 \pm 1.7 ^a
T2	65.1 \pm 2.8 ^{b,c,1}	58.5 \pm 1.8 ^{a,2}	55.7 \pm 1.6 ^{a,2,3}	52.4 \pm 5.5 ^{a,c,3}	41.4 \pm 2.5 ^{a,4}	54.6 \pm 1.3
T3	67.1 \pm 5.1 ^{b,1}	44.4 \pm 4.4 ^{b,2}	55.9 \pm 8.8 ^{a,b,3}	44.9 \pm 2.8 ^{b,2}	30.5 \pm 3.8 ^{b,4}	48.6 \pm 2.2
C1	63.7 \pm 2.5 ^{b,c,1}	59.7 \pm 5.2 ^{a,1,2}	59.2 \pm 5.4 ^{b,1,2}	55.8 \pm 5.5 ^{c,2,3}	50.4 \pm 2.5 ^{c,3}	57.8 \pm 1.9
C2	61.3 \pm 3.5 ^{a,1}	52.8 \pm 6.1 ^{c,2}	58.5 \pm 6.5 ^{a,b,1,3}	54.7 \pm 4.5 ^{c,2,3}	45.4 \pm 4.0 ^{a,4}	54.5 \pm 2.2
Time means	61.3 \pm 1.5 ¹	54.8 \pm 2.0 ^{2,3}	57.3 \pm 2.2 ²	51.2 \pm 1.9 ³	42.1 \pm 1.6 ⁴	
WOB (%)						
T1	61.8 \pm 9.7 ^{a,1}	75.7 \pm 1.4 ^{a,2}	70.3 \pm 2.3 ^{a,3}	67.5 \pm 7.2 ^{a,b,3,4}	64.5 \pm 7.2 ^{a,1,4}	68.0 \pm 2.5 ^a
T2	81.9 \pm 2.3 ^{b,1}	77.1 \pm 1.2 ^{a,c,1,2}	74.5 \pm 8.7 ^{a,2}	69.9 \pm 7.9 ^{a,3}	65.1 \pm 7.8 ^{a,3}	73.7 \pm 2.5 ^b
T3	74.5 \pm 9.2 ^{c,d,1}	62.9 \pm 5.7 ^{b,2}	71.5 \pm 8.0 ^{a,1}	63.7 \pm 5.9 ^{b,2}	55.1 \pm 5.2 ^{b,3}	65.5 \pm 3.0 ^a
C1	78.5 \pm 5.9 ^{b,c,1}	80.5 \pm 2.8 ^{c,1}	80.7 \pm 5.8 ^{b,1}	78.8 \pm 5.0 ^{c,1}	78.4 \pm 6.7 ^{c,1}	79.4 \pm 2.3 ^c
C2	70.5 \pm 7.5 ^{d,1,2}	68.4 \pm 4.2 ^{b,1}	73.9 \pm 7.5 ^{a,2,3}	75.9 \pm 4.8 ^{c,3}	73.6 \pm 4.6 ^{c,2,3}	72.5 \pm 2.6 ^b
Time means	73.4 \pm 3.1 ¹	72.9 \pm 1.4 ¹	74.2 \pm 2.9 ¹	71.2 \pm 2.7 ^{1,2}	67.3 \pm 2.8 ²	
ALH (μm)						
T1	4.1 \pm 0.6 ^{a,1}	3.2 \pm 1.1 ^{a,2,3}	2.9 \pm 0.5 ^{a,3}	3.8 \pm 0.1 ^{a,1,2}	3.4 \pm 0.4 ^{a,2}	3.5 \pm 0.3 ^a
T2	2.8 \pm 0.9 ^{b,1}	3.1 \pm 1.0 ^{a,1,2}	3.5 \pm 0.3 ^{b,2}	3.2 \pm 0.7 ^{a,1,2}	3.4 \pm 0.3 ^{a,2}	3.2 \pm 0.3 ^a
T3	3.1 \pm 0.2 ^{b,1}	4.0 \pm 0.3 ^{b,2}	2.9 \pm 0.7 ^{a,1}	3.2 \pm 1.3 ^{a,1}	2.1 \pm 0.3 ^{b,3}	3.1 \pm 0.2 ^a
C1	3.0 \pm 0.7 ^{b,1}	4.6 \pm 1.2 ^{b,2}	4.6 \pm 0.4 ^{c,2}	4.7 \pm 0.8 ^{b,2}	4.6 \pm 0.3 ^{c,2}	4.3 \pm 0.3 ^b
C2	3.1 \pm 0.5 ^{b,1}	2.5 \pm 0.5 ^{c,2}	3.7 \pm 0.5 ^{b,3}	3.8 \pm 0.6 ^{a,3}	3.1 \pm 0.5 ^{a,1}	3.2 \pm 0.3 ^a
Time means	3.2 \pm 0.3 ¹	3.5 \pm 0.4 ¹	3.5 \pm 0.2 ¹	3.7 \pm 0.3 ¹	3.3 \pm 0.2 ¹	
BCF (Hz)						
T1	8.2 \pm 0.1 ^{a,1}	8.4 \pm 0.4 ^{a,1}	8.0 \pm 0.5 ^{a,1}	8.1 \pm 0.4 ^{a,1}	9.2 \pm 0.8 ^{a,2}	8.4 \pm 0.3 ^a
T2	7.8 \pm 0.3 ^{b,1}	8.4 \pm 1.0 ^{a,1,2}	8.4 \pm 0.9 ^{a,1,2}	7.9 \pm 0.5 ^{a,1}	8.8 \pm 0.8 ^{a,2}	8.3 \pm 0.4 ^a
T3	7.9 \pm 0.6 ^{a,1}	11.2 \pm 0.8 ^{b,2}	10.3 \pm 0.4 ^{b,3}	11.5 \pm 0.6 ^{b,2}	9.9 \pm 0.7 ^{a,b,3}	10.2 \pm 0.4 ^b
C1	7.2 \pm 1.1 ^{b,1}	10.5 \pm 1.2 ^{b,2}	10.9 \pm 0.6 ^{b,2}	10.6 \pm 0.6 ^{c,2}	10.7 \pm 0.7 ^{b,2}	10.0 \pm 0.5 ^b
C2	7.7 \pm 0.3 ^{a,b,1}	8.2 \pm 0.7 ^{a,1,2}	8.8 \pm 0.1 ^{a,2}	8.3 \pm 0.6 ^{a,1,2}	7.6 \pm 0.7 ^{c,1}	8.1 \pm 0.3 ^a
Time means	7.8 \pm 0.2 ¹	9.3 \pm 0.4 ²	9.3 \pm 0.2 ²	9.3 \pm 0.2 ²	9.2 \pm 0.7 ²	

less ($P < 0.05$) sperm–PMN binding throughout all experimental periods when fresh semen (T1) was compared with diluted fresh and frozen-thawed semen (T2 and T3; Fig. 1).

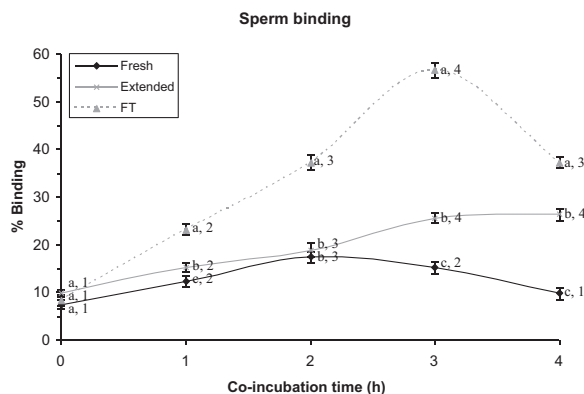


Fig. 1. Sperm binding to leukocytes 0, 1, 2, 3 or 4 h after co-incubation of PMN with fresh, extended or frozen-thawed (FT) spermatozoa. Different letters (a–c) indicate differences ($P < 0.05$) between treatments within a given time point (columns), whereas different numbers (1–4) indicate differences ($P < 0.05$) between time points within the same treatment (rows).

3.2. Sperm motility

For sperm motility variables (except ALH), there was an effect of time ($P < 0.01$) and treatment ($P < 0.005$), and an interaction between time and treatment ($P < 0.01$). In contrast, there was not a male effect ($P > 0.05$) or interaction between time, treatment and male ($P > 0.05$).




Fig. 2. Sperm–PMN attachment of frozen semen with a tendency to form large aggregates at 3 h of incubation.

Total sperm motility (TMOT) was less ($P < 0.05$) with all the treatments, but the reduction was greater in semen co-incubated with uterine secretions (T1–T3) than in semen incubated in the absence of these secretions (C1 and C2) after 3 and 4 h of co-incubation. Within treatments (T1–T3), for diluted semen (T2) there was a greater percentage of total motile spermatozoa than for pure fresh (T1) and frozen (T3) semen after 3 h of co-incubation with uterine secretions.

Similarly, to what occurred with total sperm motility, controls (C1 and C2) had greater sperm motility after 1 h of co-incubation and throughout the remaining experimental period, except after 4 h of co-incubation where there were no significant differences between T1 and C2. Again, T1 and T2 resulted in similar progressive motility data, and for frozen-thawed semen (T3) there was a lesser percentage of progressively motile spermatozoa after 1, 3 and 4 h of co-incubation with uterine secretions.

With regard to curvilinear velocity (VCL), there were no differences between treatments observed at the beginning of the experiment, but diluted spermatozoa incubated without uterine secretions (C1) had a greater VCL than the other treatments after 2 and 4 h of the experimental period. In contrast, a lesser VCL ($P < 0.05$) was observed in frozen-thawed semen (T3) co-incubated with uterine secretions at 4 h. In addition, the VCL was less ($P < 0.01$) at the end of the experiment (4 h) when compared to the beginning (0 h) in all treatments, except in C1.

Incubation of diluted semen in the absence of uterine secretions (C1) also resulted in a greater VSL at 1 h and throughout the remaining experimental period. It should be noted that the VSL was less at the end of experiment when compared to 0 h for all three treatments (T1, T2 and T3) but not in both controls, where VSL was greater (C1) or remained unaltered.

Average Pathway Velocity (VAP) was less from the beginning of the experiment and until the end of the co-incubation period in T1, T2, and T3. In contrast, spermatozoa from both controls (C1 and C2) did not reduce the VAP over the experimental period, and in the case of C1 increased the VAP. In addition, incubation of diluted sperm without uterine secretions (C1) resulted in a greater VAP than with the other treatments throughout all the experimental period.

Percentage of LIN significantly decreased in all the treatments from the beginning of the experiment, but the extent of this reduction was significantly higher in T3 than in the other treatments, especially at 4 h. In contrast, it was the C1 treatment which presented the lowest reduction in sperm LIN percentage.

With regard to WOB percentage, and despite no significant differences being observed at the start of experiment between diluted fresh semen co-incubated with uterine secretions (T2) and that incubated in the absence of such secretions (C1), a greater reduction in WOB percentages occurred with the former than the treatment (T2) from 1 h until the end of the experimental period. Again, frozen-thawed semen co-incubated with uterine secretions (T3) had a lesser WOB percentage after 1, 3 and 4 h of the incubation period.

Finally, ALH increased in C1 over the experimental period, while the values of BCF at 4 h were the greatest in C1 and least in C2.

4. Discussion

The uterus has features of a mucosa-associated lymphoid tissue that varies with the estrous phase in mares. A neutrophilic based population is observed just before ovulation, and its inflammatory activity is triggered by insemination to protect the uterine environment against sperm, bacteria and other substances acting as foreign bodies (Katila, 2001; Pitnick et al., 2009; Schuberth et al., 2008). However, the endometrial physiology and its response to semen vary with the composition, amount of sperm, seminal plasma components or added substances such as extenders (Gorgens et al., 2005; Palm et al., 2006). A greater inflammatory response triggered by frozen-thawed semen may be responsible for the lesser fertilisation and subsequent pregnancy obtained in donkeys (Miró et al., 2011; Vidament et al., 2009), possibly because of an exacerbating innate response to semen due to the absence of seminal plasma and/or presence of cryo-protectants that enhance irritation of the uterus as reported in horses (Gorgens et al., 2005; Nikolakopoulos and Watson, 1997; Watson et al., 2001).

During the incubation times, pure fresh semen followed by diluted fresh semen treatments resulted in less sperm–PMN attachment compared with frozen-thawed semen samples, and the difference increased over time with formation of large aggregates of sperm, PMN and endometrial cells. Similar results were observed in stallion fresh semen samples incubated with uterine mare secretions, where there was greater sperm–PMN attachment in the absence of seminal plasma compared with those diluted with extender or a mix of both. There was also a dose dependent effect of seminal plasma in reduction of sperm–PMN binding (Alghamdi et al., 2004; Rozeboom et al., 2001). In addition there is blocking of the effects of seminal plasma to interleukin-8-induced neutrophil chemotaxis (Rozeboom et al., 2001). The biological meaning of the large neutrophil aggregates is still incomplete but it appears as though the most relevant anti-chemotactic effect of seminal plasma is the inhibition of the strongly induced agglutination of neutrophils caused by sperm cells through a seminal plasma DNAase enzyme (Alghamdi et al., 2010).

The reduced sperm–PMN relation observed in fresh and diluted semen samples has been attributed to the presence of seminal plasma that suppresses the opsonisation, complement activation, chemiotaxis and, thus, blocks sperm phagocytosis (Alghamdi et al., 2004; Eisenbach, 2003; Katila, 1996; 2001; Troedsson et al., 2001, 2005; Schuberth et al., 2008). In contrast, seminal plasma promotes PMN binding and phagocytosis of non-viable spermatozoa (Troedsson et al., 2005). Transient binding of PMN to specific viable sperm cell subpopulations has been observed. It has been hypothesised that aged, dead or hyper-activated spermatozoa are targeted by neutrophilic granulocytes (Jaffe et al., 2006; Matthijs et al., 2003). The massive increase of PMN in the uterine lumen and

subsequent cell mass formations is also favoured by the presence of extenders, cryo-protectant substances and/or biochemical changes in the sperm membrane structure caused by the freezing-thawing process (Gorgens et al., 2005; Kotilainen et al., 1994; Matthijs et al., 2003). In this regard, membrane integrity is considered one of the key features for this selective reaction (Eisenbach, 2003; Gorgens et al., 2005; Mary, 2000; Taylor et al., 2008).

Despite some studies suggesting there are proteinaceous substances in seminal plasma involved in uterine immunomodulation in horses and swine (Alghamdi et al., 2004; Rodríguez-Martínez et al., 2010; Troedsson et al., 2005), other components in whole seminal plasma also seem to be implicated in selecting the viable and non-viable sperm and defending from the uterine inflammatory cells. However, the molecular mechanisms of these cell-to-cell interactions still remain unclear (Schubert et al., 2008; Troedsson et al., 2005).

With regard to sperm movement, treatments and controls (always with greater values) were similar in all motility variables obtained by CASA at 0h, and then decreased over time with a greater influence in treatments co-incubated with uterine secretions than in controls, changing from a rapid linear progressive movement to a slow non-linear non-progressive movement pattern. Total and progressive motilities followed by average velocity and linearity were the variables affected to the greatest extent (TMOT, PMOT, VAP and LIN). Related to this, it is worth noting that altered TMOT, PMOT and VAP due to the presence of PMN have previously been observed (Alghamdi et al., 2001; Reilas et al., 1997; Troedsson et al., 2001). Further, an initial rapid progressive motility is needed for the passage of sperm through specific sites in the female tract, and a force speed is required for efficient penetration of the zona pellucida (Olds-Clarke, 1996). Changes in velocity variables reduce the sperm ability to travel along the uterus and arrive at the fertilisation site (utero-tubal junction), so that less than 1% of inseminated spermatozoa are transported to the oviducts after insemination (Liu and Scott, 2000; Olds-Clarke, 1996). There was less variation for WOB, ALH and BCF variables throughout the co-incubation period and these were considered as the variables with the greatest impact on sperm binding (Alghamdi et al., 2001) even though sperm head movements are less affected by uterine inflammatory cells. In addition and although spermatozoa could not move forward, some sperm cells were not impacted by inflammatory cells. This might represent a strategy for sperm selection as previously suggested (Alghamdi et al., 2001; Eisenbach, 2003; Jaffe et al., 2006). In fact, and considering sperm physiology, this fact appears to be directly related with spermatozoa energy and, eventually, this waste of energy could render sperm immobile and thus reduce viability (de Andrade et al., 2011; Kareskoski and Katila, 2008).

In the present study, there were few differences between treatments (T1–T3) in sperm movement after 4 h of co-incubation, confirming that sample types (fresh, diluted or frozen-thawed semen) do not impact the competency of inflammatory female cells collected after insemination from binding to sperm cells. In addition, the PMN influence on sperm movement also increased

gradually over time as reported in horses (Alghamdi et al., 2001). However, sperm motility of frozen-thawed semen was affected to the greatest extent by treatment during the present experiment compared with pure and diluted fresh semen samples. This finding is consistent with those of Troedsson et al. (2005) where it was reported that removal or reduction of seminal plasma prior to cryopreservation affected sperm transport through the uterus. Furthermore, a stimulant effect of seminal plasma on sperm motility when in low concentrations and short-term exposures has also been reported (Jasko et al., 1992).

In horses, insemination with frozen-thawed semen has been successfully used with results over 60% (Katila, 2005; Samper and Morris, 1998; Sieme et al., 2004). Nevertheless, and despite frozen-thawed donkey semen having an apparently acceptable quality after thawing (with a 45–50% average viability), very poor pregnancy outcomes have been obtained after insemination in different donkey breeds (Canisso et al., 2008, 2011; Flores et al., 2008; Miró et al., 2009; Vidament et al., 2009). The intensive inflammatory response of the female endometrium along with the shorter longevity of frozen-thawed spermatozoa in absence of seminal plasma appear to limit the number of viable spermatozoa that are able to reach the oviduct and, subsequently, probabilities of fertilisation are clearly reduced as observed in horses (Katila, 2005). Interestingly, pregnancy rates have been reported to be greater when high quality spermatozoa suspended in seminal plasma is used to inseminate mares, with induced inflamed uteri compared with extended semen (77% compared with 5%; Alghamdi et al., 2004).

The role of seminal plasma has been gaining importance in reproductive physiology, because of the modulating mechanisms of the compounds that are in this plasma. Taken together results of previous and the present study could lead to development of procedures to enhance fertility rates using AI protocols with frozen-thawed semen in donkeys, as well as could allow for standardising and safe use of seminal plasma preparations within insemination doses as an *in vivo* anti-inflammatory treatment.

5. Conclusions

In conclusion, regardless of the sperm origin (fresh, diluted or frozen semen) insemination produces an inflammatory uterine response mainly characterised by the presence of active PMN in donkeys. Absence of seminal plasma in frozen-thawed sperm samples enhances the inflammatory activity of PMN *in vitro* as expressed by more sperm–PMN attachment with complex cell mass formations and more evident altered sperm motility variables (mainly velocity and progressiveness) than in fresh and diluted semen samples, in which seminal plasma is present. In addition, and although donkey's frozen-thawed semen has showed favourable viability characteristics and fertility *in vitro*, insemination protocols should be modified to achieve satisfactory results *in vivo*. Finally, our results warrant more research on the immuno-modulating mechanisms of seminal plasma in the reproductive breeding

process, as more knowledge in this area may enhance the understanding of inflammation and contribute to optimising reproductive technologies such as AI, not only in donkeys but also in other species susceptible to sperm-induced endometritis.

References

- Alghamdi, A., Troedsson, M.H., Laschkewitsch, T., Xue, J.L., 2001. Uterine secretion from mares with post-breeding endometritis alters sperm motion characteristics in vitro. *Theriogenology* 55, 1019–1028.
- Alghamdi, A.S., Foster, D.N., Troedsson, M.H., 2004. Equine seminal plasma reduces sperm binding to polymorphonuclear neutrophils (PMNs) and improves the fertility of fresh semen inseminated into inflamed uteri. *Reproduction* 127, 593–600.
- Alghamdi, A.S., Lovaas, B.J., Bird, S.L., Lamb, G.C., Rendahl, A.K., Taube, P.C., Foster, D.N., 2009. Species-specific interaction of seminal plasma on sperm–neutrophil binding. *Anim. Reprod. Sci.* 114, 331–344.
- Alghamdi, A.S., Funnell, B.J., Bird, S.L., Lamb, G.C., Rendahl, A.K., Taube, P.C., Foster, D.N., 2010. Comparative studies on bull and stallion seminal DNase activity and interaction with semen extender and spermatozoa. *Anim. Reprod. Sci.* 121, 249–258.
- Barbacini, S., Necchi, D., Zavaglia, G., Squires, E.L., 2003. Retrospective study on the incidence of postinsemination uterine fluid in mares inseminated with frozen/thawed semen. *J. Equine Vet. Sci.* 23, 493–496.
- Canisso, I., Souza, F., Ortigoza, J., 2008. Congelamiento de semen de burro (*Equus asinus*). *Rev. Investig. Vet.* 19, 113–125.
- Canisso, I.F., Carvalho, G.R., Morel, M.D., Ker, P.G., Rodrigues, A.L., Silva, E.C., Coutinho Da Silva, M.A., 2011. Seminal parameters and field fertility of cryopreserved donkey jack semen after insemination of horse mares. *Equine Vet. J.* 43, 179–183.
- de Andrade, A.F., Zaffalon, F.G., Celeghini, E.C., Nascimento, J., Tarrago, O.F., Martins, S.M., Alonso, M.A., Arruda, R.P., 2011. Addition of seminal plasma to post-thawing equine semen: what is the effect on sperm cell viability? *Reprod. Domest. Anim.* 46, 682–686.
- Eisenbach, M., 2003. Why are sperm cells phagocytosed by leukocytes in the female genital tract? *Med. Hypotheses* 60, 590–592.
- Flores, E., Taberner, E., Rivera, M.M., Peña, A., Rigau, T., Miró, J., Rodríguez-Gil, J.E., 2008. Effects of freezing/thawing on motile sperm subpopulations of boar and donkey ejaculates. *Theriogenology* 70, 936–945.
- Gorgens, A., Leibold, W., Klug, E., Schuberth, H.J., Martinsson, G., Zerbe, H., 2005. Inseminate components are modulating the chemotactic activity of uterine polymorphonuclear granulocytes (PMN) of mares. *Anim. Reprod. Sci.* 89, 308–310.
- Henault, M.A., Killian, G.J., 1996. Effect of homologous and heterologous seminal plasma on the fertilizing ability of ejaculated bull spermatozoa assessed by penetration of zona-free bovine oocytes. *J. Reprod. Fertil.* 108, 199–204.
- Jaffe, K., Camejo, M.I., Carrillo, T.E., Weffer, M., Muñoz, M.G., 2006. Evidence favoring sperm selection over sperm competition in the interaction between human seminal plasma and sperm motility in vitro. *Arch. Androl.* 52, 45–50.
- Jasko, D.J., Little, T.V., Lein, D.H., Foote, R.H., 1992. Comparison of spermatozoal movement and semen characteristics with fertility in stallions: 64 cases (1987–1988). *J. Am. Vet. Med. Assoc.* 200, 979–985.
- Jobim, M.I., Trein, C., Zirkler, H., Gregory, R.M., Sieme, H., Mattos, R.C., 2011. Two-dimensional polyacrylamide gel electrophoresis of equine seminal plasma proteins and their relation with semen freezability. *Theriogenology* 76, 765–771.
- Kareskoski, M., Katila, T., 2008. Components of stallion seminal plasma and the effects of seminal plasma on sperm longevity. *Anim. Reprod. Sci.* 107, 249–256.
- Katila, T., 1996. Uterine defence mechanisms in the mare. *Anim. Reprod. Sci.* 42, 197–204.
- Katila, T., 2001. Sperm–uterine interactions. A review. *Anim. Reprod. Sci.* 68, 267–272.
- Katila, T., 2005. Effect of the inseminate and the site of insemination on the uterus and pregnancy rates of mares. *Anim. Reprod. Sci.* 89, 31–38.
- Kenney, R.M., Bergman, R.V., Cooper, W.L., Moerse, G.W., 1975. Minimal contamination techniques for breeding mares: technique and preliminary findings. *Proc. Am. Assoc. Equine Pract.*, 327–336.
- Kotilainen, T., Huhtinen, M., Katila, T., 1994. Sperm-induced leukocytosis in the equine uterus. *Theriogenology* 41, 629–636.
- Liu, I.K., Scott, M.A., 2000. Sperm in the oviduct. *J. Equine Vet. Sci.* 20, 836.
- Matthijs, A., Engel, B., Woelders, H., 2003. Neutrophil recruitment and phagocytosis of boar spermatozoa after artificial insemination of sows, and the effects of inseminate volume, sperm dose and specific additives in the extender. *Reproduction* 125, 357–367.
- Mary, A.S., 2000. A glimpse at sperm function in vivo: sperm transport and epithelial interaction in the female reproductive tract. *Anim. Reprod. Sci.* 60–61, 337–348.
- Maxwell, W.M., de Graaf, S.P., Ghaoui, R., Evans, G., 2007. Seminal plasma effects on sperm handling and female fertility. *Soc. Reprod. Fertil. Suppl.* 64, 13–38.
- Miró, J., Lobo, V., Quintero-Moreno, A., Medrano, A., Peña, A., Rigau, T., 2005. Sperm motility patterns and metabolism in Catalonian donkey semen. *Theriogenology* 63, 1706–1716.
- Miró, J., Taberner, E., Rivera, M., Peña, A., Medrano, A., Rigau, T., Peñalba, A., 2009. Effects of dilution and centrifugation on the survival of spermatozoa and the structure of motile sperm cell subpopulations in refrigerated catalonian donkey semen. *Theriogenology* 72, 1017–1022.
- Miró, J., Vilés, K., Fernández, M., Fàbregas, N., Soares, J., García, W., 2011. Induced acute endometritis by frozen semen insemination in donkey. *Reprod. Domest. Anim.* 46 (Suppl. 3), 183.
- Mortimer, S.T., 2000. CASA-practical aspects. *J. Androl.* 21, 515–524.
- Moura, A.A., Koc, H., Chapman, D.A., Killian, G.J., 2006. Identification of proteins in the accessory sex gland fluid associated with fertility indexes of dairy bulls: a proteomic approach. *J. Androl.* 27, 201–211.
- Nikolakopoulos, E., Watson, E.D., 1997. Does artificial insemination with chilled, extended semen reduce the antigenic challenge to the mare's uterus compared with natural service? *Theriogenology* 47, 583–590.
- Olds-Clarke, P., 1996. How does poor motility alter sperm fertilizing ability? *J. Androl.* 17, 183–186.
- O'Leary, S., Jasper, M.J., Robertson, S.A., Armstrong, D.T., 2006. Seminal plasma regulates ovarian progesterone production, leukocyte recruitment and follicular cell responses in the pig. *Reproduction* 132, 147–158.
- Palm, F., Walter, I., Budik, S., Aurich, C., 2006. Influence of different semen extenders and seminal plasma on the inflammatory response of the endometrium in oestrous mares. *Anim. Reprod. Sci.* 94, 286–289.
- Pitnick, S., Wolfner, M.F., Suarez, S.S., 2009. Ejaculate–female and sperm–female interactions. In: Birkhead, T.R., Hosken, D.J., Pitnick, S. (Eds.), *Sperm Biology. An Evolutionary Perspective*. Elsevier, London, pp. 247–304.
- Reilas, T., Katila, T., Mäkelä, O., Huhtinen, M., Koskinen, E., 1997. Intrauterine fluid accumulation in oestrous mares. *Acta Vet. Scand.* 38, 69–78.
- Robertson, S.A., 2005. Seminal plasma and male factor signalling in the female reproductive tract. *Cell Tissue Res.* 322, 43–52.
- Rodríguez-Martínez, H., Saravia, F., Wallgren, M., Martínez, E.A., Sanz, L., Roca, J., Vázquez, J.M., Calvete, J.J., 2010. Spermadhesin PSP-I/PSP-II heterodimer induces migration of polymorphonuclear neutrophils into the uterine cavity of the sow. *J. Reprod. Immunol.* 84, 57–65.
- Rodríguez-Martínez, H., Saravia, F., Wallgren, M., Roca, J., Peña, F.J., 2008. Influence of seminal plasma on the kinematics of boar spermatozoa during freezing. *Theriogenology* 70, 1242–1250.
- Rozeboom, K.J., Rocha-Chavez, G., Troedsson, M.H., 2001. Inhibition of neutrophil chemotaxis by pig seminal plasma in vitro: a potential method for modulating post-breeding inflammation in sows. *Reproduction* 121, 567–572.
- Schuberth, H.J., Taylor, U., Zerbe, H., Waberski, D., Hunter, R., Rath, D., 2008. Immunological responses to semen in the female genital tract. *Theriogenology* 70, 1174–1181.
- Taylor, U., Rath, D., Zerbe, H., Schuberth, H.J., 2008. Interaction of intact porcine spermatozoa with epithelial cells and neutrophilic granulocytes during uterine passage. *Reprod. Domest. Anim.* 43, 166–175.
- Troedsson, M.H., Loset, K., Alghamdi, A.M., Dahms, B., Crabo, B.G., 2001. Interaction between equine semen and the endometrium: the inflammatory response to semen. *Anim. Reprod. Sci.* 68, 273–278.
- Troedsson, M.H., 2006. Breeding-induced endometritis in mares. *Vet. Clin. North Am. Equine Pract.* 22, 705–712.
- Troedsson, M.H., Desvougues, A., Alghamdi, A.S., Dahms, B., Dow, C.A., Hayna, J., Valesco, R., Collahan, P.T., Macpherson, M.L., Pozor, M., Buhí, W.C., 2005. Components in seminal plasma regulating sperm transport and elimination. *Anim. Reprod. Sci.* 89, 171–186.
- Samper, J.C., Morris, C.A., 1998. Current methods for stallion semen cryopreservation. A survey. *Theriogenology* 49, 895–903.
- Sieme, H., Bonk, A., Hamann, H., Klug, E., Katila, T., 2004. Effects of different artificial insemination techniques and sperm doses on fertility of

- normal mares and mares with abnormal reproductive history. *Theriogenology* 62, 915–928.
- Vidament, M., Vincent, P., Martin, F., Magistrini, M., Blesbois, E., 2009. Differences in ability of jennies and mares to conceive with cooled and frozen semen containing glycerol or not. *Anim. Reprod. Sci.* 112, 22–35.
- Watson, E.D., Barbacini, S., Berrocal, B., Sheerin, O., Marchi, V., Zavaglia, G., Necchi, D., 2001. Effect of insemination time of frozen semen on incidence of uterine fluid in mares. *Theriogenology* 56, 123–131.
- Zahn, F.S., Papa, F.O., Melo, C.M., Brisola, M.L., 2005. Protein profile of equine seminal plasma. Correlation to semen freezability. *Anim. Reprod. Sci.* 89, 313–315.

Capítulo III

Influence of seminal plasma on leukocyte migration and amount of COX-2 protein in the jenny endometrium after insemination with frozen-thawed semen

K. Vilés^a, R. Rabanal^b, M. Rodríguez-Prado^c, J. Miró^a

^a Equine Reproduction Service, Department of Animal Medicine and Surgery, Faculty of Veterinary Medicine, Autonomous University of Barcelona, E-08193 Bellaterra, Barcelona, Spain

^b Center of Animal Biotechnology and Gene Therapy, Department of Animal Medicine and Surgery, Faculty of Veterinary Medicine, Autonomous University of Barcelona, Spain.

^c Animal Nutrition, Management and Welfare Research Group, Department of Food and Animal Science, Faculty of Veterinary Medicine, Autonomous University of Barcelona, Spain.

Received 8 April 2013; revised 25 October 2013; accepted 1 November 2013

Anim. Reprod. Sci. xxx (2013): xxx-xxx



Contents lists available at ScienceDirect

Animal Reproduction Science

journal homepage: www.elsevier.com/locate/anireprosci



Influence of seminal plasma on leucocyte migration and amount of COX-2 protein in the jenny endometrium after insemination with frozen–thawed semen

K. Vilés^a, R. Rabanal^b, M. Rodríguez-Prado^c, J. Miró^{a,*}

^a Equine Reproduction Service, Department of Animal Medicine and Surgery, Faculty of Veterinary Medicine, Autonomous University of Barcelona, Spain

^b Center of Animal Biotechnology and Gene Therapy, Department of Animal Medicine and Surgery, Faculty of Veterinary Medicine, Autonomous University of Barcelona, Spain

^c Animal Nutrition, Management and Welfare Research Group, Department of Food and Animal Science, Faculty of Veterinary Medicine, Autonomous University of Barcelona, Spain

ARTICLE INFO

Article history:

Received 8 April 2013

Received in revised form 25 October 2013

Accepted 1 November 2013

Available online xxx

Keywords:

Seminal plasma

Donkey

Post mating induced endometritis

Artificial insemination

Frozen semen

ABSTRACT

After mating, seminal plasma has an immuno-modulatory effect on the endometrium in some mammals. In jennies, achieving conception via artificial insemination (AI) with frozen–thawed semen is generally much more difficult than in mares. The endometrial inflammatory response is hypothesized to be a contributing factor to the lesser fertility. Following a cross-over experimental design, the uterine inflammatory response of six jennies was evaluated at 6 h after AI with frozen–thawed semen (deposited in the uterine body) in the presence or absence of autologous seminal plasma (+SP or –SP). The endometrial cytology and histology of the animals were examined by uterine lavage, uterine swabbing and biopsy. The amount of cyclooxygenase-2 (COX-2) protein in endometrial cells was also evaluated. As a control (C), the same examinations were made before any AI procedure (i.e., when the jennies were in oestrus). Large numbers of polymorphonuclear neutrophils (PMN) were observed in the –SP and +SP cytology and biopsy samples; more than in the C samples. The –SP samples also had intense COX-2 labelling; less labelling was detected in the +SP and C samples (no significant difference between these latter two types). Thus, while the presence of SP does not change the post-AI number of PMNs with regard to that detected in its absence, it does reduce COX-2 protein. Further research into the complex mix of molecules in SP and its effects during AI might help increase the pregnancy rates achieved in jennies.

© 2013 Elsevier B.V. All rights reserved.

1. Introduction

The spermatozoa and seminal fluid deposited in mammalian females during natural mating and artificial insemination (AI) can induce an acute inflammatory

response in the endometrium (Troedsson et al., 2001; Robertson, 2007). This reaction is species-specific and varies with the type of inseminate (cryo-preserved, cooled or fresh semen), semen quality, and deposition site (Kotilainen et al., 1994; Katila, 2005, 2012; Fiala et al., 2007). When the cervical and epithelial endometrial cells come into contact with semen, proinflammatory cytokines such as prostaglandins are produced, mainly through the action of the COX-2 enzyme in the arachidonic acid synthesis cascade. This is thought to lead to

* Corresponding author at: Campus UAB, Edifici V, E-08193 Bellaterra, Spain. Tel.: +34 935 811 959; fax: +34 935 812 006.
E-mail address: jordi.miro@uab.cat (J. Miró).

increase intrauterine fluid production as well as the chemo-attraction of polymorphonuclear neutrophils (PMN) to the uterine lumen. Macrophages, monocytes and lymphocytes are also attracted to the sub-epithelial endometrium via the activation of complement (Troedsson et al., 2001, 2005; Robertson, 2007) in a process that peaks after 4–6 h. In mares, this leads to the cleansing of the excess semen by 24–48 h after insemination (Katila, 2001).

Seminal plasma (SP) is a mixture of molecules that functions as a transport medium for sperm. It also has species-specific inhibitory and stimulatory properties (Robertson, 2005). Although SP is not necessary for fertilization to occur, it facilitates interactions between the most competent male gametes and the uterus, thus maximizing the probability of conception and embryo viability (Töpfer-Petersen et al., 2005; Robertson, 2007). In gilts and mares with a previously inflamed uterine environment, even short SP contact times can promote pregnancy (Troedsson et al., 2001; Rozeboom et al., 2001; Fiala et al., 2002), perhaps by reducing this inflammation. The SP is also reported to have favourable effects on sperm motility and on the survival of sperm cells in the uterus by helping to avoid oxidative damage and impairing their binding to PMN and other phagocytes (Alghamdi et al., 2004; Rota et al., 2008; Aloé et al., 2012). It may also facilitate the elimination of non-viable spermatozoa via selective phagocytosis (Tomlinson et al., 1992; Troedsson et al., 2005). In addition, SP may promote the production and inhibition of different cytokines during the post-breeding inflammatory process, helping to elicit the transient immune tolerance essential for implantation and embryo development (O'Leary et al., 2004; Robertson, 2005; Jiwakanon et al., 2011; Sharkey et al., 2012). The removal of SP is, however, a necessary step when trying to cryo-preserve semen.

In mares, fertility outcomes with frozen–thawed semen have improved over the years (Sieme et al., 2004; Vidament, 2005), but fertility outcomes remain disappointing in jennies (Oliveira et al., 2006; Vidament et al., 2009). This is true even if the cryo-preserved donkey semen is of excellent quality and successful at inducing pregnancy in mares (Jepsen et al., 2010; Canisso et al., 2011). It was thought that the problem was an irritational effect of the glycerol cryoprotectant (Trimeche et al., 1998; Vidament et al., 2009). In a recent study of Rota et al. (2012), no differences were observed between semen frozen with glycerol or ethylene glycol as cryo-protectors, in post-thaw motility or fertility. Both cryo-protectors had a similar irritant effect on the jennies' endometrium post AI.

Vidament et al. (2009) using cryo-preserved donkey semen in INRA-82 and glycerol as cryo-protector obtained greater pregnancy rates in mares (36%) than in jennies (11%). Rota et al. (2012) inseminating Amiata jennies with Amiata jackass semen frozen in INRA-96 and glycerol, however, found there was only a 20% pregnancy rate and this rate was only 23.1% when cryo-preserved semen went through the post-thaw process and was re-extended with INRA-96.

Pregnancy results after AI with frozen semen in donkeys are very poor. When using frozen–thawed semen, healthy jennies could be more likely than healthy mares to develop

endometritis. This might be a consequence of the specific physiology differences between the two because of the anatomical conformation of the reproductive tract (with its long and tortuous cervix), lesser uterine drainage, and presence of eosinophils in non-inflamed jenny endometrial tissue (Vendramini et al., 1998; Renner-Martin et al., 2009; Miró et al., 2011; Climent et al., 2012; Vilés et al., 2013).

Studies on the role of SP in mares have focused on sperm-induced endometritis and its effect on fertility (Troedsson et al., 2002; Alghamdi et al., 2004; Schubert et al., 2008). In jennies, *in vitro* studies have shown a favourable effect of SP on sperm motility and reduced PMN-binding (Rota et al., 2008; Miró and Vilés, 2012). An *in vivo* study by means the post-thaw jack semen dilution in seminal plasma showed a trend towards the improvement of fertility (Rota et al., 2012). The mechanism through which SP could improve fertility is its action on the uterine immune response. The aim of the present work was to determine the effect of autologous SP on the endometrial inflammatory response in jennies after AI with frozen–thawed semen, following the changes that occur in uterine histology (via the examination of cytology and biopsy samples) and COX-2 immunohistochemistry.

2. Material and methods

2.1. Animals and experimental design

This research was approved by the Ethics Committee on Animal and Human Experimentation (CEEAH) of the Autonomous University of Barcelona. The experimental animals were six healthy jennies (5–14 years old) in oestrus, all with negative uterine cultures, and one male donkey (6 years old). All were known to be fertile. These animals were fed 2 kg of concentrate per day and had free access to hay, straw and water.

In this cross-over design experiment, endometrial cytology and biopsy samples were taken from each female on the following occasions: (1) during oestrus before any AI procedure (C group), (2) following two subsequent periods of oestrus at 6 h after AI with frozen–thawed sperm (collected from the male donkey) in the absence of SP (–SP group), and (3) following two additional periods of oestrus at 6 h after AI with frozen–thawed sperm (collected from the male donkey) in the presence of SP (+SP group). All semen and SP was deposited directly into the uterus.

2.2. Detection of oestrus and insemination protocol

Oestrus was determined by symptomology, trans-rectal palpation and use of ultrasonic techniques using an Esaote® MyLab™30 5 MHz linear transducer (VET, Genoa, Italy) to check for uterine fluid accumulation, oedema and follicle growth (detection of a follicle >40 mm in diameter and the absence of a corpus luteum). In the –SP and +SP treatments, the jennies were inseminated 24 h after *iv*-administering 2000 IU of human chorionic gonadotrophin (hCG; Chorulon®) (Intervet, Vienna, Austria). The tail was covered with a disposable examination glove and the vulva and perineal region rinsed in warm water and then cleaned with dry paper. Each jenny was

inseminated with eight straws containing frozen–thawed semen (200×10^6 sperm/mL); this was deposited in the uterine body using an equine insemination catheter (Minitübe®, Tiefenbach, Germany) employing the double-glove technique (Portus et al., 2005) with slight modifications. Only straws containing semen showing a total motility of $\geq 70\%$, a progressive motility of $\geq 40\%$ and a viability of $\geq 50\%$ were used. An additional 10 mL of pre-warmed (37°C) autologous SP were carefully deposited in the uterine body of the +SP animals immediately after insemination, using the same catheter (thus reducing cervical manipulation). Ovulation and uterine fluid drainage were evaluated by use of ultrasonic technologies at 24 h.

2.3. Seminal plasma collection

An autologous ejaculate was collected from the stallion one day before the AI procedure, using a Hannover artificial vagina (Minitübe®, Tiefenbach, Germany) equipped with an in-line filter; this provided a gel-free semen sample. After recording its volume, the ejaculate was centrifuged twice at $3000 \times g$ for 15 min at 20°C . The supernatant (i.e., the SP) was recovered and examined using an Olympus BH-2 negative phase contrast microscope with a yellow light filter to confirm the absence of spermatozoa. This SP was then stored at -20°C until use.

2.4. Endometrial cytology

A guarded uterine swab (Minitübe®, Tiefenbach, Germany) was used to obtain an endometrial cytology sample, swabbing the uterus as described by Cocchia et al. (2012). A second cytology sample was obtained by low-volume uterine lavage, infusing 50 mL of Ringer's lactate through the cervix and into the uterus using the equine insemination catheter described above. The uterus was massaged via the rectum and the fluid aspirated back through the catheter to obtain approximately 10% of the liquid introduced. The collected sample was placed in a 10 mL conical tube, and centrifuged at $660 \times g$ for 15 min. The supernatant was removed, except for a small quantity in which the pellet was re-suspended. The uterine swabbing and lavage cytology samples were smeared onto glass microscope slides, air-dried and stained with Diff-Quick (Bio-Optica, Milan, Italy). Differential counting of at least 200 cells (PMN, other inflammatory cells and endometrial cells) was performed by light microscopy (Carl Zeiss, Germany) (magnification $\times 1000$). The percentage of PMN cells was deemed to reflect the inflammatory status of the uterus: $<5\%$ = no inflammation, $5\text{--}15\%$ = mild acute inflammation, $15\text{--}30\%$ = moderate inflammation, and $>30\%$ = severe inflammation (Card et al., 2004).

2.5. Endometrial biopsy

After separating the labia, a sterilized Hauptner biopsy punch covered with a sterile glove was introduced through the vagina and placed in the caudal part of the cervical canal. The tip of the punch was slid through the glove into the uterine lumen. Biopsy samples were taken from the anterior part of the uterine body, removed carefully from

the vagina, and stored in 10% neutral buffered formalin until analysis at our institution's veterinary pathology laboratory. After embedding in paraffin, tissue sections were processed routinely for haematoxylin/eosin (H/E) staining. Five fields per sample without artefacts, intact blood vessels or damaged epithelium were examined by light microscopy (Carl Zeiss, Germany) (magnification $\times 400$). The number, types and location of the different immune cell types (PMNs and other leukocytes) were recorded, and the means for the five fields calculated (Schlafer, 2007). Depending on the number of fibroblast layers surrounding the endometrial glands, fibrosis was scored as absent (0 layers), mild (1–3), moderate (4–10) or severe (≥ 11) (Snider et al., 2011). Other degenerative changes were taken into account using the Kenney and Doig (1986) classification for mare endometritis.

2.6. COX-2 immunohistochemistry

Amount of COX-2 protein was assessed using a standard streptavidin–avidin–biotin immunoperoxidase technique. Briefly, $5 \mu\text{m}$ -thick sections were deparaffinated and endogenous peroxidase activity blocked by exposure to 3% H_2O_2 in distilled water for 5 min. Heat-induced epitope retrieval was performed at $90\text{--}100^\circ\text{C}$ in citrate buffer (pH 6.0) for 10 min, followed by 30 min of cooling at room temperature. Non-specific protein binding was blocked with 2% bovine serum albumin (Sigma–Aldrich, St. Louis, Missouri, USA). The sections were then incubated overnight at 4°C with a polyclonal rabbit anti-murine COX-2 antibody (Cayman Chemical, Ann Arbor, Michigan, USA) diluted 1:500, and then washed with PBS three times (5 min each wash). The slides were then incubated with biotinylated polyclonal goat anti-rabbit secondary antibody (Dako, Glostrup, Denmark) for 1 h, followed by incubation for 1 h with an avidin–biotin–peroxidase complex (ImmunoPure, Thermo Fisher Scientific, Rockford, Illinois, USA). The COX-2 labelling was visualized using 3,3'-diaminobenzidine tetrahydrochloride (Sigma–Aldrich, Madrid, Spain), counterstaining with Mayer's haematoxylin. Negative control sections for each endometrial sample were prepared using normal rabbit serum instead of the primary antiserum. As a positive control, sections of canine squamous cell carcinoma were prepared (Bardagi et al., 2012). The anti-COX-2 reagent used in this study has been shown to detect COX-2 in equine epidermal cells below areas of superficial erosion or ulceration in cutaneous malignant melanoma and squamous cell carcinoma. The number of COX-2 positive cells was inspected by light microscopy (Carl Zeiss, Germany) (magnification $\times 400$) in five randomly selected fields. The scoring system proposed by Jiwakanon et al. (2011) was used to jointly record the number of labelled cells, the intensity of labelling, and the location of labelled cells.

2.7. Statistical analysis

Because not all the data collected were normally distributed (as determined by the Shapiro–Wilks test), the non-parametric Kruskal–Wallis test was used to examine the differences between groups. When significant differences were observed, the corresponding data

Table 1

Mean number of PMN and eosinophils for five microscopic fields (magnification $\times 400$) in endometrial biopsies from jennies in oestrus (C), 6 h after insemination with frozen–thawed sperm but with no SP (–SP), and 6 h after insemination with frozen–thawed sperm but with SP (+SP).

Treatment	PMNs	Eosinophils
C	1.45 \pm 0.80 ^a	27.95 \pm 16.39 ^a
–SP	124.10 \pm 15.42 ^b	69.00 \pm 37.20 ^a
+SP	110.25 \pm 21.24 ^b	25.00 \pm 12.47 ^a

Values with different superscripts in the same column (a, b) indicate significant differences between treatments.

were rank-transformed and means compared using the Tukey–Kramer test. Spearman correlations were calculated to determine the relationships between the cytology, biopsy and COX-2 immunohistochemistry results. Continuous variables were expressed as means \pm SEM and discrete variables as medians and interquartile ranges. Significance was set at $P \leq 0.05$ for all tests. All calculations were performed using SAS[®] v.9.2 software (SAS Institute Inc., Cary, NC, USA).

3. Results

3.1. Ovulation and uterine fluid drainage

All inseminated jennies had ovulations by 24 h after insemination and the absence of uterine fluid was verified in all the cases.

3.2. Cytology

No significant differences were detected between the two cytological techniques (uterine swabbing and uterine lavage) in terms of cell type counts or interpretation. The mean percentage of PMN cells in the –SP (86.88 \pm 7.61) and +SP samples (72.31 \pm 7.24) was significantly greater than in the C samples (1.47 \pm 0.60) ($P < 0.0001$). No significant difference was detected, however, between the –SP and +SP samples.

3.3. Biopsy

A diffuse infiltration of PMN into the luminal epithelium and stratum compactum was observed in both the –SP and +SP samples (no significant difference), with both types having more PMNs than the C samples ($P = 0.01$). The C samples were characterized by an absence of inflammatory cells, except for eosinophils in the stratum compactum and occasionally in the spongiosum. These cells were seen in all treatments (Table 1). A moderate correlation was observed

between the PMN percentages recorded for the cytology and biopsy samples in all groups ($r = 0.71$, $P = 0.009$) but eosinophil numbers did not correlate with PMN numbers, either in the cytology or biopsy samples. Slight fibrosis was observed in 66.7% of the samples as a whole, but no significant differences were between the different groups. No other important degenerative changes were seen in any sample.

3.4. COX-2 immunohistochemistry

Intensely positive COX-2 labelling was observed in the –SP samples compared to the +SP and C samples. Weak COX-2 staining was observed in the +SP and C samples (no significant difference; Table 2). COX-2 staining correlated with the PMN percentages recorded in the cytology ($r = 0.63$; $P = 0.02$) and biopsy ($r = 0.78$; $P = 0.002$) samples. Fig. 1 shows representative images of the biopsy and COX-2 immunohistochemistry results for each treatment group.

4. Discussion

Use of reproductive technologies can enhance effectiveness of breeding programmes for many species. However, each species requires its own AI protocol – even those that are phylogenetically closely related (Pukazhenthil and Wildt, 2004). In donkeys, the expected pregnancy rates are generally achieved when fresh or cooled semen is used in AI, but can be very disappointing when frozen–thawed semen is used (Trimeche et al., 1998; Vidament et al., 2009; Oliveira et al., 2011).

The inflammatory process that occurs after insemination (whether natural or artificial) may involve many linked mechanisms, which might be modulated by SP; the full effects of SP on the female endometrium are not fully understood, and appear to vary between species (Alghamdi et al., 2009). In the present study, the cytological and biopsy samples showed large numbers of PMNs in the endometrium following AI with frozen–thawed semen in both the –SP and +SP groups. Thus, the presence of SP does not seem to affect this variable. The PMNs are also reported to be the main inflammatory cells present 12 h after AI in mares where SP or extenders such as PBS, skim-milk and egg-yolk are present (Palm et al., 2008).

Rota et al. (2012) reported similar number of PMN in uterine lavage samples of +SP jennies at 6 and 10 h after insemination, without differences when post-thaw semen was resuspended in SP for PMN concentration and an increase in PMN proportion. Post-thaw semen re-suspension in SP, however, resulted in an increase in jenny pregnancy rates (8/13, 61.5%). Similarly, in mares,

Table 2

Mean number of positive cells and median scores for COX-2 immunohistochemical labelling in the luminal epithelium and stratum compactum from jennies in oestrus (C), 6 h after insemination with frozen–thawed sperm but with no SP (–SP), and 6 h after insemination with frozen–thawed sperm but with SP (+SP).

Treatment	COX-2 positive cells	Luminal epithelium	Stratum compactum
C	3.35 \pm 0.89 ^a	0.00 \pm 0.50 ^a	0.00 \pm 0.50 ^a
–SP	42.40 \pm 16.64 ^b	5.00 \pm 0.57 ^b	3.00 \pm 0.57 ^b
+SP	8.25 \pm 3.29 ^a	2.00 \pm 0.81 ^a	0.50 \pm 0.50 ^a

Values with different superscripts in the same column (a, b) indicate significant differences between treatments.

Please cite this article in press as: Vilés, K., et al., Influence of seminal plasma on leucocyte migration and amount of COX-2 protein in the jenny endometrium after insemination with frozen–thawed semen. Anim. Reprod. Sci. (2013), <http://dx.doi.org/10.1016/j.anireprosci.2013.11.002>

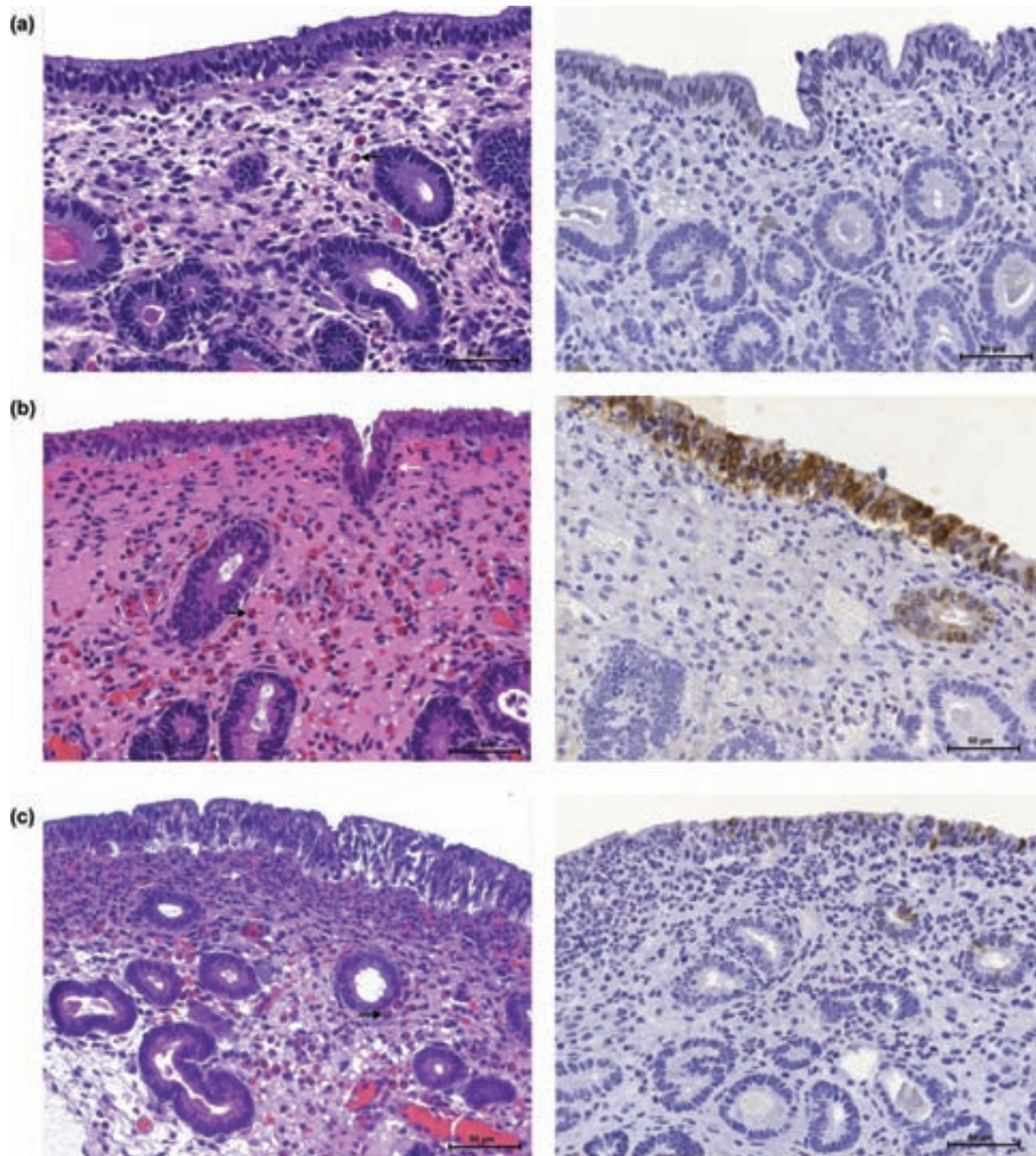


Fig. 1. Representative images showing sections of H/E-stained biopsies and COX-2 immunohistochemical labelling in jennies in oestrus (C), 6 h after insemination with frozen-thawed sperm but with no SP (-SP), and 6 h after insemination with frozen-thawed sperm but with SP (+SP).

increased PMN numbers have been reported in uterine lavage samples at 6 h after AI involving fresh, washed sperm extended in SP compared to the numbers in non-inseminated animals (Portus et al., 2005). Greater pregnancy rates are also reported in mares when sperm is extended in SP (Alghamdi et al., 2004). In addition, comparable numbers of PMN have been observed at 12 h post-AI in uterine swab and uterine lavage cytology samples from mares inseminated with SP, skimmed milk, PBS or egg-yolk (Palm et al., 2006), although numbers were fewer than in the present study. This difference might be explained by the timing of the sample collection procedures in each study.

Unlike in mares and donkeys, a suppressive effect of SP on PMN numbers has been detected on the surface epithelium and sub-epithelial connective tissue in gilts at 6 h post-AI (Jiwakanon et al., 2011). It has been suggested that, in mares, rather than exerting a direct effect on early PMN infiltration, SP shortens the inflammation period (even though it may be pro-inflammatory early after insemination; Katila, 2012); no difference in the number of PMN was detected when using fresh sperm with skimmed milk with or without SP at 6 or 12 h post-insemination, although with SP the numbers were clearly reduced at 24 h (Troedsson et al., 2001; Fiala et al., 2002).

Little information is available regarding the components of semen that contribute towards establishing an optimal uterine environment, but at least in donkeys (present work) and horses (see above), SP does not appear to affect the early influx of PMN into the endometrium. Nevertheless, previous *in vitro* studies have shown an inhibitory effect of SP on the binding of PMN with sperm cells in jennies (Miró and Vilés, 2012), gilts (Li et al., 2012) and mares (Alghamdi et al., 2004; Troedsson et al., 2005). In mares, a specific equine cysteine-rich secretory protein (CRISP3) was recently reported to reduce PMN-sperm cell binding (Doty et al., 2011).

The degenerative fibrotic changes seen in the present research did not correlate with inflammatory status. Further, judging from the C group samples, eosinophils would seem to normally be present in the donkey endometrium, unlike in mares (Miró et al., 2011; Vilés et al., 2013). The significance of the presence of these cells in the donkey endometrium remains unknown.

The substantial COX-2 gene expression observed in the –SP samples was not detected in the SP samples. Indeed, no differences were detected between the +SP and C samples. COX-2 and other cytokines are, however, reported to be upregulated by the presence of SP or extenders 12 h after intrauterine insemination in mares (Palm et al., 2008). In addition, an early increase of COX-2 (6 h after the expected ovulation time) after SP treatment has been observed in pigs, suggesting that SP promotes ovulation by COX-2 stimulation and the subsequent uterine synthesis of prostaglandins that eventually reach the ovaries (O'Leary et al., 2006). However, the same authors described reduced mRNA for COX-2 at day 5 and 9 after SP treatment, probably to favour the pre-implantation progress. Taylor et al. (2009) reported a lesser COX-2 gene expression at 3 h after-AI in the presence of SP compared to Androhep™. In humans, increases in PMNs, T-cells, cytokines, and COX-2 are reported in the cervix 12 h after exposure to semen (Sharkey et al., 2012).

In contrast to that reported in other studies, the present results show that in donkeys, at 6 h post-AI with frozen–thawed semen, SP appears to modify the inflammatory response by inhibiting COX-2 gene expression in both the luminal epithelium and stratum compactum. This would block the synthesis of prostaglandins and PMN chemotaxis, reducing the amplitude of the primary signs of inflammation, as occurs after the administration of COX-2 inhibitors (Serhan et al., 2008). It would be interesting to explore which mechanisms of the endometrial inflammatory response are affected by the presence of SP in jennies as this knowledge might help improve fertility when frozen–thawed semen is used in this species. Interestingly, increased pregnancy rates with frozen–thawed semen have been recently obtained in jennies following deep intrauterine insemination using greater than typical sperm concentrations (Oliveira et al., 2012) – a procedure that leads to an accelerated resolution of the inflammatory response in mares (Fiala et al., 2007). Perhaps, a greater sperm concentration induces a saturation of PMN and then the free spermatozoa are able to fertilize, or the deep intrauterine AI near the oviduct may help to avoid the extent of contact with PMN that typically occurs. The

combination of high frozen–thawed sperm concentrations, deep-horn intrauterine AI, and the addition of SP in this procedure, might improve pregnancy rates in jennies.

In conclusion, frozen–thawed donkey semen (with or without SP) induces a massive influx of PMN into the jenny endometrium. Although conventional (–SP) frozen semen insemination initiates an intense COX-2 gene expression by 6 h post AI, the addition of SP to the inseminate reduces the COX-2 gene expression to levels of the control group (C).

References

- Alghamdi, A., Lovaas, B., Bird, S., Lamb, G., Rendahl, A., Taube, P., Foster, D., 2009. Species-specific interaction of seminal plasma on sperm–neutrophil binding. *Anim. Reprod. Sci.* 114, 331–344.
- Alghamdi, A.S., Foster, D.N., Troedsson, M.H., 2004. Equine seminal plasma reduces sperm binding to polymorphonuclear neutrophils (PMNs) and improves the fertility of fresh semen inseminated into inflamed uteri. *Reproduction* 127, 593–600.
- Aloé, S., Weber, F., Behr, B., Sauter-Louis, C., Zerbe, H., 2012. Modulatory effects of bovine seminal plasma on uterine inflammatory processes. *Reprod. Domest. Anim.* 47, 12–19.
- Bardagi, M., Fondevila, D., Ferrer, L., 2012. Immunohistochemical detection of COX-2 in feline and canine actinic keratoses and cutaneous squamous cell carcinoma. *J. Comp. Pathol.* 146, 11–17.
- Canisso, I.F., Carvalho, G.R., Morel, M.D., Ker, P.G., Rodrigues, A.L., Silva, E.C., Coutinho Da Silva, M.A., 2011. Seminal parameters and field fertility of cryopreserved donkey jack semen after insemination of horse mares. *Equine Vet. J.* 43, 179–183.
- Card, C., Carley, S., Green, J., Chirino-Trejo, M., 2004. Endometrial cytology in mares bred with frozen semen. In: *Proceedings of the 50th convention of the AAEP, Denver, Colorado, USA. The American Association of Equine Practitioners*, pp. 505–509.
- Climent, F., Vilés, K., Miró, J., 2012. Vaginoplastia in two young infertile Catalan jennies. A clinical case. *Reprod. Domest. Anim.* 47, 113.
- Cocchia, N., Paciello, O., Auletta, L., Uccello, V., Silvestro, L., Mallardo, K., Paraggio, G., Pasolini, M., 2012. Comparison of the cytobrush, cottonswab, and low-volume uterine flush techniques to evaluate endometrial cytology for diagnosing endometritis in chronically infertile mares. *Theriogenology* 77, 89–98.
- Doty, A., Buhi, W.C., Benson, S., Scoggin, K.E., Pozor, M., Macpherson, M., Mutz, M., Troedsson, M.H., 2011. Equine CRISP3 modulates interaction between spermatozoa and polymorphonuclear neutrophils. *Biol. Reprod.* 85, 157–164.
- Fiala, S.M., Pimentel, C.A., Mattos, A.L., Gregory, R.M., Mattos, R.C., 2007. Effect of sperm numbers and concentration on sperm transport and uterine inflammatory response in the mare. *Theriogenology* 67, 556–562.
- Fiala, S., Pimentel, C., Steiger, K., Mattos, A.L., Gregory, R.M., Mattos, R.C., 2002. Effect of skim milk and seminal plasma uterine infusions in mares. *Theriogenology* 58, 491–494.
- Jepsen, R., Evans, L., Youngs, C., 2010. Use of direct thaw insemination to establish pregnancies with frozen–thawed semen from a standard jack. *J. Equine Vet. Sci.* 30, 651–656.
- Jiwakanon, J., Persson, E., Berg, M., Dalin, A., 2011. Influence of seminal plasma, spermatozoa and semen extender on cytokine expression in the porcine endometrium after insemination. *Anim. Reprod. Sci.* 123, 210–220.
- Katila, T., 2012. Post-mating inflammatory responses of the uterus. *Reprod. Domest. Anim.* 47, 31–41.
- Katila, T., 2005. Effect of the inseminate and the site of insemination on the uterus and pregnancy rates of mares. *Anim. Reprod. Sci.* 89, 31–38.
- Katila, T., 2001. Sperm–uterine interactions: a review. *Anim. Reprod. Sci.* 68, 267–272.
- Kenney, R., Doig, P., 1986. Equine endometrial biopsy. *Theriogenology* 2, 723–729.
- Kotilainen, T., Huhtinen, M., Katila, T., 1994. Sperm-induced leukocytosis in the equine uterus. *Theriogenology* 41, 629–636.
- Li, J., Yamaguchi, S., Funahashi, H., 2012. Boar seminal plasma or hen's egg yolk decrease the *in-vitro* chemotactic and phagocytotic activities of neutrophils when co-incubated with boar or bull sperm. *Theriogenology* 77, 73–80.
- Miró, J., Vilés, K., 2012. Seminal plasma to control induced acute endometritis by frozen semen in jennies. *Reprod. Domest. Anim.* 47, 58–115.

- Miró, J., Vilés, K., Fernández, N., Soares, J., Fábregas, N., García, W., 2011. Induced acute endometritis by frozen semen insemination in donkey. *Reprod. Domest. Anim.* 46, 130.
- O'Leary, S., Jasper, M.J., Robertson, S.A., Armstrong, D.T., 2006. Seminal plasma regulates ovarian progesterone production, leukocyte recruitment and follicular cell responses in the pig. *Reproduction* 132, 147–158.
- O'Leary, S., Jasper, M.J., Warnes, G.M., Armstrong, D.T., Robertson, S.A., 2004. Seminal plasma regulates endometrial cytokine expression, leukocyte recruitment and embryo development in the pig. *Reproduction* 128, 237–247.
- Oliveira, J.V., Papa, F.O., Melo-Oña, C.M., Monteiro, G.A., Puoli-Filho, J.N.P., Alvarenga, M.A., 2012. New procedures to freeze donkey semen and its influence on mares and jennies fertility. *J. Equine Vet. Sci.* 32, 503–504.
- Oliveira, J., Ozanam, F., Monteiro, J., Marini, C., Alvarenga, M., 2011. Nascimento do primeiro jumento a partir de espermatozoides congelados no Brasil. In: Proceedings of the XII ABRAVEQ Annual Conference, Campinas, Sao Paulo, Brasil. The Brazilian Association of Equine Practitioners, p. 203.
- Oliveira, J., Alvarenga, M., Melo, C., Macedo, M., Dell'Aqua, J., Papa, F., 2006. Effect of cryoprotectant on donkey semen freezability and fertility. *Anim. Reprod. Sci.* 94, 82–84.
- Palm, F., Walter, I., Budik, S., Kolodziejek, J., Nowotny, N., Aurich, C., 2008. Influence of different semen extenders and seminal plasma on PMN migration and on expression of IL-1 β , IL-6, TNF- α and COX-2 mRNA in the equine endometrium. *Theriogenology* 70, 843–851.
- Palm, F., Walter, I., Budik, S., Aurich, C., 2006. Influence of different semen extenders and seminal plasma on the inflammatory response of the endometrium in oestrous mares. *Anim. Reprod. Sci.* 94, 286–289.
- Portus, B.J., Reilas, T., Katila, T., 2005. Effect of seminal plasma on uterine inflammation, contractility and pregnancy rates in mares. *Equine Vet. J.* 37, 515–519.
- Pukazhenth, B.S., Wildt, D.E., 2004. Which reproductive technologies are most relevant to studying, managing and conserving wildlife? *Reprod. Fertil. Dev.* 16, 33–46.
- Renner-Martin, T.F., Forstenpointner, G., Weissengruber, G.E., Eberhardt, L., 2009. Gross anatomy of the female genital organs of the domestic donkey (*Equus asinus* Linne, 1758). *Anat. Histol. Embryol.* 38, 133–138.
- Robertson, S.A., 2007. Seminal fluid signaling in the female reproductive tract: lessons from rodents and pigs. *J. Anim. Sci.* 85, E36–E44.
- Robertson, S.A., 2005. Seminal plasma and male factor signalling in the female reproductive tract. *Cell Tissue Res.* 322, 43–52.
- Rota, A., Panzani, D., Sabatini, C., Camillo, F., 2012. Donkey jack (*Equus asinus*) semen cryopreservation: studies of seminal parameters, post breeding inflammatory response, and fertility in donkey jennies. *Theriogenology* 78, 1846–1854.
- Rota, A., Magelli, C., Panzani, D., Camillo, F., 2008. Effect of extender, centrifugation and removal of seminal plasma on cooled-preserved Amiaata donkey spermatozoa. *Theriogenology* 69, 176–185.
- Rozeboom, K.J., Rocha-Chavez, G., Troedsson, M.H., 2001. Inhibition of neutrophil chemotaxis by pig seminal plasma in vitro: a potential method for modulating post-breeding inflammation in sows. *Reproduction* 121, 567–572.
- Schlafer, D.H., 2007. Equine endometrial biopsy: enhancement of clinical value by more extensive histopathology and application of new diagnostic techniques? *Theriogenology* 68, 413–422.
- Schuberth, H.J., Taylor, U., Zerbe, H., Waberski, D., Hunter, R., Rath, D., 2008. Immunological responses to semen in the female genital tract. *Theriogenology* 70, 1174–1181.
- Serhan, C.N., Chiang, N., Van Dyke, T.E., 2008. Resolving inflammation: dual anti-inflammatory and pro-resolution lipid mediators. *Nat. Rev. Immunol.* 8, 349–361.
- Sharkey, D.J., Tremellen, K.P., Jasper, M.J., Gemzell-Danielsson, K., Robertson, S.A., 2012. Seminal fluid induces leukocyte recruitment and cytokine and chemokine mRNA expression in the human cervix after coitus. *J. Immunol.* 188, 2445–2454.
- Sieme, H., Bonk, A., Hamann, H., Klug, E., Katila, T., 2004. Effects of different artificial insemination techniques and sperm doses on fertility of normal mares and mares with abnormal reproductive history. *Theriogenology* 62, 915–928.
- Snider, T.A., Sepoy, C., Holyoak, G.R., 2011. Equine endometrial biopsy reviewed: observation, interpretation, and application of histopathologic data. *Theriogenology* 75, 1567–1581.
- Taylor, U., Zerbe, H., Seyfert, H.M., Rath, D., Baulain, U., Langner, K.F., Schuberth, H.J., 2009. Porcine spermatozoa inhibit post-breeding cytokine induction in uterine epithelial cells in vivo. *Anim. Reprod. Sci.* 115, 279–289.
- Tomlinson, M.J., White, A., Barratt, C.L., Bolton, A.E., Cooke, I.D., 1992. The removal of morphologically abnormal sperm forms by phagocytes: a positive role for seminal leukocytes? *Hum. Reprod.* 7, 517–522.
- Töpfer-Petersen, E., Ekhlasi-Hundrieser, M., Kirchhoff, C., Leeb, T., Sieme, H., 2005. The role of stallion seminal proteins in fertilisation. *Anim. Reprod. Sci.* 89, 159–170.
- Trimeche, A., Renard, P., Tainturier, D., 1998. A procedure for poitou jackass sperm cryopreservation. *Theriogenology* 50, 793–806.
- Troedsson, M.H.T., Desvousges, A., Alghamdi, A.S., Dahms, B., Dow, C.A., Hayna, J., Valesco, R., Collahan, P.T., Macpherson, M.L., Pozor, M., Buhi, W.C., 2005. Components in seminal plasma regulating sperm transport and elimination. *Anim. Reprod. Sci.* 89, 171–186.
- Troedsson, M., Alghamdi, A., Mattisen, J., 2002. Equine seminal plasma protects the fertility of spermatozoa in an inflamed uterine environment. *Theriogenology* 58, 453–456.
- Troedsson, M.H., Loset, K., Alghamdi, A.M., Dahms, B., Crabo, B.G., 2001. Interaction between equine semen and the endometrium: the inflammatory response to semen. *Anim. Reprod. Sci.* 68, 273–278.
- Vendramini, O., Guintard, C., Moreau, J., Tainturier, D., 1998. Cervix conformation: a first anatomical approach in baudet du poitou jenny asses. *Cambridge J.* 66, 741–744.
- Vidament, M., Vincent, P., Martin, F., Magistrini, M., Blesbois, E., 2009. Differences in ability of jennies and mares to conceive with cooled and frozen semen containing glycerol or not. *Anim. Reprod. Sci.* 112, 22–35.
- Vidament, M., 2005. French field results (1985–2005) on factors affecting fertility of frozen stallion semen. *Anim. Reprod. Sci.* 89, 115–136.
- Vilés, K., Rabanal, R., Rodríguez-Prado, M., Miró, J., 2013. Effect of ketoprofen treatment on the uterine inflammatory response in jennies after artificial insemination with frozen-thawed semen. *Theriogenology* 79, 1019–1026.



Discusión / Discussion

4. Discusión / Discusión

La fecundación es un suceso que requiere interacciones específicas entre componentes del sistema reproductor del macho y la hembra de una especie o en algunos casos, entre especies de la misma familia taxonómica. Tras la deposición del semen, los espermatozoides son reconocidos inicialmente como cuerpo extraño en el tracto reproductivo de la hembra y desencadenan una respuesta inflamatoria normal del endometrio (Katila, 2012). Este aspecto ha sido ampliamente estudiado en la yegua y otras especies de interés comercial, donde las tecnologías reproductivas como la IA con semen criopreservado representan una herramienta importante para el aprovechamiento de características genéticas deseadas.

La intervención humana para la obtención de descendientes de forma artificial en asnos ha sido menor y los resultados de fertilidad tras la IA con semen criopreservado en burros son escasos (Trimeche et al., 1998; Vidament et al., 2009; Oliveira et al., 2011) fundamentalmente por la falta de conocimientos básicos sobre la reproducción en el burro. La caracterización y evaluación del endometrio, constituye una información necesaria para la aplicación de cualquier tecnología reproductiva artificial. En la yegua, la citología y cultivo endometrial son unas técnicas diagnósticas comúnmente utilizadas en campo que proveen una información presuntiva del ambiente endometrial, pero la biopsia endometrial es la herramienta de elección para realizar un diagnóstico definitivo del estado del endometrio y un pronóstico en yeguas (Nielsen, 2005; Schlafer, 2007; Cocchia et al., 2012). Las investigaciones sobre el ambiente endometrial en la burra son escasas. En la burra catalana, la citología y biopsia del endometrio sano (en estro) se caracterizó por la presencia de células endometriales, debris y un escaso número de células inflamatorias (a excepción de un infiltrado de eosinófilos presente en todas las muestras) sin cambios degenerativos importantes. Un gran aumento del número de neutrófilos polimorfonucleares (PMN) tanto en las citologías (lavado e hisopado) como en las biopsias endometriales a las 6 h post-IA, fue indicativo de endometritis aguda, como determinan Summerfield y Watson (1998). Se han observado

resultados similares en citologías uterinas tomadas a las 6 h post-IA, mediante lavado en burras de raza Amiata (Rota et al., 2012) e hisopado en burras de raza Pega (Oliveira, 2005), en las cuales, la fertilidad con semen congelado fue muy baja. En yeguas, el compromiso de la fertilidad debido a una endometritis post-IA solo se observa en aquellas hembras que han desarrollado endometritis persistente con cambios degenerativos importantes en el útero u otras alteraciones anatómicas del tracto reproductivo (Watson, 2000; Maischberger et al., 2008).

El aspecto histológico del endometrio de la burra no había sido previamente estudiado, destacándose diferencias con la yegua. La presencia de infiltrados de eosinófilos en el endometrio tanto en estro como post-IA, fue un hallazgo interesante, ya que en yeguas, estas células inflamatorias solo se observan tras una historia de anafilaxis, lesiones vestibulares, neumovagina o infecciones por hongos en útero (Slusher et al., 1984; Snider et al., 2011); dichas patologías no se presentaron en las burras del experimento. Tampoco se encontró relación de los eosinófilos con otras células inflamatorias o cambios degenerativos, a diferencia de un estudio en burras de Egipto, donde se observaron infiltrados de eosinófilos en endometrios clasificados como tipo IIB (endometritis crónica) según la clasificación de Kenney y Doig (1986). Sin embargo, las biopsias endometriales de ese estudio provenían de una planta de sacrificio y se desconocía la historia clínica de los individuos muestreados (Sokkar et al., 2001). Al menos en nuestra raza de burro, los eosinófilos parecen constituir parte del ambiente endometrial normal en estro y su proporción no es afectada por la IA. Esta particular característica también ha sido reportada en ovejas en estro y tampoco se ve influenciada por la IA (Scott et al., 2009). Hasta el momento, la presencia de eosinófilos en el endometrio de la burra no había sido documentada, pero es evidente que, si existen diferencias anatómicas (Renner-Martin et al., 2009), fisiológicas (Taberner et al., 2008) e histológicas del tracto reproductivo de la burra respecto a la yegua, los mecanismos de limpieza uterina también son diferentes y especie-específicos. Aunque se necesitan más estudios, estas características podrían predisponer el desarrollo de endometritis post-inseminación en la burra y por tanto, el control de la respuesta inflamatoria del endometrio durante el protocolo de IA con semen congelado debe constituir un objetivo importante para mejorar los resultados de fertilidad en burros.

Se han utilizado diferentes anti-inflamatorios para controlar la endometritis inducida por la inseminación en yeguas. La terapia con AINEs ha mostrado reducir la inflamación y en algunos casos incrementar las tasas de preñez principalmente en yeguas con endometritis persistente. Risco et al. (2009) encontraron una reducción del influjo inicial de PMN tras la IA en yeguas tratadas con flumixin meglumine y Rojer et al. (2010) utilizaron vedaprofen durante la IA, sin obtener una reducción significativa de PMN, aunque posteriormente encontraron una inhibición temprana de COX-2 en endometrio y una reducción significativa de PMN cuando el medicamento era administrado 24 h después de la IA (Aurich et al., 2010). El uso de corticosteroides también ha mostrado resultados similares respecto al número de PMN a las 6 y 12 h post-IA (Bucca et al., 2008), así como una disminución del edema uterino a las 24 h (Stout, 2012). Dell'Aqua et al. (2006), tampoco encontraron una reducción de PMN, ni de COX-2 a las 24 h post-IA, pero obtuvieron un aumento de la fertilidad en yeguas infértiles tratadas con un prednisona.

El tratamiento con ketoprofen durante la IA con semen congelado/descongelado en la burra catalana, disminuyó la expresión de COX-2 principalmente en el estrato compacto del endometrio y no influyó sobre el número de PMN producidos a las 6 h post-IA. La inhibición de COX-2 se considera el principal efecto anti-inflamatorio de los AINEs (Moses y Bertone, 2002; Kollias-Baker y Cox, 2004), pero otros mecanismos de acción del ketoprofen podrían ser investigados en el endometrio de la burra post-inseminación, por ejemplo, en humanos el ibuprofen ha mostrado inhibir la enzima β -glucuronidasa, que es una sustancia producida por los PMN en los exudados inflamatorios e indica su grado de activación (Villanueva et al, 1993). También se ha observado una inhibición de la expresión de esta enzima tras la administración de ketoprofen en caballos (Landoni y Lees, 1995). En el burro catalán, el ketoprofen mostró un rápido metabolismo respecto al caballo (Corveleyn et al., 1996; Landoni y Lees, 1996), reflejado por una vida media corta en plasma, rápida eliminación y escasa distribución tisular aparente. Estas diferencias farmacocinéticas pueden afectar la disponibilidad del medicamento en los tejidos inflamados y por tanto, deben ser tenidas en cuenta para la instauración de una dosis específica que sea segura y efectiva en burros.

Los efectos moduladores del plasma seminal (PS) sobre los espermatozoides y la inflamación endometrial post-IA, también parecen ofrecer una alternativa en el tratamiento de la endometritis inducida por el semen en diferentes especies (Rozeboom et al., 2001; Li et al., 2012). En la segunda investigación de esta tesis doctoral, se evaluó el efecto *in Vitro* del PS sobre los espermatozoides y los PMN endometriales en el burro catalán. La presencia de PS en el semen fresco puro y fresco diluido, disminuyó la actividad inflamatoria de los PMN, expresada por un menor número de PMN adheridos a espermatozoides que los observados en las muestras de semen congelado. Existen estudios similares en caballos, donde además, se detalla la naturaleza proteica de varios componentes supresores de PMN (Alghamdi et al., 2004; Töpfer-Petersen et al., 2005; Doty et al., 2011). Estas proteínas del PS específicas para cada especie, inhiben la quimiotaxis de PMN, la activación del complemento, opsonización y fagocitosis de espermatozoides (Rozeboom et al., 2001; Troedsson et al., 2005; Taylor et al., 2009a; Alghamdi et al., 2009; Li et al., 2012). No obstante, el PS también parece favorecer la fagocitosis de espermatozoides viejos, muertos o hiperactivados (no viables), participando en los procesos de selección espermática (Troedsson et al., 2006; Eisenbach, 2003).

La alteración de la motilidad espermática por la formación de agregados PMN-espermatozoides, así como la influencia del PS sobre la misma, también forma parte de los mecanismos de selección de espermatozoides (Jaffe et al., 2006; Troedsson et al., 1998). Similar a lo observado en caballos (Troedsson et al., 1998a; Alghamdi et al., 2001), la motilidad total, motilidad progresiva, velocidad promedio y linealidad espermática (MT, MP, VAP, LIN) del semen de burro, fueron las variables de motilidad más afectadas tras la incubación con PMN endometriales de burra; y el semen congelado mostró una mayor alteración de las mismas. Estas características son necesarias para el transporte del espermatozoide a través del útero (Olds-Clarke, 1996; Liu y Scott, 2000) como ha sido previamente descrito en equinos, donde la extracción del PS durante el proceso de criopreservación disminuyó el transporte espermático en el útero (Troedsson et al., 1998b). Por lo contrario, de Andrade et al., (2010) encontraron una disminución de la linealidad (LIN) en muestras de semen congelado/descongelado de caballo a los 5 min de incubación con PS, no obstante, las velocidades (VCL, VAP, VSL) no fueron afectadas y se

mantuvo una mayor integridad de membrana. Este último aspecto también ha sido observado en ovinos, donde además se observó un aumento de la tasa de fertilización *in Vitro* (FIV) de oocitos maduros tras la resuspensión de semen congelado/descongelado en PS (El-Hajj Ghaoui et al., 2007).

Existe cierta controversia respecto al papel *in Vivo* del PS en la inflamación endometrial, pero los estudios coinciden en observar un incremento de los índices de preñez en burras, yeguas, cerdas y vacas inseminadas en presencia de PS (Rozeboom et al., 2000; Alghamdi et al., 2004; Yamaguchi et al., 2009; Odhiambo et al., 2009; Heise et al., 2010; Rota et al., 2012). En la última investigación de la presente tesis, se determinó el efecto de la administración intrauterina de PS durante la IA con semen congelado/descongelado en la burra catalana. Los resultados en endometrio fueron similares a los obtenidos con la administración de ketoprofen durante la IA (inhibición de COX-2 sin influencia sobre el número de PMN tanto en citologías como en biopsias). No obstante, es posible deducir que el PS mostró un mayor efecto anti-inflamatorio sobre la expresión de COX-2 que el ketoprofen, ya que se encontraron diferencias significativas tanto en el epitelio luminal como en el estrato compacto del endometrio respecto a la IA sin tratamiento, de hecho, el aspecto inmunohistoquímico del endometrio post-IA con PS fue similar al endometrio no inflamado en estro. En contraste a lo observado, la expresión de COX-2 y otras citoquinas ha mostrado un incremento en presencia de PS en cerdas y yeguas a las 6 h pre-ovulación y 12 h post-ovulación, respectivamente (O'Leary et al., 2004; Palm et al., 2008). Asimismo, se ha descrito un aumento de PMN, células-T y COX-2 en cérvix tras 12 h de exposición al semen en humanos (Sharkey et al., 2012). Sin embargo, similar a la burra catalana, Taylor et al. (2009b) encontraron una menor expresión de COX-2, así como de la interleucina-8 (CXCL-8, citoquina relacionada con el reclutamiento de neutrófilos) a las 3 h de inseminación con PS comparado con un extender (Androhep™) en cerdas, además de una correlación de esta última citoquina con el número de PMN endometriales.

En el presente estudio, el PS no influyó sobre la cantidad de PMN endometriales al menos a las 6 h post-IA, habiéndose obtenido resultados similares en burras de raza Amiata (Rota et al., 2012) y en yeguas (Troedsson et al., 2001; Palm et al.,

2008). Algunos autores describen un aumento del número de PMN y líquido intrauterino (Dell'Aqua et al., 2006; Taylor et al., 2009a), así como una reducción de las contracciones uterinas a las 6 h post-IA en presencia del PS en yeguas (Portus et al., 2005). Sin embargo, se ha observado un efecto supresor sobre el número de PMN a las 6 y 35-40 h post-IA en cerdas (Jiwakanon et al., 2011), posiblemente, gracias a la inhibición de ciertas citoquinas (y otras aún no determinadas) como la COX-2 y las mencionadas anteriormente (Taylor et al., 2009b), que intervienen en la quimiotaxis y migración de PMN en el endometrio (Matthijs et al., 2003; Gorgens et al., 2005). En yeguas, diferentes estudios han obtenido una reducción del número de PMN a las 24-36 h post-IA en presencia de PS, coincidiendo en que posiblemente el mecanismo de acción del PS consiste en acelerar la resolución de la inflamación más que reducir la inflamación a corto plazo (Troedsson et al., 2001; Fiala et al., 2002 Palm et al., 2006; Katila, 2012).

El PS ocasiona diferentes efectos sobre las mismas moléculas en tiempos diferentes y sus mecanismos de modulación son especie-específicos. En la burra catalana, el PS redujo la inflamación endometrial mediante inhibición de la agregación de PMN-espermatozoides *in Vitro* y de la expresión de COX-2 (principal indicador de la inflamación inducida) *in Vivo* a las 6 h de IA con semen congelado/descongelado, además de un efecto de selección de la motilidad espermática *in Vitro*. Si bien es cierto que la eliminación del PS durante los procesos de refrigeración y congelación de semen en burros es necesaria, ya que incrementa la viabilidad de los espermatozoides como ha sido descrito en razas autóctonas de España como el asno Zamorano-Leonés (Serres, 2003) y el burro Catalán (Miró et al., 2009), el papel del PS en las interacciones semen-endometrio debe considerarse un punto clave en la reproducción con semen congelado en burros, ya que su utilización para el control de la inflamación endometrial post-IA podría incrementar los resultados de fertilidad de esta tecnología reproductiva, aumentando las posibilidades de éxito de los programas de conservación de razas de amenazadas de burro, así como en otras especies susceptibles a desarrollar endometritis post-inseminación.



Conclusiones finales/Final Conclusions

5. Conclusiones finales/Final conclusions

1. El aspecto histológico del endometrio de la burra catalana en celo se asemeja al endometrio de la yegua en celo. Sin embargo, la presencia de eosinófilos en el estrato compacto y esponjoso parece constituir una característica del endometrio de la burra sana en celo y además, su proporción no cambia tras la IA con semen congelado/descongelado.
2. La burra sana parece ser más susceptible que la yegua sana a desarrollar endometritis post-IA con semen congelado/descongelado debido a diferencias en su tracto reproductivo. De forma similar a otras especies, esta respuesta inflamatoria se caracteriza por una migración de grandes cantidades de PMN, edema y liberación de citoquinas en el útero; pero a diferencia de la yegua sana y como ocurre en yeguas con endometritis persistente, esta inflamación parece reducir las posibilidades de fecundación pese a una adecuada calidad del semen utilizado.
3. La administración intravenosa de ketoprofen durante la IA con semen congelado/descongelado reduce la respuesta inflamatoria del endometrio mediante inhibición de la expresión de COX-2, principalmente en el estrato compacto. No obstante, la ausencia de una dosis determinada y las diferencias farmacocinéticas del ketoprofen en el burro respecto al caballo (vida media corta, rápida eliminación y escasa distribución tisular aparente), son aspectos que afectan la disposición del medicamento en los tejidos inflamados y por tanto, deben ser considerados para el control de la endometritis post-IA en la burra.

4. El plasma seminal (PS) produce efectos moduladores sobre los espermatozoides y la inflamación endometrial en el burro catalán. Por una parte, reduce la formación de agregados PMN-espermatozoides y selecciona los espermatozoides con mayor motilidad progresiva *in Vitro*. En segundo lugar, inhibe la expresión de COX-2 tanto en el epitelio luminal como en el estrato compacto del endometrio y no afecta la cantidad de PMN endometriales *in Vivo* a las 6 h de IA con semen congelado/descongelado.



Bibliografía / Bibliography

6. Bibliografia / Bibliography

- Adams G, Ratto M, Collins, Bergfelt D.** (2009) Artificial insemination in South American camelids and wild equids. *Theriogenology* 71:166-175.
- Allen WR.** (2005) The Development and Application of the Modern Reproductive Technologies to Horse Breeding. *Reprod. Dom. Anim.* 40:310-329.
- Alghamdi AS, Troedsson MH, Laschkewitsch T, Xue JL.** (2001) Uterine secretion from mares with post-breeding endometritis alters sperm motion characteristics in vitro. *Theriogenology* 55(4):1019-1028.
- Alghamdi AS, Foster DN, Troedsson MH.** (2004) Equine seminal plasma reduces sperm binding to polymorphonuclear neutrophils (PMNs) and improves the fertility of fresh semen inseminated into inflamed uteri. *Reproduction* 127(5):593-600.
- Alghamdi AS, Lovaas BJ, Bird SL, Lamb GC, Rendahl AK, Taube PC, Foster DN.** (2009) Species-specific interaction of seminal plasma on sperm-neutrophil binding. *Anim. Reprod. Sci.* 114(4):331-344.
- Àlvarez, A.** (2005) Actuaciones para la conservación del Asno Zamorano-Leonés, Inseminación Artificial con semen refrigerado y congelado. Tesis Doctoral. Universidad Complutense de Madrid, España.
- Andrabi S, Maxwell W.** (2007) A review on reproductive biotechnologies for conservation of endangered mammalian species. *Anim. Reprod. Sci.* 99:223-243.
- Antasolus.** Associazione Nazionale Terapie Alternative e Solidali. [Internet] Roma, Itália. [citado 15 Ene 2013] Disponible en: <<http://www.antonlus.org/>>
- Apassodasino.** Cooperativa Sociale Onlus "A passo d'Asino" [Internet] Milan, Itália. [citado 15 Ene 2013] Disponible en: <<http://www.apassodasino.org/>>

- Aranguren-Mendez J, Jordana J, Gomez M.** (2002) Genetic conservación of five endangered Spanish donkey breeds. *J. Anim. Breed.* 119: 256-263.
- Aurich C, Rojer H, Walter I.** (2010) Treatment of estrous mares with the non-steroidal anti-inflammatory drug vedaprofen reduces the inflammatory response of the endometrium to insemination. *Anim Reprod Sci* 121:104-106.
- Aurich JE.** (2012) Artificial insemination in Horses – More than a Century of Practice and Research. *J. Equine. Vet. Sci.* 32:458 – 463.
- Bailey S.** (2010) Corticosteroid associated laminitis. *Vet. Clin. Equine.* 26:277-285.
- Barbacini S, Necchi D, Zavaglia G, Squires EL.** (2003) Retrospective study on the incidence of postinsemination uterine fluid in mares inseminated with frozen/thawed semen. *J. Equine. Vet. Sci.* 23(11):493-496.
- Bucca S, Carli A, Buckley T, Dolci G, Fogarty U.** (2008) The use of dexamethasone administered to mares at breeding time in the modulation of persistent mating induced endometritis. *Theriogenology* 70(7):1093-1100.
- Canisso I, Souza F, Ortigoza J, Carvalho G, Morel M, da Silva E, Guimarães J, Lima A.** (2008) Congelamiento de semen de burro (*Equus asinus*). *Rev. Inv. Vet. Perú.* 19(2):113-125.
- Canisso I, Carvalho G, Morel M, Ker P, Rodrigues A, Silva E, Coutinho da Silva M.** (2011) Seminal parameters and field fertility of cryopreserved donkey jack semen after insemination of horse mares. *Equine. Vet. J.* 43(2):179-183.
- Card C, Carley S, Green J, Chirino-Trejo M.** (2004) Endometrial Cytology in Mares Bred with Frozen Semen. In: Proceedings of the 50th convention of the AAEP, Denver, Colorado, USA. *Reproduction* 505-509.
- Card C.** (2005) Post-breeding inflammation and endometrial cytology in mares. *Theriogenology* 64(3):580-588.
- Chaouat G.** (2007) The Th1/Th2 paradigm: still important in pregnancy?. *Semin. Immunopathol.* 29: 95-113

- Climent F, Vilés K, Miró J.** (2012) Vaginoplastia in two young infertile Catalan jennies. A clinical case. *Reprod. Dom. Anim.* 47(3):113.
- Cocchia N, Paciello O, Auletta L, Uccello V, Silvestro L, Mallardo K.** (2012) Comparison of the cytobrush, cottonswab, and low-volume uterine flush techniques to evaluate endometrial cytology for diagnosing endometritis in chronically infertile mares. *Theriogenology* 77:89-98.
- Comizzoli P, Mermillod P, Mauget R.** (2000). Reproductive biotechnologies for endangered mammalian species. *Reprod. Nutr. Dev.* 40:493-504.
- Corveleyn S, Deprez P, Van der Weken G, Baeyens W, Remon J.** (1996) Bioavailability of ketoprofen in horses after rectal administration. *J. Vet. Pharmacol. Therap.* 19:359-363.
- Cosentino C, Paolino R, Freschi P, Calluso A.** (2012) Jenny milk production and qualitative characteristics. *J. Dairy. Sci.* 95:2910-2915.
- Cosentino, C., Freschi, P., Paolino, R., Valentini, V.** (2013). Market sustainability analysis of jenny milk cosmetics. *Emir. J. Food. Agric.* 25 (8): 635-640
- DAD-IS** (2011) Domestic Animal Diversity Information System. (DAD-IS), Food and Agriculture Organization of the United Nations. <<http://www.fao.org/dad-is/>>.
- deAndrade A, Zaffalon F, Celeghini E, Nascimento J, Tarragó O, Martins S, Alonso M, Arruda R.** (2011) Addition of seminal plasma to Post-thawing equine semen: What is the effect on sperm cell viability. *Reprod. Dom. Anim.* 46:682-686.
- Dell'Aqua Jr, Papa FO, Lopes MD, Alvarenga MA, Macedo LP, Melo CM.** (2006) Modulation of acute uterine inflammatory response after artificial insemination with equine frozen semen. *Anim. Reprod. Sci.* 94:270-273.
- Doty A, Buhi W, Benson S, Scoggin K, Pozor M, Macpherson M, Mutz M, Troedsson MH.** (2011) Equine CRISP3 modulates interaction between spermatozoa and Polymorphonuclear Neutrophils. *Biol. of Reprod.* 85:157-164.

- Drucker A, Gomez V, Anderson S.** (2001) The economic valuation of farm animal genetic resources: a survey of available methods. *Ecological Economics* 36:1-18.
- Eisenbach M.** (2003) Why are sperm cells phagocytosed by leukocytes in the female genital tract? *Medical Hypotheses*. 60(4):590-592.
- El-Hajj Ghaoui R, Gillan L, Thomson P, Evans G, Maxwell C.** (2007) Effect of seminal plasma fractions from entire and vasectomized rams on the motility characteristics, status and In Vitro fertility of ram spermatozoa. *J. Androl.* 28:109-122.
- FAO** (2007). The state of the world's animal genetic resources for food and agriculture. Rome.
- FAO** (2012) Cryoconservation of animal genetic resources. Animal Production and Health Guidelines 12, Rome.
- Fiala S, Pimentel C, Steiger K, Mattos A, Gregory R, Mattos R.** (2002) Effect of skim milk and seminal plasma uterine infusions in mares. *Theriogenology* 58:491-494.
- Fiala S, Pimentel C, Mattos A, Gregory R, Mattos R.** (2007) Effect of sperm numbers and concentration on sperm transport and uterine inflammatory response in the mare. *Theriogenology* 67(3):556-562.
- Flores E, Taberner E, Rivera M, Peña A, Rigau T, Miró J.** (2008) Effects of freezing/thawing on motile sperm subpopulations of boar and donkey ejaculates. *Theriogenology* 70(6):936-945.
- Folch P.** (1998) Programa de conservació i manteniment de recursos genètics en la raça asinina catalana. Tesis doctoral. Universidad Autónoma de Barcelona. España.
- Gorgens A, Leibold W, Klug E, Schuberth HJ, Martinsson G, Zerbe H.** (2005) Inseminate components are modulating the chemotactic activity of uterine polymorphonuclear granulocytes (PMN) of mares. *Anim. Reprod. Sci.* 89:308-310.

- Hall S, Bradley D.** (1995) Conserving livestock biodiversity. *TREE* 10 (7):267-270.
- Heinemann J.** (2009) Donkey Therapy is a Big Ass-et in Germany. The Gathered View. National Newsletter of the Prader-Willi Syndrome Association (USA). Sep-Oct: 35 (5):1-16.
- Heise A, Kähn W, Volkmann DH, Thompson PN, Gerber D.** (2010) Influence of seminal plasma on fertility of fresh and frozen-thawed stallion epididymal spermatozoa. *Anim. Reprod. Sci.* 118(1):48-53.
- Hurtgen J.** (2006) Pathogenesis and treatment of endometritis in the mare: A review. *Theriogenology* 66:560-566.
- Hunter B, Raz T, Grey A, Chirino-Trejo M, Card C.** (2006) Uterine inflammatory response to simultaneous treatment with frozen semen and bacteria in resistant mares. . In: Proceedings of the 52th convention of the AAEP, San Antonio, Texas, USA. *Reproduction* 52:389-392.
- Jaffe K, Camejo M, Carrillo T, Weffer M, Muñoz M.** (2006) Evidence favoring sperm selection over sperm competition in the interaction between human seminal plasma and sperm motility in vitro. *Arch. Androl.* 52(1):45-50.
- Jasko DJ, Little TV, Lein DH, Foote RH.** (1992) Comparison of spermatozoal movement and semen characteristics with fertility in stallions: 64 cases (1987-1988). *J. Am. Vet. Med. Assoc.* 200(7):979-985.
- Jepsen R, Evans L, Youngs C.** (2010) Use of direct thaw insemination to establish pregnancies with frozen-thawed semen from a standard Jack. *J Equine. Vet. Sci.* 30 (11):651-656.
- Jiwakanon J, Persson E, Berg M, Dalin A.** (2011) Influence of seminal plasma, spermatozoa and semen extender on cytokine expression in the porcine endometrium after insemination. *Anim. Reprod. Sci.* 123:210-220.
- Jordana J, Bosch E, Ferrando A.** (2010) Asé Català. Les Races Autòctones (II). Dossier Tècnic. RuralCat y Departament d'Agricultura, Alimentació y Acció Rural de la Generalitat de Catalunya 44:3-7.

- Jordana J, Folch P.** (1996) The endangered catalonian donkey breed: The main ancestor of the American ass or mammoth. *J. Equine. Vet. Sci.* 16(10):436-441.
- Kareskoski M, Katila T.** (2008) Components of stallion seminal plasma and the effects of seminal plasma on sperm longevity. *Anim. Reprod. Sci.* 107:249-256.
- Katila T.** (1996) Uterine defence mechanisms in the mare. *Anim. Reprod. Sci.* 42(1-4):197-204.
- Katila T.** (2001) Sperm–uterine interactions: a review. *Anim. Reprod. Sci.* 68(3-4):267-272.
- Katila T.** (2005) Effect of the inseminate and the site of insemination on the uterus and pregnancy rates of mares. *Anim. Reprod. Sci.* 89(1-4):31-38.
- Katila T.** (2012) Post-mating inflammatory responses of the uterus. *Reprod. Dom. Anim.* 47(s3):31-41.
- Kazim G, Reilas T, Katila T.** (2005) Effect of insemination and site on uterine inflammatory response of mares. *Theriogenology* 63:2504-2512.
- Kenney R, Doig P.** (1986) Equine endometrial biopsy. *Theriogenology* 2:723-729.
- Koblischke P, Kindahl H, Budik S, Aurich J, Palm F, Walter I, Kolodziejek J, Nowotny N, Hoppen HO, Aurich C.** (2008) Embryo transfer induces a subclinical endometritis in recipient mares which can be prevented by treatment with non-steroid anti-inflammatory drugs. *Theriogenology* 70(7):1147-1158.
- Kollias-Baker C, Cox K.** (2004) Non-steroidal anti-inflammatory drugs. *Equine Clinical Pharmacology* 14: 247-266
- Kotilainen T, Huhtinen M, Katila T.** (1994) Sperm-induced leukocytosis in the equine uterus. *Theriogenology* 41(3):629-636.
- Kugler W, Grunenfelder HP, Broxham E.** (2008) Donkey Breeds in Europe. SAVE foundation. Monitoring Institute for Rare Breeds and Seeds in Europe. *Switzerland* 45: 44-47.

- Landoni MF, Lees P.** (1995) Comparison of the anti-inflammatory actions of flumixin and ketoprofen in horses applying PK/PD modelling. *Equine. Vet. J.* 27:247–56.
- Landoni MF, Lees P.** (1996) Pharmacokinetics and pharmacodynamics of ketoprofen enantiomers in the horse. *J. Vet. Pharmacol. Ther.* 19(6):466-474.
- Lauvie A, Audiot A, Couix N, Casabianca F, Brives H, Verrier E.** (2011) Diversity of rare breed management programs: Between conservation and development. *Livestock Sci.* 140:161-170.
- LeBlanc MM.** (2010) Advances in the Diagnosis and Treatment of Chronic Infectious and Post-Mating-Induced Endometritis in the Mare. *Reprod. Dom. Anim.* 45 (Supp. 2): 21–27
- Li J, Yamaguchi S, Funahashi H.** (2012) Boar seminal plasma or hen's egg yolk decrease the in-vitro chemotactic and phagocytotic activities of neutrophils when co-incubated with boar or bull sperm. *Theriogenology* 77:73-80.
- Liu I, Scott M.** (2000) Sperm in the oviduct. *J. Equine Vet. Sci.* 20(12):836.
- Maischberger E, Irwin J, Carrington S, Duggan V.** (2008) Equine post-breeding endometritis. *J. Equine. Vet.* 61(3):163-168.
- Maloufi F, Pierson R, Otto S, Ball C, Card C.** (2002) Mares susceptible or resistant to endometritis have similar endometrial echographic and inflammatory cell reactions at 96 hours after infusion with frozen semen and extender. In: *Proceedings of the 48th convention of the AAEP.* Orlando, Florida, USA. 48:51-57
- Martin F, Morceau Y.** (2006) Le Baudet du Poitou: 25 ans de recherche pour sa conservation. *Les actes du BRG* 6:393-400
- Matthijs A, Engel B, Woelders H.** (2003) Neutrophil recruitment and phagocytosis of boar spermatozoa after artificial insemination of sows, and the effects of inseminate volume, sperm dose and specific additives in the extender. *Reproduction* 125(3):357-367.

- Miró J, Taberner E, Rivera M, Peña A, Medrano A, Rigau T.** (2009) Effects of dilution and centrifugation on the survival of spermatozoa and the structure of motile sperm cell subpopulations in refrigerated Catalanian donkey semen. *Theriogenology* 72(8):1017-1022.
- Moses V, Bertone A.** (2002) Nonsteroidal anti-inflammatory drugs. *Vet. Clin. Equine* 18: 21-37
- Mozaffari A, Derakhshanfar A, Alinejad A, Morovati M.** (2010) A comparative study on the adverse effects of flunixin, ketoprofen and phenylbutazone in miniature donkeys: Haematological, biochemical and pathological findings. *NZ. Vet. J.* 58(5):224-228.
- Nielsen J.** (2005) Endometritis in the mare: A diagnostic study comparing cultures from swab and biopsy. *Theriogenology* 64:510-518.
- Odhiambo J, Poole D, Hugues L, DeJarnette J, Inskeep E, Dailey R.** (2009) Pregnancy outcome in dairy and beef cattle after insemination and treatment with seminal plasma or growth factor beta-1. *Theriogenology* 72:566-571.
- Olds-Clarke P.** (1996) How does poor motility alter sperm fertilizing ability? *J. Androl.* 17(3):183-186.
- O'Leary S, Jasper M, Warnes G, Armstrong D, Robertson S.** (2004) Seminal plasma regulates endometrial cytokine expression, leukocyte recruitment and embryo development in the pig. *Reproduction* 128:237– 47.
- Oliveira J.** (2005) Estudo de metodologias para a criopreservação de sêmen de jumento (*Equus asinus*) por meio de testes laboratoriais e fertilidade. Tesis doctoral. Faculdade de Medicina Veterinária e Zootecnia da Universidade Estadual Paulista. Botucatu – Brasil.
- Oliveira J, Alvarenga M, Melo C, Macedo, Dell'Aqua Jr, Papa F.** (2006) Effect of cryoprotectant on donkey freezability and fertility. *Anim. Reprod. Sci.* 94:82-84
- Oliveira J, Ozanam F, Monteiro J, Marini C, Alvarenga M.** (2011) Nascimento do primeiro jumento a partir de espermatozóides congelados no Brasil. In:

Proceedings of the XII ABRAVEQ anual conference, Campinas, São Paulo, Brasil. The Brazilian Association of Equine Practitioners, p. 203.

Oliveira J, Papa F, Melo C, Monteiro G, Puoli-Filho J, Alvarenga M. (2012) New procedures to freeze donkey semen and its influence on mares and jennies fertility. *J. Equine Vet. Sci.* 32: 503-504

Overbeck W, Witte T, Heuwieser W. (2011) Comparison of three diagnostic methods to identify subclinical endometritis in mares. *Theriogenology* 75(7):1311-1318.

Palm F, Walter I, Budik S, Aurich C. (2006) Influence of different semen extenders and seminal plasma on the inflammatory response of the endometrium in oestrous mares. *Anim. Reprod. Sci.* 94:286-289.

Palm F, Walter I, Budik S, Kolodziejek J, Nowotny N, Aurich C. (2008) Influence of different semen extenders and seminal plasma on PMN migration and on expression of IL-1 β , IL-6, TNF- α and COX-2 mRNA in the equine endometrium. *Theriogenology* 70(5):843-851.

Parés PM, Vilaró T. (1994) La ramaderia. Quaderns de la Revista de Girona. Num. 52, Diputació de Girona/Caixa de Girona, Catalunya.

Portus B, Reilas T, Katila T. (2005) Effect of seminal plasma on uterine inflammation, contractility and pregnancy rates in mares. *Equine. Vet. J.* 37: 515-519.

Pukazhenti BS, Wildt DE. (2004) Which reproductive technologies are most relevant to studying, managing and conserving wildlife? *Reprod. Fertil. Dev.* 16: 33-46.

Renner-Martin T, Forstenpointner G, Weissengruber G, Eberhardt L. (2009) Gross anatomy of the female genital organs of the domestic donkey (*equus asinus* linne, 1758). *Anat. Histol. Embryol.* 38(2):133-138.

- Risco A, Reilas T, Muilu L, Kareskoski M, Katila T.** (2009) Effect of oxytocin and flunixin meglumine on uterine response to insemination in mares. *Theriogenology* 72(9):1195-1201.
- Robertson S.** (2005) Seminal plasma and male factor signaling in the female reproductive tract. *Cell Tissue Res.* 322: 43-52.
- Rodero E, Valera M, Herrera M, Gómez M, Galisteo J.** (1998) Situación actual de la población asnal autóctona española. *Arch Zootec* 47:523-528.
- Rojer H, Aurich C.** (2010) Treatment of persistent mating-induced endometritis in mares with the non-steroid anti-inflammatory drug vedaprofen. *Reprod. Dom. Anim.* 45:458-60.
- Romagosa J.** (1959). El Garañon Catalán. Tesis doctoral. Universidad de Madrid. Madrid.
- Rota A, Magelli C, Panzani D, Camillo F.** (2008) Effect of extender, centrifugation and removal of seminal plasma on cooled-preserved Amiatina donkey spermatozoa. *Theriogenology* 69:176-185.
- Rota A, Panzani D, Sabatini C, Camilo F.** (2012) Donkey jack (*Equus asinus*) semen cryopreservation: Studies of seminal parameters, post-breeding inflammatory response, and fertility in donkey jennies. *Theriogenology* 78:1846-1854.
- Rozeboom KJ, Rocha-Chavez G, Troedsson MH.** (2001) Inhibition of neutrophil chemotaxis by pig seminal plasma in vitro: a potential method for modulating post-breeding inflammation in sows. *Reprod.* 121(4):567-572.
- Sharkey D, Tremellen K, Jasper M, Gemzell-Danielsson K, Robertson S.** (2012) Seminal fluid induces leukocyte recruitment and cytokine and chemokine mRNA expression in the human cervix after coitus. *J. Immunol.* 188: 2445-2454.
- Schlafer DH.** (2007) Equine endometrial biopsy: Enhancement of clinical value by more extensive histopathology and application of new diagnostic techniques? *Theriogenology* 68(3):413-422.

- Schuberth HJ, Taylor U, Zerbe H, Waberski D, Hunter R, Rath D.** (2008) Immunological responses to semen in the female genital tract. *Theriogenology* 70(8):1174.
- Scott J, Ketheesan N, Summers P.** (2009) Spermatozoa and seminal plasma induce a greater inflammatory response in the ovine uterus at oestrus than dioestrus. *Reprod. Fertil. Dev.* 21: 817–826.
- Serres, C.** (2003) Evaluación y conservación del semen del Asno Zamorano-Leonés. Tesis Doctoral. Universidad Complutense de Madrid. Madrid.
- Slusher SH, Freeman KP, Roszel JF.** (1984) Eosinophils in equine uterine cytology and histology specimens. *J. Am. Vet. Med. Assoc.* 184(6):665-670.
- Snider TA, Sepoy C, Holyoak GR.** (2011) Equine endometrial biopsy reviewed: Observation, interpretation, and application of histopathologic data. *Theriogenology* 75(9):1567-1581.
- Sokkar SM, Hamouda MA, El-Rahman SM.** (2001) Endometritis in She Donkeys in Egypt. *J. Vet. Med.* 48(7):529-536.
- Stout T, Ruitjter-Villani M.** (2012) Effect of post-breeding dexamethasone treatment on the uterine inflammatory reaction in the mare. *Reprod. Dom. Anim.* 47: 60.
- Summerfield N, Watson E** (1998) Endometrial macrophage populations in genitally normal mares at oestrus and dioestrus and in mares susceptible to endometritis. *Equine. Vet. J.* 30 (1): 79-81
- Taberner E, Medrano A, Peña A, Rigau T, Miró J.** (2008) Oestrus cycle characteristics and prediction of ovulation in Catalanian jennies. *Theriogenology* 70: 1489-1497.
- Taberner E, Morató R, Mogas T, Miró J.** (2010) Ability of Catalanian donkey sperm to penetrate zona pellucida-free bovine oocytes matured in vitro. *Anim. Reprod. Sci.* 118: 354-361.

- Taylor U, Schuberth H, Rath D, Michelmann H, Sauter-Louis C, Zerbe H.** (2009a) Influence of inseminate components on porcine leucocyte migration *In Vitro* and *In Vivo* after Pre- and Post-Ovulatory insemination. *Reprod. Dom. Anim.* 44:180-188.
- Taylor U, Zerbe H, Seyfert H, Rath D, Baulain U, Langner K.** (2009b) Porcine spermatozoa inhibit post-breeding cytokine induction in uterine epithelial cells in vivo. *Anim. Reprod. Sci.* 115:279–89.
- Töpfer-Petersen E, Ekhlasi-Hundrieser M, Kirchhoff C, Leeb T, Sieme H.** (2005) The role of stallion seminal proteins in fertilization. *Anim. Reprod. Sci.* 89:159-170.
- Torres E, Querol J, Bosch E.** (1983). La raza asnal catalana: estado actual. 34 Reunion Anual de la Federación Europea de Zootecnia, Madrid.
- Trimeche A, Renard P, Tainturier D.** (1998) A procedure for poitou jackass sperm cryopreservation. *Theriogenology* 50(5): 793-806.
- Troedsson MH, Alghamdi A, Laschkewitsch T, Xue JL** (1998a) Sperm Motility Is Altered in Uterine Secretions from Mares with Postbreeding Endometritis. In: the AAEP proceedings 44: 66-67
- Troedsson MH, Liu IK, Crabo BG.** (1998b) Sperm transport and survival in the mare. *Theriogenology* 49:905-915.
- Troedsson MH, Loset K, Alghamdi A, Dahms B, Crabo B.** (2001) Interaction between equine semen and the endometrium: the inflammatory response to semen. *Anim. Reprod. Sci.* 68: 273-278.
- Troedsson MH, Desvouses A, Alghamdi A, Dahms B, Dow C, Hayna J, Valesco R, Collahan P, Macpherson L, Pozor M, Buhi W.** (2005) Components in seminal plasma regulating sperm transport and elimination. *Anim. Reprod. Sci.* 89:171-186.
- Troedsson MH, Desvouses A, Hansen P, Buhi W.** (2006) Equine seminal plasma proteins protect live spermatozoa from PMN-binding and phagocytosis, while

providing a mechanism for selective sperm elimination of apoptotic and dead spermatozoa. *Anim. Reprod. Sci.* 94: 60–61

Vendramini O, Guintard C, Moreau J, Tainturier D. (1998) Cervix conformation: A first anatomical approach in baudet du poitou jenny asses. *Anim. Sci.* 66:741-744.

Vidament M, Vincent P, Martin F, Magistrini M, Blesbois E. (2009) Differences in ability of jennies and mares to conceive with cooled and frozen semen containing glycerol or not. *Anim. Reprod. Sci.* 112:22-35.

Villanueva M, Heckenberger R, Strobach H, Palmér M, Schrör K. (1993) Equipotent inhibition by R(-), S(+) and racemic ibuprofen of human polymorphonuclear cell function *in vitro*. *Br. J. clin. Pharmacol.* 35:235-242.

Watson E, Barbacini S, Berrocal B, Sheerin O, Marchi V, Zavaglia G. (2001) Effect of insemination time of frozen semen on incidence of uterine fluid in mares. *Theriogenology* 56(1):123-131.

Watson ED. (2000) Post-breeding endometritis in the mare. *Anim. Reprod. Sci.* 60-61:221-232.

Woodward E, Christoffersen M, Campos J, Squires E, Troedsson MH. (2012) Susceptibility to persistent breeding-induced endometritis in the mare: Relationship to endometrial biopsy score and age, and variations between seasons. *Theriogenology* 78(3):495-501.

Yamaguchi S, Funahashi H, Murakami T. (2009) Improved fertility in gilts and sows after artificial insemination of frozen-thawed boar semen by supplementation of semen extender with caffeine and CaCl₂. *J. Reprod. Dev.* 55:645–649.