Malassezia YEASTS AND CLINICAL APPROACH OF DISEASES CAUSED BY *M. pachydermatis* IN PETS

LLONCH, L. Supervised by CABAÑES, F.J.
Faculty of Veterinary (UAB), Jun. 2015

AIMS

Malassezia genus is a group of yeasts that may develop disease in humans and animals. The aim of this review is to know all *Malassezia* species and their identification methods, such as clinical approach of the main pathogenic species in pets, *M. pachydermatis*.

TAXONOMY

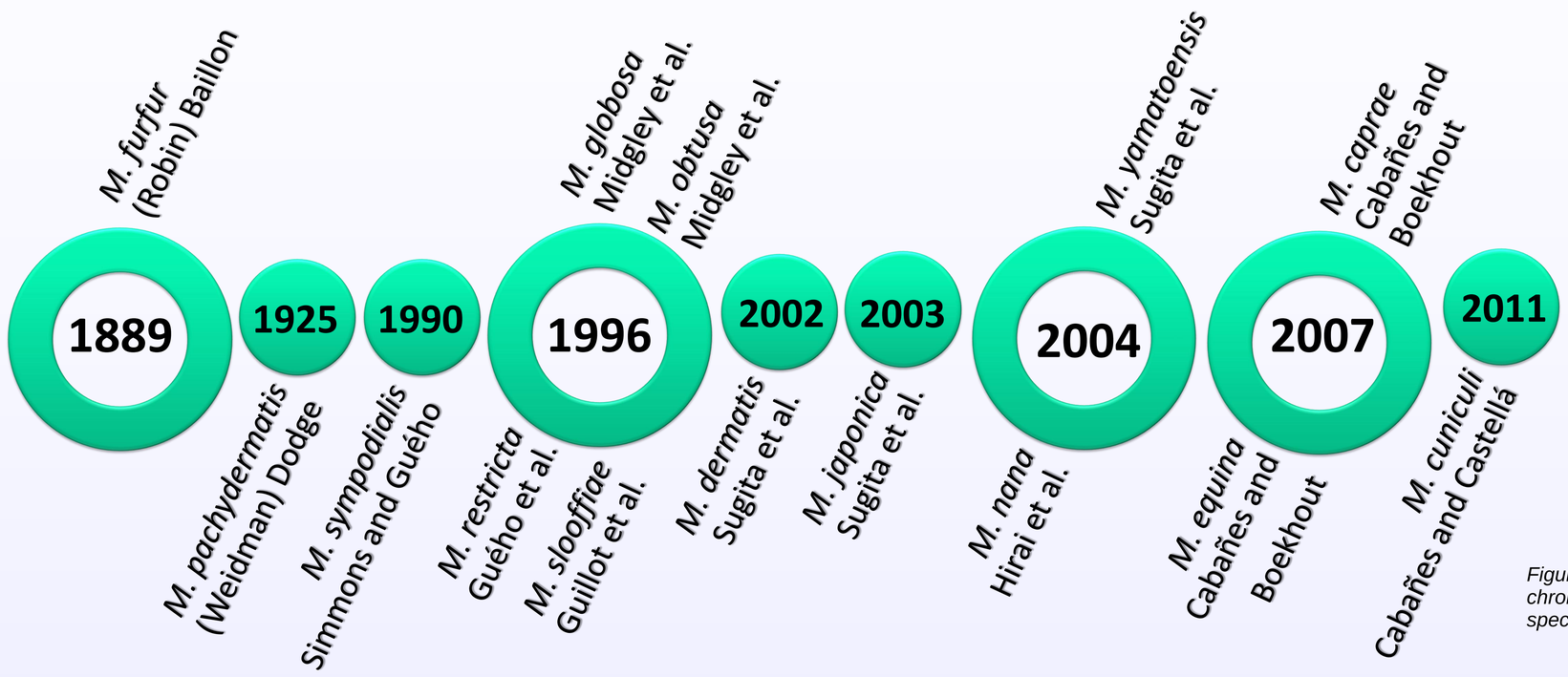

Figure 1. Taxonomic chronology of Malassezia species.

IDENTIFICATION

Species	Host	Phenotypic characteristics		
		Cell morphology	Lipid dependency	SDA (32˚C)
M. pachydermatis	Dog, cat/carnívores, birds	Ellipsoidal	-, (w)	+, w
M. furfur	Man/cow, elefant, pig, monkey, ostrich, pelican	Globose, ellipsoidal, cylindrical	+	-
M. sympodialis	Man/horse, pig, sheep	Ellipsoidal	+	-
M. globosa	Man/cheetah, cow	Globose	+	-
M. obtusa	Man	Ellipsoidal, cylindrical	+	-
M. restricta	Man	Globose, ellipsoidal	+	-
M. slooffiae	Man, pig/goat, sheep	Ellipsoidal, cylindrical	+	-
M. dermatis	Man	Ellipsoidal, globose	+	-
M. japonica	Man	Globose, ellipsoidal	+	-
M. nana	Cat, cow/dog	Ellipsoidal	+	-
M. yamatoensis	Man	Ellipsoidal	+	-
M. caprae	Goat/horse	Globose, ellipsoidal	+	-
M. equina	Horse/cow	Ellipsoidal	+	-
M. cuniculi	Rabbit	Globose	+	-

Table 1. Main guests and phenotypic characteristics of Malassezia species. (Cabañes et al., 2011; Cafarchia et al., 2011; Cabañes, 2014)

Molecular tools		DNA regions
Direct DNA sequencing		ITS-1
		LSU
		chs-2
		ITS-2
		IGS-1
Conventional PCR tools employing selected genetic markers	PCR-RFLP	ITS-1, ITS-2 and LSU
	PCR-SSCP	ITS-1 and chs-2
Real-time PCR employing markers in rDNA		ITS-1 and ITS-2
Fingerprinting methods	RAPD	Total genòmic DNA
	AFLP	Total genòmic DNA
	DGGE	SSU
	PFGE	Chromosomal DNA

Table 2. Molecular techniques for identification and differentiation of Malassezia species. (Cafarchia et al., 2011)

DISEASES CAUSED BY *M. pachydermatis* IN PETS

Image 1. Hyperpigmentation, erythema and secondary liquenificació to Malassezia dermatitis in atopic German shepherd. (courtesy of Mar Bardagí, HCV -UAB)

Clinical profile

Image 2. Facial fold dermatitis and secondary dermatitis to Malassezia. (courtesy of Mar Bardagí, HCV -UAB)

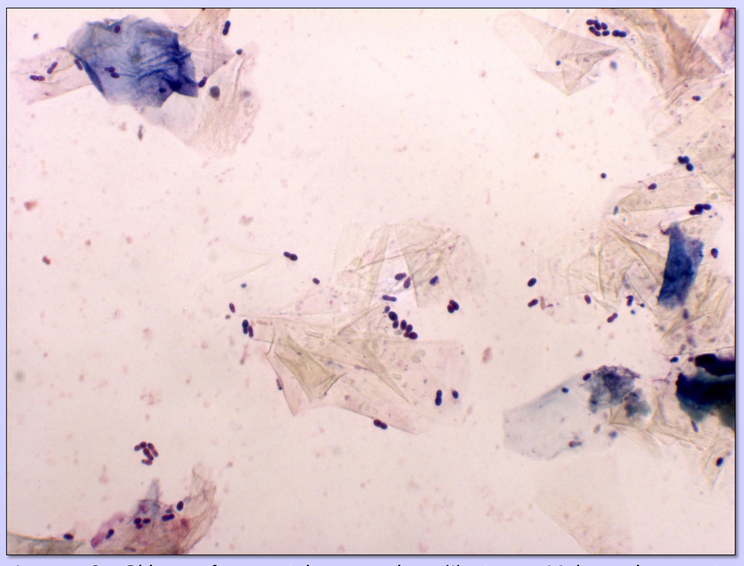

Image 3. Skin surface cytology made with tape. Malassezia yeasts observed. (courtesy of Mar Bardagí, HCV -UAB)

Clinical diagnosis

Therapeutic treatment

Topical therapy

- 2% miconazole and 2% clorhexidine
- 2-4% clorhexidine
- 2% miconazole
- 2% ketoconazole
- 1% ketoconazole and 2% clorhexidine
- 1% selenium sulfide (dogs only)

Systemic therapy

- Ketoconazole
- Itraconazole
- Fluconazole
- Terbinafine

Figure 2. Therapeutic drugs for Malassezia dermatitis treatment.

CONCLUSIONS

Regular presence of opportunistic and pathogenic species of *Malassezia* in our society requires a deep understanding of this yeast to be able to control them.

Right knowledge of clinical profile of *M. pachydermatis* in dogs and cats contrast with absence of specific diagnostic criteria, which delay definitive diagnosis and complicate clinical approach to inexperienced veterinary surgeon.