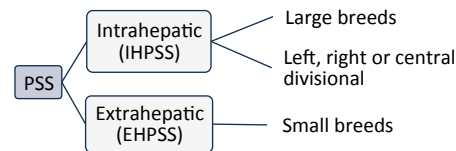


Judit Navarro Artero (June 2017)

INTRODUCTION

PORTOSYSTEMIC SHUNT (PSS)

PSS is a vascular communication between portal and systemic circulation (caudal vena cava or azygos vein). It can be congenital (most common) or acquired.



Clinical signs: neurological, gastrointestinal and urinary.

TREATMENT

Medical therapy is not curative. The objective of this therapy is to reduce blood ammonia levels in order to decrease clinical signs associated to hepatic encephalopathy.

Surgical treatment is the only curative option. Its objective is to produce total, progressive occlusion of the anomalous vessel. There are two types of surgical treatment:

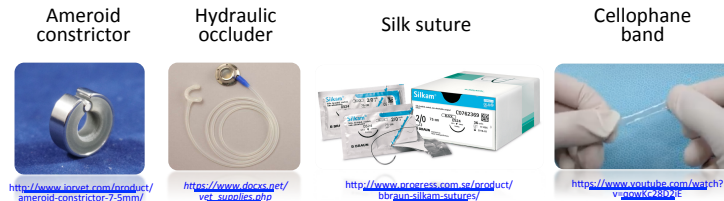- **Invasive techniques.**
- **Minimally-invasive techniques:** interventional radiology.

OBJECTIVES

1. To assess surgical invasive techniques for the treatment of IHPSS.
2. To determine the existing minimally-invasive techniques for the treatment of intrahepatic PSS and to establish the most used ones.
3. To compare invasive and minimally-invasive techniques.

TECHNIQUE COMPARISON

INVASIVE TECHNIQUES



INTERVENTIONAL RADIOLOGY

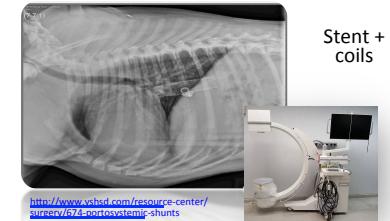


Table 1: Comparison of techniques for the treatment of intrahepatic portosystemic shunt in dogs.

Technique	Nº of surgeries	Medium survival time (months)	Major complications (*)			Mortality due to shunt or surgery (*)			Outcome (*)			Author
			Intra-OP	Post-OP (1w)	Post-OP (>1w)	Intra-OP	Post-OP (1w)	Post-OP (>1w)	E	M	D	
PTE (Stent + Coils)	111	73,5	3/111	14/111	-	1/111	4/111	14/111	57/86	13/86	16/86	Weisse et al. (2014)
	5	-	0	0	0	0	0	0	4/5	1/5	0	Bussadori et al. (2007)
	3	>9	0	0	0	0	0	0	0	3/3	0	Cook et al. (2015)
AC	11	-	0	1/11	3/11	0	1/11	3/11	2/10	5/10	3/10	Mehl et al. (2007)
	9	-	1/9	0	1/9	0	0	1/9	7/8	0	1/8	Bright et al. (2006)
CB	11	-	0	6/11	0	0	3/11	0	5/10	0	5/10	Hunt et al. (2004)
PL	17	-	0	2/17	0	0	1/17	0	12/13	1/13	0	Mehl et al. (2007)
HO	10	>22	0	0	0	0	0	0	6/8	2/8	0	Adin et al. (2006)

* Number of animals/Total number of animals. Abbreviations: PTE, Percutaneous Transvenous Embolization; AC, Ameroid Constrictor; CB, Cellophane Banding; PL, Partial Ligation; HO, Hydraulic Occluder; E, Excellent; G, Good; P, Poor; w, Week.

CONCLUSIONS

- According to the cases studied in this dissertation, the best invasive surgical technique for the treatment of the intrahepatic portosystemic shunt is a partial ligation. However, the bibliography includes a small amount of cases and the result is non-concluding. Apart from being the most effective technique, partial ligation is also the least expensive technique.
- Invasive surgical techniques are related to a poorer prognostic in intrahepatic portosystemic shunts, rather than extrahepatic, partially due to the difficulty of the surgical approach.
- The only endovascular minimally-invasive technique described for the treatment of the intrahepatic portosystemic shunt in dogs is the percutaneous transvenous embolization using a stent and thrombogenic coils.
- Minimally invasive surgical techniques (interventional radiology) for the treatment of intrahepatic portosystemic shunt imply similar outcomes but lower mortality and poor outcome rates compared with invasive techniques.
- Veterinary publications about interventional radiology for the treatment of intrahepatic portosystemic shunt are limited due to the high cost of the surgical technique and the high specialization of the surgery. It's an emerging technique that can become the future for the treatment of intrahepatic portosystemic shunt in dogs.