

## 1 Introduction

Among feline neoplasms, **squamous cell carcinoma (SCC)** is one of the most common tumors, mainly affecting depigmented areas and white-coated cats. Treatments include surgery, chemotherapy, and radiation therapy, cryotherapy, phototherapy and **electrochemotherapy (ECT)**. ECT emerges as an innovative option, combining the administration of antineoplastic drugs with electric pulses to improve the effectiveness of the treatment and minimize side effects.

## 3 Materials and methods

In addition to the bibliographic search, a **retrospective study of 15 clinical cases of cats with SCC of the nasal planum** treated exclusively with ECT at the Hospital Clínic Veterinari of UAB was carried out. Diagnosis was made by **biopsy**. Most of the analyzed cases were patients with SCC staging in **T1, No** (absence of metastasis in the regional lymph node) and **Mo** (absence of distant metastasis) unless two cats with **T2** staging.

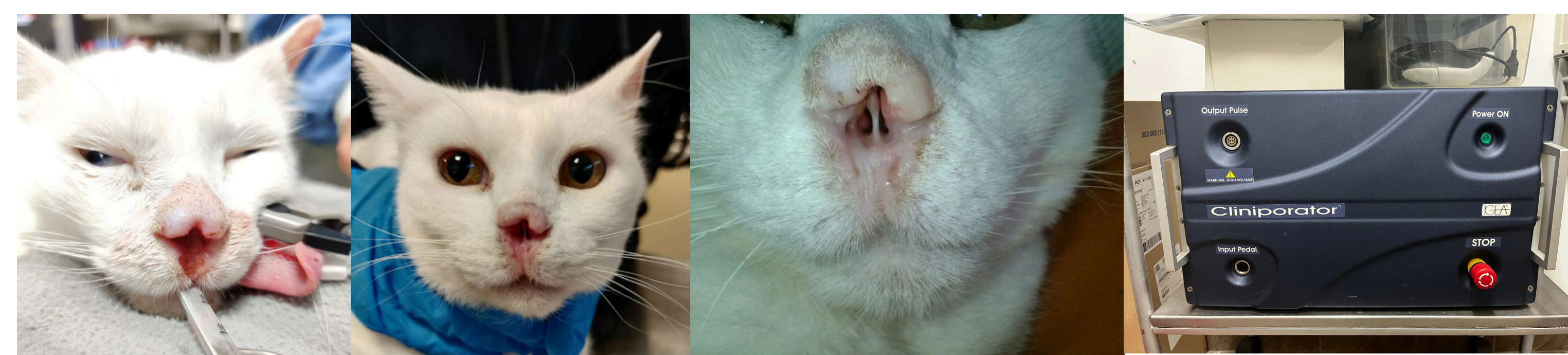
Cats were treated with the **standard dose of bleomycin (15000 IU/m<sup>2</sup>) intravenously** (voltage 1300 V, 100 microseconds, duration 2 milliseconds, 8 pulses per application) under general anesthesia. The equipment used was IGEA brand Cliniporator with parallel electrodes. After ECT application, **supportive therapy** with anti-inflammatory drugs (4-5 days) and broad-spectrum antibiotics if secondary bacterial infection was suspected.

## 2 Objectives

- Review the mechanism of action and application of ECT for SCC of the nasal planum in cats.
- Retrospective analysis of clinical cases treated at the Hospital Clínic Veterinari of UAB of cats with squamous cell carcinoma of the nasal planum treated with ECT.

## 4 Results and discussion

All cats were **Common European breed** (100%). Most of them had white or partially white coat whit **depigmented area of the nasal planum**. Among the treated cats, 5 (33.3%) were neutered males, 2 non-neutered males (13.3%), 5 neutered females (33.3%) and 3 non-neutered females (20%).



**Figure 1.** A) Cat with SCC of the infiltrative nasal planum B) 21 days after 1st ECT C) 1 month after 2nd ECT, favorable evolution where no ulceration is observed D) Equipment used to perform the ECT (Cliniporator of the IGEA brand) (Images provided by HCV).

Age at first Tx (years)	Lesion / year of lesion	Shelter (S) or Guardian (G)	Number of Tx	Time between Tx	Local response 6 months after first Tx	Disease-free interval	Observations (follow-up 1 year after first Tx)	Age at first Tx (years)	Lesion / year of lesion	Shelter (S) or Guardian (G)	Number of Tx	Time between Tx	Local response 6 months after first Tx	Disease-free interval	Observations (follow-up 1 year after first Tx)
7	Ulcerative superficial lesion (0,4 x 0,5 cm) / 30/03/2021	S	2	1 year	CR	12 months	Recurrence 1 year post first Tx	10	SCC partial invasive / 01/10/2020	G	3	2,5 months / 2 months	PR	12 months	Still in PR, but with good evolution, 3 session is made
11	Ulcerative lesion (0,7 x 0,7 x 0,2 cm) / 27/04/2022	S	1		CR	8 months	Death 1 year post first Tx. Cause no related with SCC.	13	Erosive and crust lesions / 28/04/2023	S	1		CR	8 months	Loss of follow-up
11	Infiltrative SCC / 01/12/2023	G	2	2,5 months	PR		Loss of follow-up	12	Nodular lesion (1 x 1 x 0,8 cm) / 15/06/2022	S	3	2,5 months / 7 months	PR		Still in RP
10	SCC in advanced stage (1 x 1,4 cm) / 22/04/2021	S	2	1 month	CR		Death 8 months post first Tx. Cause no related with SCC.	12	Ulcerative lesion (2,3 x 2 cm) / 08/07/2021	S	2	5 months	PR		Loss of follow-up
8	Ulcerative lesions (0,2 x 0,1 cm) / 08/06/2021	S	1		CR		Loss of follow-up	3	Ulcerative lesion (1,2 x 1,2 x 0,7 cm) / 15/12/2021	S	4	21 days / 7 months / 3 months	PR		Still in RP
12	Ulcerative and crust lesion / 01/10/2020	G	2	2 months	CR	10 months	Recurrence 10 months post second Tx	6	Lesion of 1 x 1 cm / 18/02/2021	G	2	4 months	PR	10 months	Loss of follow-up
10	Ulcerative lesion (0,7 x 0,7 x 0,2 cm) / 27/01/2019	G	3	2 years / 1,5 years	CR	24 months	Still in CR	10	Infiltrative lesions and destruction of nose / 04/02/2021	G	2	1,3 months	PR	24 months	Loss of follow-up
10	Erosive and crust lesion (0,3 x 0,3 cm) / 25/01/2022	G	2	11 months	CR	11 months	Recurrence 11 months post first Tx								

**Table 1.** 15 cats with SCC treated with ECT. ECT = electrochemotherapy; SCC = squamous cell carcinoma; Tx = treatment; CR = complete response; PR = partial response

## 5 Conclusions

- ECT is increasingly popular and can be a useful tool in the treatment of SCC in cats due to its easy administration, effectiveness, few side effects, and the possibility of combining it with other treatments such as surgery.
- The choice of treatment should be based on the health status of each patient, the size and extent of the lesions and the expectations of the owner.
- The results highlight the importance of long-term follow-up due to the high percentage of relapse observed in the study.

## 6 References

