

ELBOW ARTHRODESIS IN DOG: EXPLORING THE CHALLENGES OF ONE OF THE MOST COMPLICATED INTERVENTIONS IN VETERINARY TRAUMATOLOGY

David Iznájar Blázquez
Final degree project - June 2024

INTRODUCTION

The elbow in dogs is a vital and commonly affected joint, causing non-traumatic lameness in the anterior limbs. Between 5% and 10% of dogs will need elbow surgery during their lifetime. Elbow arthrodesis is a rare procedure with a low success rate of 13.6% which is often required in these cases.

OBJECTIVES

To answer the question of why elbow arthrodesis is so complicated and why it has such a low success rate.

ANATOMY OF ELBOW

The elbow is a condyle and monoaxial synovial joint formed by the condyles of the humerus, radius and ulna. Its main movements are flexion and extension, with a variable angle depending on the breed of the dog.

This joint is anatomically complex due to the presence of several structures, such as bones, nerves, ligaments, arteries, veins, and muscles.

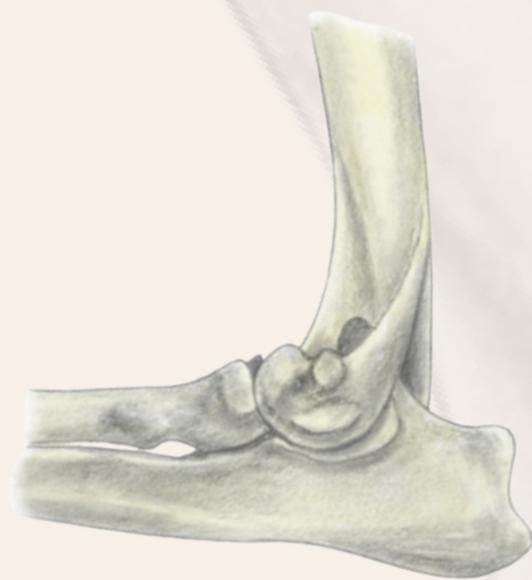

Figure 1. Lateral osteology of the elbow. Source: (Constantinescu G y Constantinescu I, 2009).

ARTHRODESIS

It is a last resort procedure to prevent amputation, where the joint is fixed at a specific angle by removing cartilage and using an osteosynthesis plate. The different types of approaches are caudal, medial and lateral.

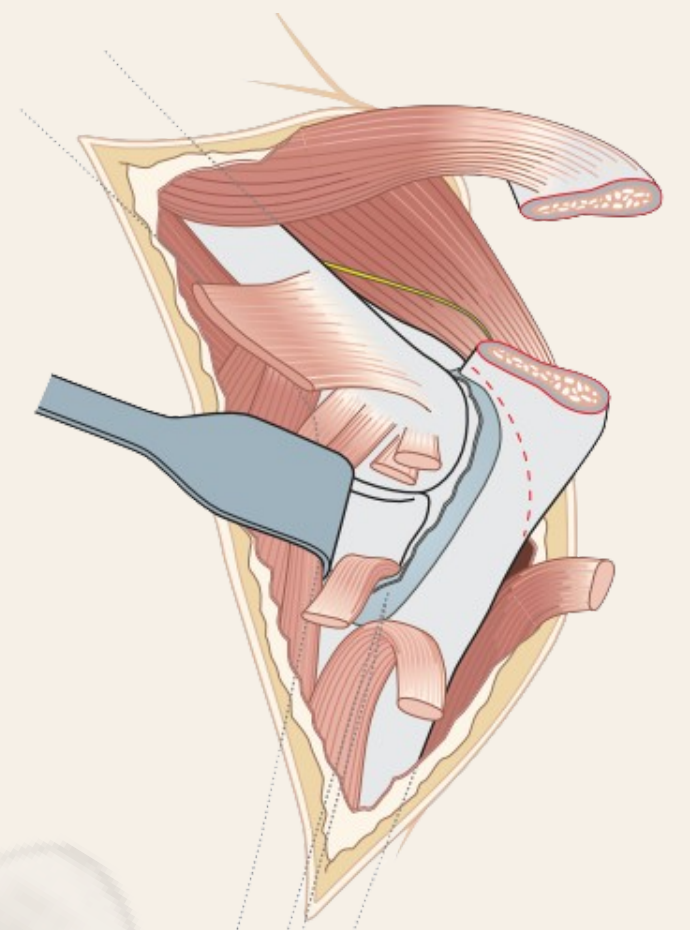


Figure 2. Caudal approach. Source: (Johnson et al., 2005).

COMPLICATIONS

The main factors that cause complications are anatomical and biomechanical complexity, force load on the joint, immobilization time, internal fixation, postoperative bandages, surgical and anesthetic time, invasive technique, use of non-blocking plates and non-compliance with asepsis.

ALTERNATIVES

The alternative to arthrodesis is the elbow prosthesis, which can be total or partial. The main types are the Iowa State System and the TATE Elbow System for total prostheses, and the BANC System for partial prostheses.

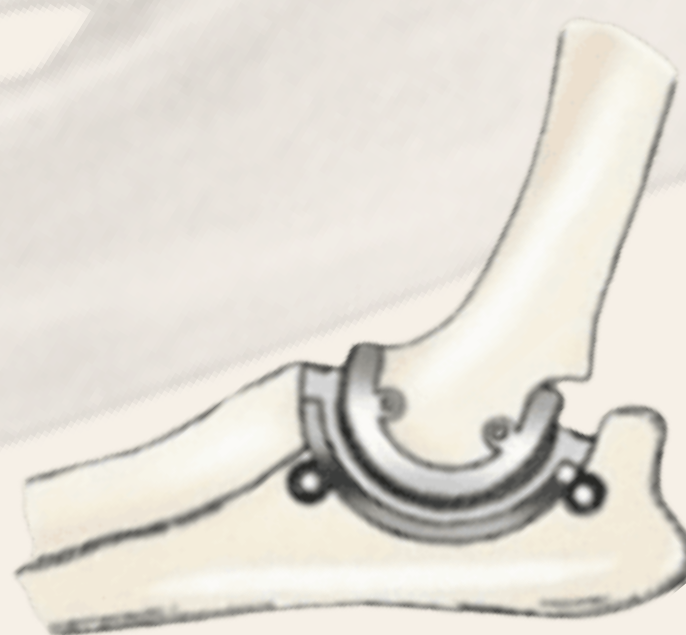


Figure 3. TATE Elbow system. Source: (Johnston S.A. y Tobias K.M., 2023).

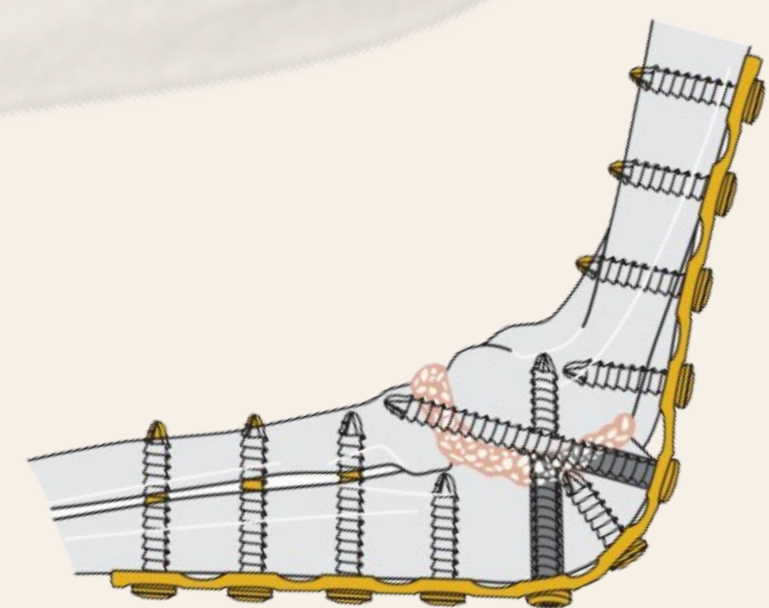


Figure 4. Placement of caudal plate. Source: (Johnson et al., 2005).

CONCLUSIONS

We can conclude that elbow arthrodesis is a surgery of high surgical complexity, where multiple factors converge to hinder the best outcome. Considering the importance of the joint, its anatomical complexity and the complications that arise during or after surgery, elbow arthrodesis is a highly complex traumatological intervention with low success rates (13.6%).